

# Endodontic Management of Type 2 Dens Invaginatus Using Endosequence Bioceramic Root Repair Material

Sarang Suresh, Muhammad Muzamil Alvi, Feroze Ali Kalhor, Priya Rani Harjani and Mahwish Memon

*Department of Operative Dentistry and Endodontics, Liaquat University of Medical and Health Sciences, Jamshoro, Pakistan*

## ABSTRACT

This study reports a case of a 16-year male patient with a palatal swelling and a non-vital maxillary left lateral incisor. The patient was diagnosed with pulp necrosis and radicular cyst of UL2 with a lesion size of more than 15 mm, an open apex, and a type 2 dens invaginatus using Cone Beam Computerized Tomography (CBCT). This case report further describes the successful treatment of the patient with orthograde root canal treatment followed by periapical surgery with a labial approach and bioceramic root repair material, which resulted in complete healing of the periapical lesion within four months.

**Key Words:** Bioceramics, Cone-beam computed tomography, Dens invaginatus.

**How to cite this article:** Suresh S, Alvi MM, Kalhor FA, Harjani PR, Memon M. Endodontic Management of Type 2 Dens Invaginatus Using Endosequence Bioceramic Root Repair Material. *JCPSP Case Rep* 2023; 1:89-91.

## INTRODUCTION

Dens invaginatus (DI) is a developmental anomaly that affects different teeth and has different classifications based on various factors. Type I (Oheler's classification) is the most common and only involves the crown, while Type II is deeper and can extend to the root canal system, and Type III is the least common and extends through the root to the apex.<sup>1</sup> The aetiology of DI is not well understood.<sup>2</sup> The treatment options depend on the severity of the lesion and the extent of pulpal involvement, and early management is essential to prevent further complications. Therefore, knowledge and understanding of the diagnosis and management of DI are significant to clinical practice.

This case report describes a 16-year male patient who underwent surgical endodontic treatment for a palatal swelling associated with the non-vital maxillary left lateral incisor. The publication of this case report can enhance the knowledge and understanding of clinicians and researchers in the field of endodontics and can improve patient care and outcomes in DI.

## CASE REPORT

A 16-year male was referred for the diagnosis and management of a non-vital maxillary left lateral incisor with palatal swelling which was present for a week and was slowly growing. There was no history of trauma, fever, pain, or discharge from the swelling.

However, both the patient and their family were concerned about the possibility of oral cancer. Adding to their worries, a quack had recommended him to stop brushing his teeth to prevent the swelling from growing further.

The patient reported brushing his teeth once a day. He was not on any medications and had no known systemic disease.

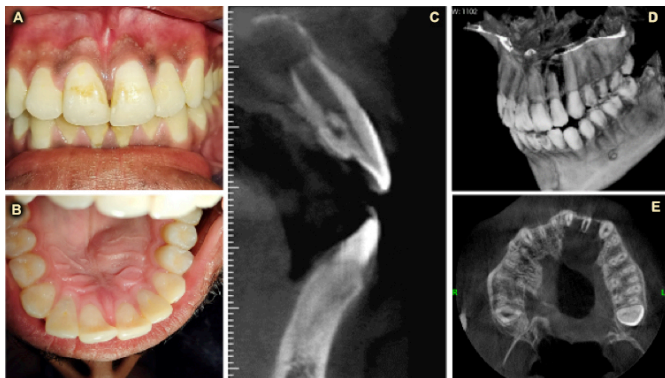
During the extraoral clinical examination, he had a normal gait and was accompanied by his mother. No swelling or discolouration was found on the patient's face. The temporomandibular joint examination was normal, and there was no regional lymphadenopathy. During the intraoral examination, there was no sign of dental trauma, and the gingival colour was normal with no labial gingival swelling. However, the patient had a unilateral left anterior palatal swelling with pink-coloured overlying mucosa, extending from the UL5 to the distal aspect of the UL3. There were no caries lesions on any anterior teeth, but generalised cervical plaque was visible on the labial surface of the anterior maxillary and mandibular teeth. The swelling was hard, firm, and attached to the bone. Aspiration of the swelling resulted in straw-coloured fluid, and no decrease in swelling was observed. The swelling was non-tender to palpation, and tenderness on percussion was negative from the UL6 to the UR6.

Pulp sensibility tests were performed from UR2 to UL6. The tests included a cold test using Endo Cold Spray (Henry Schein, USA) and an electric pulp test using Waldent Electric Pulp Tester. Normal responses were observed for all teeth except for the UL2 which showed a negative response to both the cold and electric pulp testing.

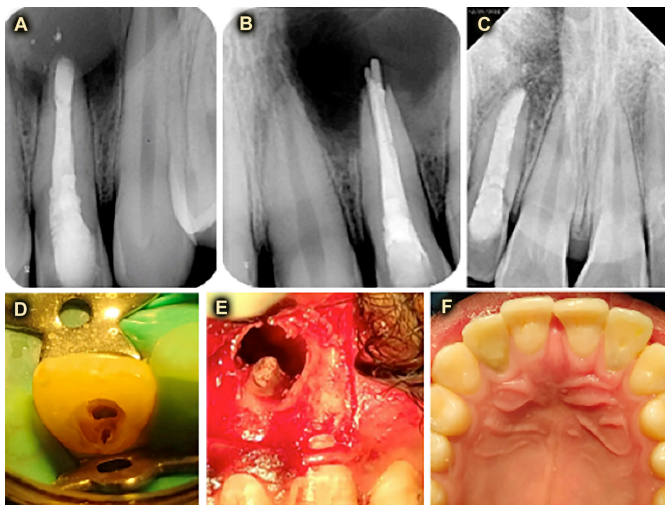
The patient had an orthopantomogram (OPG), which revealed a well-circumscribed radiolucency with corticated margins in the left maxillary region encircling the UL1 to UL3 below the maxillary sinus. Additionally, an open apex was visible with UL2, with a shorter root length than the UR2.

*Correspondence to: Dr. Sarang Suresh, Department of Operative Dentistry and Endodontics, Liaquat University of Medical and Health Sciences, Jamshoro, Pakistan*  
E-mail: hotchandanisarang@gmail.com

Received: June 16, 2023; Revised: July 24, 2023;  
Accepted: July 27, 2023  
DOI: <https://doi.org/10.29271/jcpspcr.2023.89>



**Figure 1:** (A) Clinical photograph of frontal view in occlusion; (B) Clinical photograph of maxillary occlusal view; (C) Sagittal view of CBCT showing dens invagination; (D) 3D view of CBCT, showing small left maxillary lateral incisor along with radiolucency at apex; (E) Axial view showing dimension of open apex and apical resorption.



**Figure 2:** (A) Postoperative periapical radiograph after 10 days showing access cavity restored with composite and root end restoration; (B) Postoperative periapical radiograph after immediately after obturation showing extruded gutta percha; (C) Periapical radiograph obtained on follow-up after 4 months showing complete bone repair with normal lamina dura around apex; (D) Intra oral clinical photograph showing main canal and invaginated canal in left maxillary lateral incisor; (E) Intra operative clinical photograph showing root end restoration with Endosequence Bioceramic Root Repair Material; (F) Postoperative maxillary occlusal showing complete healing at 4 months.

A Cone Beam Computerized Tomography (CBCT) (Villa SI stemi Medicali S.p.A, Italy) was performed, which revealed that the UL2 had parallel roots and an open apex which could be associated with Type II DI. The length of the left maxillary lateral incisor was measured to be 24 mm in incisal to apical direction, while the dimension of the open apex was 1.88 mm in mesiodistal direction and 4 mm in faciopalatal direction. The size of the apical radiolucency was measured to be 18×18 mm (Figure 1).

The working diagnosis of pulp necrosis with large endodontic lesion associated with left maxillary lateral incisor with open apex with Type II DI was made with the prognosis classified as uncertain based on size greater than 15 mm.

After the diagnosis was explained to the patient, various treatment options were informed, including non-surgical endodontic treatment with long-term intra-canal medications, extraction

followed by curettage and replacement with an implant or fixed partial denture, or no treatment. The pros and cons of each treatment were discussed in detail. The patient decided to undergo single-visit conventional orthograde root canal treatment with root-end surgery, with bioceramic root repair material. A written informed consent was obtained from the patient for this chosen treatment.

During the initial visit, a single session, orthograde, non-surgical root canal treatment was performed on two separate canals using ISO Hand Files in a Crown Down manner, while 3% sodium hypochlorite was used as an irrigant under rubber dam isolation with infiltration anaesthesia. The working length was confirmed with a radiograph, and obturation was performed using cold lateral compaction. The GP cones were extruded through the apex to find their location during the surgical procedure. The access cavity was temporarily restored with Cavit (3M ESPE).

In the second visit, performed 24 hours later, an infraorbital block anaesthesia and infiltration anaesthesia in the palate were administered. A submarginal horizontal incision, 5 mm from the marginal gingiva with two vertical releasing incisions was made, and a full-thickness muco-periosteal flap was raised to obtain a bone window of less than 10 mm. Curettage of the lesion was performed with spoon excavator, and a biopsy sample was obtained. A 3-mm root end was resected using high-speed hand-piece with rear exhausting air, and the access cavity of 3-mm depth preparation was filled with Premixed Bioceramic (Endosequence Root Repair Material). The surgical site was closed with 3/0 silk sutures (Sinorgmed, Shandong Sinorgmed Co, Ltd, China) using interrupted sutures (Figure 2). The patient was discharged with a prescription for amoxicillin of 500 mg three times a day, paracetamol of 500 mg three times a day for five days, and chlorhexidine mouth rinse two times a day until sutures were removed.

The third visit was scheduled after 10 days, and during that visit, sutures were removed, surgical site was examined, and access cavity was restored definitively with direct composite restoration and healing was assessed clinically and radiographically with periapical radiograph. The patient was emphasised with oral hygiene instructions. The histopathologic examination confirmed the presence of radicular cyst. The patient was followed at 30 days and 4 months, and clinical radiographic examination was performed which showed complete healing of swelling and radiolucency at 4 months (Figure 2F).

## DISCUSSION

DI, also known as dens in dente, is a developmental anomaly of a tooth due to invagination of the dental epithelium into the underlying dental papilla during tooth formation. Studies have reported a prevalence of DI ranging from 0.25 to 10%.<sup>3</sup> The tooth's unique clinical and radiographic features, such as a deep pit on the lingual aspect, can lead to increased susceptibility to caries, pulp necrosis, and periapical pathology, while also causing cosmetic concerns due to enamel defects. To enhance diagnostic accuracy, CBCT has emerged as a valuable tool, providing three-dimensional visualisation and superior detection capabilities for DI

compared to conventional periapical radiographs.<sup>4</sup> Studies have compared the diagnostic accuracy of periapical radiographs and CBCT in detecting DI, with CBCT being significantly more accurate in detecting the presence and extent of DI, as well as providing a three-dimensional visualisation, which helps in treatment planning.<sup>5</sup>

The noteworthy aspect of this case was the rare association of a Type II DI and an apical lesion, which was successfully treated with conventional root canal therapy and apical surgery. Anatomical considerations, aesthetic outcomes, and ease of access play significant roles in the choice of surgical approach. The labial approach was preferred over the palatal approach for this case, as it provides direct access to the apical area, resulting in better visibility and access to the root apex. The labial approach involves a small incision in the gingival margin, resulting in less postoperative discomfort and faster healing time than the palatal approach. The literature supported this finding, as patients treated with the labial approach had less postoperative discomfort and faster healing times than those treated with the palatal approach.<sup>6,7</sup>

This case report highlighted the importance of early detection and intervention in preventing the progression of dental lesions. The patient presented with a slowly growing swelling, which may have been present for some time before seeking the medical attention. The case report also suggested that bioceramic root repair materials may offer a practical alternative to traditional root-end filling materials, as they have shown favourable biocompatibility and sealing ability.

The prognosis of endodontic treatment can be uncertain or guarded, as it is influenced by multiple factors. One of the significant factors affecting the prognosis is the size and location of the lesion. Large lesions present for a long time and those found near important structures such as the maxillary sinus or inferior alveolar nerve can make treatment more challenging and the prognosis less certain. Additionally, extensive bone loss or periapical pathology can negatively affect the prognosis. Finally, patient compliance with post-treatment care is critical to the success of endodontic treatment, as non-compliance with restorative treatment and maintenance of good oral hygiene can lead to a less certain prognosis.<sup>8</sup> Clinicians must carefully evaluate these factors to develop a proper treatment plan and discuss the anticipated outcomes with the patient.

Bioceramic materials, renowned for their superior biocompatibility, sealing ability, bioactivity, and antimicrobial properties, have emerged as an ideal choice for effectively managing complex endodontic cases like DI with an apical lesion. Risk of pain or inflammation after bioceramic sealer extrusion to periapical tissues is minimal.<sup>9</sup> Mineral trioxide aggregate (MTA) and bioceramics remain the gold standard.<sup>10</sup> However, there is a need for further researches to decide the success rate of various treatment options. Comparison of different treatment modalities for such cases is also needed to determine the most effective and predictable treatment option.

## PATIENT'S CONSENT:

Written informed consent was obtained from the patient for this chosen treatment.

## COMPETING INTEREST:

The authors declared no competing interest.

## AUTHORS' CONTRIBUTION:

SS: Performed the case, drafting and final approval of the report.

MMA: Performed the case and final approval of the report.

FAK: Supervised the case, manuscript drafting and critical analysis.

PRH: Drafting of the manuscript.

MM: Supervised the case, drafting and discussion writing.

All authors have approved the final version of the manuscript to be published.

## REFERENCES

1. Zhu J, Wang X, Fang Y, den Hoff JW, Meng L. An update on the diagnosis and treatment of dens invaginatus. *Aust Dent J* 2017; **62**(3):261-75. doi: 10.1111/adj.12513.
2. Karamifar K, Tondari A, Saghir MA. Endodontic periapical lesion: An overview on the aetiology, diagnosis and current treatment modalities. *Eur Endod J* 2020; **5**(2):54-67. doi: 10.14744/eej.2020.42714.
3. González-Mancilla S, Montero-Mirallés P, Saúco-Márquez JJ, Areal-Quecuty V, Cabanillas-Balsera D, Segura-Egea JJ. Prevalence of Dens Invaginatus assessed by CBCT: Systematic review and meta-analysis. *J Clin Exp Dent* 2022; **14**(11):e959-66. doi: 10.4317/jced.59849.
4. Thakur S, Thakur NS, Bramta M, Gupta M. Dens invagination: A review of literature and report of two cases. *J Nat Sci Biol Med* 2014; **5**(1):218-21. doi: 10.4103/0976-9668.127341.
5. Mabrouk R, Berrezouga L, Frih N. The accuracy of CBCT in the detection of dens invaginatus in a tunisian population. *Int J Dent* 2021; **2021**:8826204. doi: 10.1155/2021/8826204.
6. Winnier J, Suresh R. A comparative evaluation of a labial approach with a conventional palatal approach for endodontic access in primary maxillary incisors: A pilot study. *Int J Clin Pediatr Dent* 2020; **13**(1):53-6. doi: 10.5005/jp-journals-10005-1704.
7. Kong J, Peng Z, Zhong T, Shu H, Wang J, Kuang Y, et al. Clinical analysis of approach selection of extraction of maxillary embedded mesiodens in children. Schmalz G, Ed. *Dis Markers* 2022; **2022**:6517024. doi: 10.1155/2022/6517024.
8. Nassar H, Al-Dabbagh N, Aldabbagh R, Albahiti M, Jadu FM, Qutob A, et al. Dental follow-up and maintenance index: The development of a novel multidisciplinary protocol. *Heliyon* 2020; **6**(5):e03954. doi: 10.1016/j.heliyon.2020.e03954.
9. Koch KA, Brave DG, Nasseh AA. Bioceramic technology: Closing the endo-restorative circle, Part I. *Dent Today* 2010; **29**(2):100-5.
10. Lima NFF, Dos Santos PRN, Pedrosa MDS, Delboni MG. Cimentos biocerâmicos em endodontia: revisão de literatura. *Rev Fac Odontol - UPF* 2017; **22**(2). Available from: <http://seer.upf.br/index.php/rfo/article/view/7398> [cited 22 July 2023].

• • • • •