

Correlation of Lung Ultrasound and Computed Tomography Findings in COVID-19 Pneumonia

Cengiz Karacaer¹, Oguz Karabay², Yasemin Gunduz³, Selcuk Yaylaci¹ and Ertugrul Guclu²

¹Department of Internal Medicine, Sakarya University Research and Training Hospital, Turkey

²Department of Infectious Diseases, Sakarya University Research and Training Hospital, Turkey

³Department of Radiology, Sakarya University Research and Training Hospital, Turkey

ABSTRACT

Objective: To evaluate the laboratory confirmed COVID-19 pneumonia and correlate the findings obtained by thorax ultrasound (USG) and thorax computed tomography (CT).

Study Design: Observational study.

Place and Duration of Study: Departments of Infection Disease, Internal Medicine and Radiology, Sakarya Training and Research Hospital, Sakarya, Turkey, between March and May 2020.

Methodology: This study was consisted of 100 adult patients having rRT-PCR positive COVID-19 pneumonia diagnosed by thorax CT. The clinical features, thorax USG and CT findings of these patients were recorded and expressed. USG and thorax CT findings were scored using a method described before. Continuous variables were expressed as mean (\pm SD) values. The Kolmogorov-Smirnov test was used for the normal distribution test, and continuous variables were compared using the Mann-Whitney U test. USG and CT performed at time of admission to the hospital. Descriptive statistics were conducted based on the structures of variable.

Results: A total of 100 patients (54 men and 46 women; mean age, 59.88 ± 13.03 years; range, 28-91 years) with COVID-19 pneumonia were evaluated. Involvement areas on the lower posterior of the right side were detected as 70% by ultrasound and 74% by CT. Positively correlation was detected in lung scans assessed by USG and CT ($p < 0.001$, $r = 0.705$).

Conclusion: Ultrasound has several advantages including no ionizing radiation exposure for health care workers, being a safe, fast and non-invasive diagnostic technique with bedside usage. Hence, ultrasound is an efficient alternative to diagnosis and monitor of patients with COVID-19 pneumonia.

Key Words: COVID-19, Lung ultrasound, Pneumonia, RRT-PCR.

How to cite this article: Karacaer C, Karabay O, Gunduz Y, Yaylaci S, Guclu E. Correlation of Lung Ultrasound and Computed Tomography Findings in COVID-19 Pneumonia. *J Coll Physicians Surg Pak* 2020; **30(Suppl1)**:S147-S152.

INTRODUCTION

Severe acute respiratory syndrome (SARS)-associated coronavirus-2 (SARS-CoV-2) is a member of the coronavirus family and a new strain of beta-corona virus which infects humans.¹ SARS CoV-2 spreads globally and this outbreak was declared as pandemic.

COVID-19 infection causes profoundly scattered lesions in the lungs and acute respiratory distress syndrome (ARDS) by proceeding through lower respiratory tract. Patients represent a wide spectrum; from mild symptoms, same patients develop pneumonia, ARDS or multiple organ dysfunction syndrome to death.² For these reasons, accurately evaluating the pathological lung examination and lung aeration is highly critical.

The diagnosis is made by real-time reverse transcriptase-polymerase chain reaction (rRT-PCR) for the confirmation of clinical diagnosis. Nasopharyngeal swabs have been tested using RT-PCR test has 50-60% sensitivity.^{3,4} Sample collection method and the quality of the test affect the results. The false negative results might be obtained if the viral replication is not in window phase along with contributing to the viral spread through infected people at this period of the pandemic.⁵ Scanning techniques such as computed tomography (CT) decreased the risk of false negative diagnosis of COVID-19 in nucleic acid tests as 31 vs. 64 with the difference rate of 51.6%, whereas the nucleic acid test demonstrated 64.5% positive rate (20 out of 31). Thorax CT screening, having 98% sensitivity, is extremely crucial in patients with false negative RT-PCR results.^{6,7} It is still unclear whether the RT-PCR is the gold standard and the false negative or false positive results are frequent.⁴ Typical pneumonia associated clinical symptoms and screenings have been detected in many patients, yet RT-PCR tests yielded negative results. The reason behind the false positive results in this clinical application remained to be investigated.⁸

Correspondence to: Dr. Cengiz Karacaer, Department of Internal Medicine, Sakarya University Research and Training Hospital, Turkey
E-mail: karacaerc@yahoo.com

Received: August 13, 2020; Revised: November 05, 2020;
Accepted: November 05, 2020
DOI: <https://doi.org/10.29271/jcpsp.2020.Suppl1.S147>

Pneumonia and ARDS diagnosis are obtained through chest radiography, ultrasound and CT. Thorax CT is crucial to visualize chest findings of pneumonia. Moreover, ultrasound offers high capacity evaluation of COVID-19 pulmonary involvement findings in patients who are not convenient for CT and pregnant women, and contributes to the follow-ups and treatment plans. Routine utilization of bedside lung ultrasound is essential for patients with COVID-19 pneumonia and ARDS in terms of monitoring the diagnosis, treatment and disease progression caused by COVID-19. In this study, the aim was to validate the pneumonia infiltration findings of PCR-positive COVID-19 patients who were evaluated by lung ultrasound at the bedside and compared with chest CT findings.

METHODOLOGY

This study was approved by Ethical Committee of Sakarya University Faculty of Medicine (date: 13.04.2020, approval ID: 16214662/050.01.04/74). Laboratory approval of COVID-19 viral infection is performed by RT-PCR analysis using throat swab samples. COVID-19 positive adult patients, who were hospitalised in Sakarya University Training and Research Hospital Infectious Diseases Clinic, were included in the study. Patients who were 18 years old or older, non-pregnant and RT-PCR confirmed COVID-19 positive diagnosis were included in the study. Pregnancy, PCR negative COVID-19 diagnosis like as isolated CT signs, malignancy, lobectomy history, tuberculosis, heart failure and chronic renal failure were among the exclusion criteria.

Hemogram and blood biochemical parameters were recorded from patients' files on the first hospitalisation. Blood parameters were evaluated simultaneously with CT and US. Blood samples for count blood cell examination were collected in tubes containing ethylene diamine tetraacetic acid. Cells were counted by an automatic analyser (CELL DYN 3700). The reference range of the white blood cell count was defined as 4500 to 10.000 K/UL. C-reactive protein (CRP) was measured with an immuno turbidimetric analyser (BNII/BN ProSpec System; Siemens Healthineers, Erlangen, Germany).

The LOGIQ™ 200 GE pro series, medical systems, model number 2270968 class1 Oct 2005 (GE, KOREA) equipped with a convex array ultrasound probe (3.5 MHz) was used in this study. Ultrasound chest monitoring was performed regardless of CT images that were obtained at the initial admission of the patients. In this study, no additional thorax tomography scanning was performed. CT findings on the day of hospitalisation were evaluated by a radiologist. Ultrasonographic evaluation was performed by an internal medicine specialist (Dr. C.K.) who specialized in ultrasonographic diagnosis. CT evaluation was performed by a radiologist (Dr. Y.G.) - USG and CT practitioners examined the patients independently. Reports were made independently of each other.

In order to avoid from the contagiousness, the personnel who performed ultrasound, fully equipped with protective gowns.

Ultrasound device and the probe were disinfected prior to each patient examination. Due to the risk of contagiousness, ultrasound scanning was made in bedsides in patient rooms. Ultrasound examination included sternal angle planes of front, side and rear areas of left and right walls, front and rear axillary lines, along with upper and rear areas while lying on a side (Figure 1).⁹ Anterolateral regions of the chest wall were investigated in patients lying on their backs, whereas the rear regions were examined on lateral position. Twelve lung region scores have been designated as ultrasound score of the patients. As seen in figure-1, the zones were defined as upper anterior, mid anterior, mid posterior, inferior anterior, inferior lateral, inferior posterior zone, and left anterior, lingula anterior, lingula posterior, inferior anterior, inferior lateral, inferior posterior zone. Scoring was performed as defined by Xu *et al.*⁶ The same scoring was applied to both ultrasound and CT, based on the number of zone involvement.⁶ Zone involvement scoring was made as follows: Normal ventilation (N, score 1), 1 zone involvement (score 2), 2 zone involvements (score 3), 3 zone involvements (score 4), 4 or more zone involvements (score 5). The patterns of lung ultrasound were in accordance with a comet tail sign, consolidation and pleural effusion.¹⁰

Computed tomography examinations were obtained from Tohsiba Alexion 16 MDCT (Otowara, Japan) with 5 mm cross section thickness. Both lungs were evaluated in a total of 12 areas. Investigation of the involvement in the upper part of the lower lobe superior segments of both lungs was ignored as these regions were not evaluated ultrasonographically. In these areas, ground glass densities, consolidations, and air bronchograms and pleural effusions were recorded. These involvements were scored according to ultrasonography scoring.¹⁰

Data analysis was performed by using SPSS-22 for Windows (Statistical Package for Social Science, SPSS Inc. Chicago IL, USA®Z). The variables were investigated using visual (histograms, probability plot) and analytical methods (Kolmogorov-Smirnov/Shapiro-Wilk's test) to determine whether or not they are normally distributed. Categorical variables are interpreted by frequency tables. Analyses were performed to describe and summarise the distributions of variables. The continuous variables were expressed as mean and standard deviation. While investigating the associations between non-normally distributed and/or ordinal variables, the correlation coefficients and their significance were calculated using Spearman correlation. The statistically significant two tailed p-value was considered as <0.05.

RESULTS

A total of 100 COVID-19 RT-PCR positive patients (mean age: 59.88±13.03 years, range: 28-91 years old) were included to the study, in which 54 of them were males (mean age: 59.98±13.47 years, range: 28-87 years old) and 46 were females (mean age: 59.76±12.63 years, range: 35-91 years old). The demographic and laboratory findings were outlined at Table I.

Table I: Demographic and laboratory findings.

Parameters / Mean \pm S.D.			
Age	59.88 \pm 13.03 (28-91)	Sex (M/F)	54/46
CK (U/L)	213.45 \pm 537.55	CK-MB (U/L)	17.02 \pm 9.73
WBC (K/uL)	6.17 \pm 2.64	D-Dimer (μ FFU/L)	714.30 \pm 958.99
PLT (K/uL)	180.72 \pm 67.68	INR	1.18 \pm 0.37
NEU (K/uL)	4.15 \pm 2.42	CREA (mg/dL)	0.97 \pm 0.95
LYM (K/uL)	1.48 \pm 0.69	ALT (U/L)	28.69 \pm 19.86
HGB (g/dL)	12.85 \pm 1.73	AST (U/L)	34.17 \pm 19.70
CRP (mg/L)	44.69 \pm 44.33	Ferritin (mg/L)	433.59 \pm 493.38
Alb (mg/L)	34.96 \pm 4.65	LDH (U/L)	283.38 \pm 118.96
Glob (mg/L)	29.23 \pm 4.81	pH	7.40 \pm 0.06
Using of ACEI	12	HT	26
Using of ARB	14	T2DM	31
COPD	7	CAD	6

WBC: White blood cell, CK: Creatine Kinase, PLT: Platelet, NEU: Neutrophil, MCV: Mean corpuscular volume, LYM: Lymphocyte, Hgb: Hemoglobin, Hct: Hematocrit, Alb: Albumin, ALT: Alanine aminotransferase, AST: Aspartate aminotransferase, CRP: C-reactive protein, Crea: Creatinine, LDH: Lactate dehydrogenase, ESR: Erythrocyte sedimentation rate, ACEI: Angiotensin converting enzyme inhibitor, T2DM: Type-2 Diabetes Mellitus, ARB: Angiotensin receptor blocker, COPD: Chronic obstructive pulmonary disease, HT: Hypertension, CAD: Chronic arterial disease.

Table II: Symptoms and pathologic laboratory findings in diagnosis.

Parameters† (n=100)				
Weakness	24	Ferritin	1000-2069	13
Muscle and joint pain	5		500-1000	11
Loss of taste	4		500-200	32
Inability to smell	4		200<	44
Head ache	4	LDH	>150	94
Chest pain	5	ALT	>80	3
Dyspnea	22		>40	20
Cough	58	AST	>80	4
Sore throat	10		>40	26
Fever	25	CK	1000-4620	3
Leucopenia	28		400-1000	5
Leukocytosis	7	D-Dimer	4000-4760	4
Neutropenia	5		2000-4000	4
Lymphopenia	26		1000-2000	7
Eosinopenia	84		500-1000	22
Anemia(M/F)	20/15	Albumin	2-3	13
CRP >10	73		3-4	47

† All results were expressed as a percentage. CRP: C-reactive protein, LDH: Lactate dehydrogenase, ALT: Alanine aminotransferase, AST: Aspartate aminotransferase, CK: Creatine kinase.

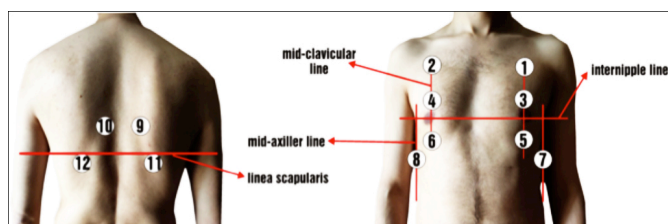


Figure 1: Left lung areas; 1: Upper anterior, 3: Mid anterior, 5: Inferior anterior, 7: Inferior lateral, 10: Lingula posterior, 12: Inferior posterior. Right lung areas; 2: Upper anterior, 4: Mid anterior, 6: Inferior anterior, 8: Inferior lateral, 9: Mid posterior, 11: Inferior posterior zone.

Common symptoms and pathological findings were represented in Table II, which shows high ferritin, LDH, ALT, AST, CK, and D-Dimer levels were found in 56, 94, 20, 26, 8 and 37 patients in 100, respectively, whereas 60 patients had low levels of albumin (Table II). Radiologic scanning demonstrated the rates of lung zonal involvements. According to the involvement areas detected by ultrasound, the findings were

70% lower posterior, 54% mid posterior, 42% mid anterior on the right side, and 65% lower posterior, 54% lingua posterior on the left side. Whereas by CT, the findings were 74% lower posterior, 53% lower lateral on the right side, and 64% lower posterior, and 51% lower anterior on the left side.

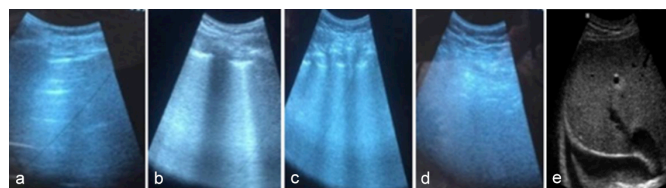


Figure 2 (a,b,c,d,e): The pattern that represent from normal aeration of the lungs (a) to consolidation showing severe degredation (d). (a) A-lines: horizontal alline to the pleura: Normal Lung; (b) B-lines: lineal vertical artifact that arise from pleural line: Mild pulmonary edema (c) B-lines: Moderate/severe pulmonary edema (d) Consolidation: Severe pulmonary edema (e) Pleural effusion.

In upper anterior, lower anterior and lower posterior zones, ultrasound and CT findings represented similar infiltration

rates, whereas there was discordance in mid anterior, mid posterior and lower lateral zones, along with partial discordance in lingua anterior and posterior zones. In mid anterior, mid posterior, lingua anterior and lingua posterior, elevated involvements were detected by ultrasound compared to CT. Zone involvements in lower lateral and anterior zones were higher in CT screenings. In the correlation analysis (Spearman), positively linear relationship was detected in chest scans obtained by ultrasound and CT ($p < 0.001$, $r = 0.705$).

DISCUSSION

In this study, the authors compared the radiological scanning methods used for COVID-19 positive patients and observed 0.705 rate correlation in ultrasound against CT. It can be a reliable alternative diagnostic tool only in cases which have contraindication where CT is not available or where there is a high concern for malignancy secondary to diagnostic radiation.¹¹ According to our current knowledge, this study is the pioneer in correlating different screening methods in COVID-19 patients. Analysing the zone numbers, we found that zero represented full accordance, zones up to 5 showed harmony between ultrasound and CT, yet there were clear discordances in zones 7 and 11. The discordances based on the zone number might be resulted from the experience of the personnel who performed scanning or the quality of ultrasound. In this research, a significant efficacy between ultrasound and CT was demonstrated with a correlation accordance of 0.705. Even though ultrasound is more laborious, it is critically beneficial since it infects fewer personnel, exposes patients with lower radiation and reduces costs during the process. It is believed that lung ultrasound should become widespread since the rate of viral infections like COVID-19 might increase in upcoming years.

Lung ultrasound is an essential alternative in the emergency room for the early detection of adult pneumonia.¹² Its advantages are; since the radiation dose required to be taken annually with a single-body CT scan is full, the absence of an increased risk of secondary malignancy to radiation, cost effectiveness, easy applicability, repeatability and investigation simultaneously with the entire population, especially in the pediatric and young adolescent and pregnant population. Lung ultrasound saves additional time.¹³ Its advantages include late maintenance application, less irradiation and low costs (as it is found on countries with increased sources) and it reduces the necessity of lying on the back as CT screening requires.¹⁴ Lung ultrasound is almost equivalent to CT in detecting most disorders, can be repeated at any time and provides additional information.^{9,15} Feasibility is high. Lung ultrasound may seem complicated at the first glance, but solely requires a change in the way of thinking. Ultrasound is a safe, fast, non-invasive diagnostic technique suitable for bedside use, which can help doctors resolve clinical confusions on time and extensively speed up the differential diagnosis procedure.¹⁶ Lung ultrasound seems to be a key tool for early diagnosis of the most common complications of mechan-

ical ventilation, such as pleural effusion, atelectasis, alveolar consolidation associated with ventilator.¹⁷

In Figure 2, ultrasound samples that are used in this study represent a spectrum from normal lung infiltration to pulmonary consolidation, which severely decreases infiltration and causes severe breathing disorders. However, tomographic screenings demonstrated ground glass opacity regions in posterior peripheral areas of bilateral lower lobes, lower right lobe posterior periphery and upper left lobe anterior periphery. In patients with ARDS, the regional lung ultrasound score is strongly correlated with tissue density assessed by quantitative CT, as the elevation in each score is associated with a significant increase in density from 0 to 3.¹⁸ Lung ultrasound stands for an additional labour for the doctors. However, an extensive review of lung ventilation assessment ranges from 8 minutes for specialists to 10 minutes for trainees.¹⁹

Regarding the number of zone involvements, it was believed that the non-overlap between ultrasound and CT may be due to the artifact exposure of ultrasound in some zones, especially in zone 6, zone 7 and zone 11 involvements. Overall, positive correlation has been detected in correlation analysis performed with ultrasound and CT ($p < 0.001$, $r = 0.705$).

Ultrasound is especially critical in the follow-up of patients with pneumonia. In cases requiring repeated CT extraction, ultrasound evaluation of the lungs is a crucial alternative. Previous publications manifested that lung involvement is bilateral, has ground glass opacity appearance, wedge-like appearance with pleural base, which are detected by CT scans. Major consolidations were evaluated as air bronchogram.²⁰ Pleural effusion was not observed some studies.²¹ However, Cheng²² and Xu⁶ *et al.* showed the presence of pleural effusion as 4% rate in their studies. In the present study, we found 2% non-spreading effusion. Irregular or confluent lesions exhibited a tendency to spread throughout the pleura. The most affected lobe was the right lower lobe, followed by the upper and lower left lobes. This is due to the natural course of the disease. In a 64-patient study conducted by Wong *et al.*, pleural effusion was detected as non-spreading and the lowest rate was found 3%.²³ Similarly, in our study, upper and especially lower lobe involvements were more common, as seen in the Tables. In contrast, the reason behind the high incidence in middle zones seemed to be due to the artifacts. Thus, lung ultrasound exhibited superior in for COVID-19 pneumonia follow-up.

In terms of laboratory tests and results, there was a decrease in lymphocyte count and albumin and an increase in ferritin, LDH, CK, and CK-MB in most patients. This result was thought to be due to changes in the immune cells cytokine response of the SARS-CoV-2 on the immune system. In a study conducted in Wuhan, China, results supporting our findings were obtained.²⁴

The main limitations of this study were its relatively small

number of patients and single-centre design. In the evaluation of the lung by ultrasonography, poor sound conductivity of the air in the alveolar is one of the main disadvantages. Despite this disadvantage, the loss of alveolar aeration cannot create a clear acoustic window. Because of these disadvantages, it cannot be used for routine evaluation of the lungs and is, therefore, dependent on user experience. Such as its results changeable by operator's experience. Another disadvantage was, US is not suitable for longitudinal comparison as it is operator dependent.

These results represent that ultrasound findings are comparable to CT findings, whereas with experienced specialists and with higher patient population ultrasound might yield better outcomes. The obvious discordance between ultrasound and CT in the lower lateral zones of lungs might be resulted from the inexperience of the physician.

CONCLUSION

US may be an alternative method for first-line diagnosis for chest CT imaging and chest X-ray imaging at all stages of COVID-19 disease, especially in children, pregnant women, intensive care patients with transport problems, such as lack of ionizing radiation exposure, easy application, and repeatability. Combination of lung US sonographic patterns in pandemic areas with clinical and laboratory findings, followed by chest CT for approval in selected cases, can help early diagnosis, therapeutic decisions, and follow-up monitoring of COVID-19 pneumonia in both children and adults.

ETHICAL APPROVAL:

This study was approved by Ethical Committee of Sakarya University Faculty of Medicine (date: 13.04.2020, approval ID: 16214662/050.01.04/74).

PATIENTS' CONSENT:

Informed consents were obtained from all participants.

CONFLICT OF INTEREST:

Authors declared no conflict of interest.

AUTHORS' CONTRIBUTION:

CK: Data collection, compiling, statistics and discussion.

OK: Led and conceived the project and authored the manuscript.

SY: Design articles and analysed data.

YG: Collect and analysed data.

EG: Helped perform the analyses with constructive discussions.

REFERENCES

- Lu R, Zhao X, Li J, Niu P, Yang B, Wu H, et al. Genomic characterisation and epidemiology of 2019 novel coronavirus: implications for virus origins and receptor binding. *Lancet* 2020; **395(10224)**:565-74. doi: 10.1016/S0140-6736(20)30251-8.
- Wu C, Chen X, Cai Y, Xia J, Zhou X, Xu S, et al. Risk factors associated with acute respiratory distress syndrome and death in patients with coronavirus disease 2019 pneumonia in Wuhan, China. *JAMA Intern Med* 2020; **180(7)**:934-43. doi: 10.1001/jamainternmed.2020.0994.
- Xiao AT, Tong YX, Gao C, Zhu L, Zhang YJ, Zhang S. Dynamic profile of RT-PCR findings from 301 COVID-19 patients in Wuhan, China: A descriptive study. *J Clin Virol* 2020; 104346. doi: 10.1016/j.jcv.2020.104346.
- Diagnosis of the Coronavirus disease (COVID-19)_ rRT-PCR or CT? | Elsevier Enhanced Reader [Internet]. [cited 2020 May 9].
- Rothe C, Schunk M, Sothmann P, Bretzel G, Froeschl G, Wallrauch C, et al. Transmission of 2019-NCOV infection from an asymptomatic contact in Germany. *N Eng J Med* 2020; **382(10)**:970-1.
- Xu X, Yu C, Qu J, Zhang L, Jiang S, Huang D, et al. Imaging and clinical features of patients with 2019 novel coronavirus SARS-CoV-2. *Eur J Nucl Med Mol Imaging* 2020; **47(5)**:1275-80. doi: 10.1007/s00259-020-04735-9
- Huang P, Liu T, Huang L, Liu H, Lei M, Xu W, et al. Use of chest CT in combination with negative RT-PCR assay for the 2019 novel coronavirus but high clinical suspicion. *Radiology* 2020; **295(1)**:22-3. doi: 10.1148/radiol.2020200330.
- Zhang Q, Zhao Q. Inactivating porcine coronavirus before nuclei acid isolation with the temperature higher than 56 °C damages its genome integrity seriously. *bioRxiv* 2020; doi.org/10.1101/2020.02.20.958785.
- Lichtenstein D, Goldstein I, Mourgeon E, Cluzel P, Grenier P, Rouby JJ. Comparative diagnostic performances of auscultation, chest radiography, and lung ultrasonography in acute respiratory distress syndrome. *Anesthesiol* 2004; **100(1)**:9-15. doi: 10.1097/00000542-200401000-00006.
- IZhou S, Wang Y, Zhu T, Xia L. CT features of coronavirus disease 2019 (COVID-19) pneumonia in 62 patients in Wuhan, China. *A J Roentgenol* 2020; **214(6)**:1287-94. doi: 10.2214/AJR.20.22975.
- Abbotts R, Topper MJ, Biondi C, Fontaine D, Goswami R, Stojanovic L, et al. DNA methyltransferase inhibitors induce a BRCAness phenotype that sensitizes NSCLC to PARP inhibitor and ionizing radiation. *Proc Natl Acad Sci U S A* 2019; **116(45)**:22609-18.
- Lichtenstein DA, Mezière GA. Relevance of lung ultrasound in the diagnosis of acute respiratory failure the BLUE protocol. *Chest* 2008; **134(1)**:117-25. doi: 10.1378/chest.07-2800.
- Helm JS, Rudel RA. Adverse outcome pathways for ionizing radiation and breast cancer involve direct and indirect DNA damage, oxidative stress, inflammation, genomic instability, and interaction with hormonal regulation of the breast. Vol. 94, *Archives of Toxicology. Springer* 2020; p.1511-49.
- Brenner DJ, Elliston CD, Hall EJ, Berdon WE. Estimated risks of radiation-induced fatal cancer from pediatric CT. *Am J Roentgenol* 2001; **176(2)**:289-96.
- Reissig A, Copetti R, Mathis G, Mempel C, Schuler A, Zechner P, et al. Lung ultrasound in the diagnosis and follow-up of community-acquired pneumonia: A prospective,

- multicenter, diagnostic accuracy study. *Chest* 2012; **142(4)**: 965-72. doi: 10.1378/chest.12-0364.
16. Moore CL, Copel JA. Current concepts: Point-of-care ultrasonography. Vol. 364, New England Journal of Medicine. Massachussetts Medical Society; 2011. p. 749-57.
17. Mongodi S, Bouhemad B, Orlando A, Stella A, Tavazzi G, Via G, et al. Modified lung ultrasound score for assessing and monitoring pulmonary aeration. *Ultraschall in der Medizin* 2017; **38(5)**:530-7. doi: 10.1055/s-0042-120260.
18. Chiumello D, Mongodi S, Algieri I, LucaVergani G, Orlando A, Via G, et al. Assessment of lung aeration and recruitment by CT scan and ultrasound in acute respiratory distress syndrome patients. *Crit Care Med* 2018; **46(11)**:1761-8. doi: 10.1097/CCM.0000000000003340.
19. Rouby JJ, Arbelot C, Gao Y, Zhang M, Lv J, An Y, et al. Training for lung ultrasound score measurement in critically ill patients. *Am J Respir Crit Care Med* 2018; **198(3)**: 398-401. doi: 10.1164/rccm.201802-0227LE.
20. Bernheim A, Mei X, Huang M, Yang Y, Fayad ZA, Zhang N, et al. Chest CT findings in coronavirus disease-19 (COVID-19): Relationship to duration of infection. *Radiology* 2020; **295(3)**:200463. doi: 10.1148/radiol.2020200463.
21. Lai CC, Shih TP, Ko WC, Tang HJ, Hsueh PR. Severe acute respiratory syndrome coronavirus 2 (SARS-CoV-2) and coronavirus disease-2019 (COVID-19): The epidemic and the challenges. *Int J Antimicrob Agents* 2020; **55(3)**:105924. doi: 10.1016/j.ijantimicag.2020.105924.
22. Cheng Z, Lu Y, Cao Q, Qin L, Pan Z, Yan F, et al. Clinical Features and Chest CT Manifestations of Coronavirus Disease 2019 (COVID-19) in a Single-Center Study in Shanghai, China. *AJR Am J Roentgenol* 2020; **215(1)**:121-6.
23. Wong HYF, Lam HYS, Fong AHT, Leung ST, Chin TWY, Lo CSY, et al. Frequency and distribution of chest radiographic findings in covid-19 positive patients. *Radiology* 2019; **296(2)**:201160. doi: 10.1148/radiol.2020201160.
24. Chen N, Zhou M, Dong X, Qu J, Gong F, Han Y, et al. Epidemiological and clinical characteristics of 99 cases of 2019 novel coronavirus pneumonia in Wuhan, China: A descriptive study. *Lancet* 2020; **395(10223)**:507-13.

• • • • •