

# Application of Bilateral Cerebral Perfusion + Balloon Occlusion of Descending Aorta + Antegrade Perfusion of Lower Body in DeBakey Type I Aortic Dissection

Yang Yujian<sup>1</sup>, Luo Juan<sup>2</sup>, Zhang Peiyun<sup>2</sup>, Feng Yaoguang<sup>1</sup>, Asfandyar Khan<sup>2</sup> and Lei Zhengwen<sup>1</sup>

<sup>1</sup>Department of Thoracic and Cardiovascular Surgery, Changsha Hospital of Traditional Chinese Medicine (Changsha Eighth Hospital), Changsha, Hunan, China

<sup>2</sup>Department of Thoracic and Cardiovascular Surgery, First Affiliated Hospital of Hengyang Medical School, University of South China, Hengyang, Hunan, China

## ABSTRACT

**Objective:** To evaluate the efficacy of a new perfusion method in DeBakey Type I aortic dissection surgery, with the goal of enhancing thorough organ protection and optimising patient outcomes.

**Study Design:** Descriptive study.

**Place and Duration of the Study:** Department of Thoracic and Cardiovascular Surgery, The First Affiliated Hospital of the University of South China, from January 2020 to December 2021.

**Methodology:** Thirty-two patients undergoing total aortic arch replacement with descending aortic stenting were included in the study. The new perfusion method involved a combination of bilateral selective cerebral perfusion, descending aortic balloon occlusion, and antegrade lower body perfusion. Lower limb ischaemic complications and mortality rate were the main outcome measures. Surgical procedures and patient data were collected and analysed.

**Results:** No cases of paraplegia, intestinal necrosis, or lower-limb ischaemia were observed. The new perfusion method effectively protected lower-body organs, with a short duration of lower-body ischaemia during surgery. The overall mortality rate was 3.13%, and postoperative complications were minimal, resulting in satisfactory survival rates.

**Conclusion:** The combination of perfusion techniques, including bilateral selective cerebral perfusion, descending aortic balloon occlusion, and antegrade lower body perfusion, proved effective in improving the outcomes for DeBakey Type I aortic dissection surgery. Further research is needed to confirm the long-term benefits of this approach.

**Key Words:** DeBakey type I aortic dissection, Descending aortic balloon blockade, Lower body antegrade perfusion, Bilateral selective cerebral perfusion.

**How to cite this article:** Yujian Y, Juan L, Peiyun Z, Yaoguang F, Khan A, Zhengwen L. Application of Bilateral Cerebral Perfusion + Balloon Occlusion of Descending Aorta + Antegrade Perfusion of Lower Body in DeBakey Type I Aortic Dissection. *J Coll Physicians Surg Pak* 2024; **34(12)**:1484-1489.

## INTRODUCTION

Aortic arch surgery has traditionally focused on prioritising protection for the heart and brain, often adopting the arch first approach, while neglecting adequate perfusion and protection for lower body and abdominal organs.<sup>1-5</sup> This approach can result in inadequate perfusion to critical organs such as the spinal cord, gastrointestinal tract, kidneys, and lower limb organs.

Conventional lower-body organ protection methods, such as deep hypothermic circulatory arrest (DHCA), have been associated with an increased risk of ischaemia-reperfusion injury, higher mortality rates, and postoperative complications.<sup>6</sup> Therefore, there is a need to develop innovative perfusion techniques that provide effective organ protection during aortic arch surgery, particularly for patients with DeBakey Type I aortic dissection. A new perfusion technique for DeBakey Type I aortic dissection was approved by the Hospital Ethics Committee, which improved outcomes.<sup>7,8</sup>

The rationale of the present study was to address the shortcomings of traditional perfusion methods in aortic arch surgery by implementing a new perfusion technique for DeBakey Type I aortic dissection. This was justified by the need to improve patient outcomes and minimise postoperative complications associated with inadequate lower body organ protection during aortic arch surgery. The new perfusion method, approved by the hospital ethics committee, was developed to provide effective and comprehensive protection to both the cerebral and

Correspondence to: Dr. Lei Zhengwen, Department of Thoracic and Cardiovascular Surgery, First Affiliated Hospital of Hengyang Medical School, University of South China, Hengyang, Hunan, China  
E-mail: leizhengwen0803@163.com

Received: January 10, 2024; Revised: August 25, 2024;

Accepted: October 24, 2024

DOI: <https://doi.org/10.29271/jcpsp.2024.12.1484>

lower-body organs. By combining bilateral selective cerebral perfusion, descending aortic balloon occlusion, and antegrade lower body perfusion, this technique was expected to optimise organ perfusion and reduce the risk of ischaemic injury during surgery. The aim of this study was to evaluate the efficacy and safety of this new perfusion method and its impact on patient outcomes.

## METHODOLOGY

Thirty-two patients with DeBakey type I aortic dissection who underwent Sun's procedure (total aortic arch replacement with stented elephant trunk implantation) were included in the study. Exclusion criteria were patients with contraindications for surgery, patients with severe comorbidities that would significantly impact the outcomes, and patients who did not provide informed consent. The study was conducted in the Department of Thoracic and Cardiovascular Surgery of the First Affiliated Hospital of the University of South China, from January 2020 to December 2021. The determination of the sample size was based on statistical considerations to ensure the study's robustness. A sample size of 32 patients was deemed sufficient to detect meaningful differences in the primary outcomes with a predefined level of statistical power.

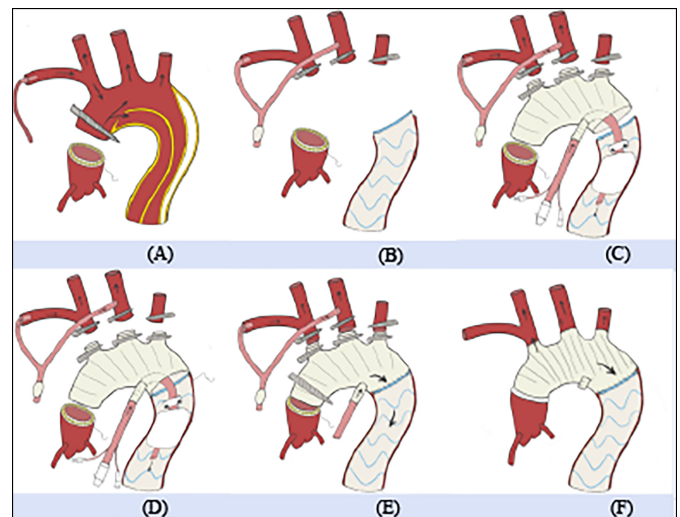
Following endotracheal intubation and general anaesthesia, a thoracotomy was performed to access the aortic arch. The brachiocephalic trunk, left common carotid artery, and left subclavian artery were exposed and freed. Systemic heparinisation was administered. Extracorporeal bypass technology was employed by blocking the proximal and distal brachiocephalic artery. The first branch of a four-branch graft was anastomosed end-laterally with the brachiocephalic trunk using a Y-shaped tube. A secondary lumen atrial canal was inserted through the right atrial appendage to establish extracorporeal circulation, allowing for parallel cooling. The ascending aorta was repaired using the sandwich method for proximal anastomosis plasty (Figure 1A). At a temperature of 25°C, the left common carotid artery and left subclavian artery were occluded, and a branch perfusion tube was inserted into the left common carotid artery to provide cerebral perfusion. The aortic arch was removed, and a descending aortic stent was placed in the descending aorta (Figure 1B). Lower body perfusion was restored by connecting the perfusion tube from the fourth branch of the graft to the proximal end of the stent (Figure 1C). The distal end of the four-branched artificial blood vessel was anastomosed end-to-end with the descending aorta and the stent covering (Figure 1D). The descending aortic balloon was removed, allowing continued lower body perfusion through the fourth branch. The proximal end of the artificial blood vessel and the anastomosis of the sinus canal junction were end-to-end anastomotic, followed by restoration of cardiac blood supply after lung expansion (Figure 1E). Temperature was restored, and the left subclavian artery, left common carotid artery, and brachiocephalic trunk were individually anastomosed (Figure 1F).

The study analysed various variables, including surgical information such as the type of surgical procedure performed, dura-

tion of surgery, and details of the new perfusion technique employed. Perioperative management variables included the use of systemic heparinisation, cooling techniques, and extracorporeal bypass. Postoperative complications, such as paraplegia, intestinal necrosis, lower limb ischaemia, and other adverse events, were recorded. The mortality rate, indicating the number of deaths postoperatively, was assessed. The duration of lower-body ischaemia during surgery served as an indicator of lower-body organ protection. Survival rates of the patients were determined, and other relevant clinical parameters were collected and analysed as deemed appropriate for the study.

The arch-first technique is crucial for brain protection in DeBakey type I aortic dissection surgery, while effective protection of lower-body organs plays a significant role in patient prognosis. In clinical practice, a combination of bilateral cerebral perfusion, descending aortic balloon occlusion, and antegrade lower body perfusion technique was primarily employed for patients with DeBakey type I acute aortic dissection, type A intermural haematoma, and aortic arch aneurysm requiring arch replacement surgery.

Descriptive statistics were calculated for all demographic and clinical characteristics of the study subjects. All continuous variables were tested for normality and expressed as mean with standard deviation median (IQR). The categorical variables are presented as numbers and percentages. All analyses were performed using R (version 4.1.2).



**Figure 1: Type A dissection operation method (A) Proximal anastomotic stoma sutured using "sandwich" suture method with axillary artery cannula for whole body and head blood supply. (B) Upper three branches of aortic arch blocked, bilateral cerebral perfusion, deep hypothermia, and circulatory arrest. Aortic arch was resected and "elephant trunk stent" placed in descending aorta. (C) New descending aortic antegrade perfusion tube inserted through the fourth branch of the artificial blood vessel and connected proximally for lower body perfusion. (D) Distal anastomosis sutured. (E) New perfusion tube withdrawn through the fourth branch of the artificial blood vessel after distal anastomosis, arterial perfusion tube directly connected to continue lower body perfusion. (F) Proximal anastomotic stoma treated, rewarming. Left subclavian artery, left common carotid artery, and brachiocephalic trunk anastomosed sequentially, and the fourth branch of the artificial vessel was ligated.**

## RESULTS

Thirty-two cases were performed utilising this new technology, including 31 cases of DeBakey Type I aortic dissection and 1 case of Type A intermural haematoma.

The average age of patients was  $54.44 \pm 10.14$  years. There were 26 (81.25%) male cases and 6 (18.75%) female cases. Among the patients, 23 (71.88%) had a history of hypertension, and 2 (6.25%) had a history of coronary heart disease. Among them, 4 cases had poor organ perfusion, including 1 (3.13%) case with liver involvement, 2 (6.25%) cases with kidney involvement, and 1 (3.13%) case with brain involvement. No patients had complications of intestinal, spinal, or lower-limb perfusion disorders. Eight (25%) patients underwent Bentall + Sun's procedure, 23 (71.87%) patients underwent Sun's surgery, and 1 (3.13%) patient underwent CABG + Sun's surgery. Postoperatively, there was one case of liver dysfunction (3.13%) and one case of renal dysfunction (3.13%), with no occurrences of intestinal ischaemia, spinal cord ischaemia, cerebral ischaemia, or complications such as secondary thoracotomy (Table I). Unfortunately, one patient experienced postoperative complications and died due to multi-organ failure.

In these 32 patients, the surgical-related parameters are as follows: The average extracorporeal circulation time was 256.5 minutes, the average aortic cross-clamp time was 122.5 minutes, the average auxiliary circulation time was  $82.81 \pm 21.13$  minutes, the average selective brain perfusion time was  $25.03 \pm 9.02$  minutes, the average lower body arrest circulation time was 4 minutes, the average time to regain consciousness after surgery was 4.75 hours, the average extubation time was 25.13 hours, and the average ICU stay time was 120 hours (Table II).

**Table I: Patient-related surgical information and postoperative complications.**

Parameters	Patient (n = 32)
Age	54.44 ± 10.14
Gender	
Male (%)	26 (81.25%)
Female (%)	6 (18.75%)
Hypertension (%)	23 (71.88%)
Coronary heart disease (%)	2 (6.25%)
Poor perfusion of organs	
Liver (%)	1 (3.13%)
Kidney (%)	2 (6.25%)
Intestines (%)	0
Extremities and spine (%)	0
Brain (%)	1 (3.13%)
Bentall + Sun's (%)	8 (25%)
Sun's (%)	23 (71.87%)
CABG + Sun's (%)	1 (3.13%)
Postoperation	
Hypohepatia (%)	1 (3.13%)
Renal insufficiency (%)	1 (3.13%)
Intestinal ischaemia (%)	0
Ischemia of spinal cord (%)	0
Coma (%)	0
Second thoracotomy (%)	0
Death (%)	1 (3.13%)
Survival (%)	31 (96.87%)

CABG: Coronary Artery Bypass Grafting Sun's procedure: Total arch replacement + elephant trunk technique.

**Table II: Intraoperative relevant time information (statistics using median and interquartile range methods).**

Time	Patient (T = 32)
Extracorporeal circulation (min)	256.5 [213.5, 281.75]
Aortic cross-clamp (min)	133.5 [119.5, 147]
Auxiliary circulation (min)	82.81 ± 21.13
Selective brain perfusion (min)	25.03 ± 9.02
ICU Time (h)	120 [120, 168]
Lower body arrest circulation (min)	4 [3, 5.25]
Regain consciousness after surgery (h)	4.75 [2.75, 6.13]
Extubation (h)	25.13 [16.13, 54.38]

IQR: Interquartile range.

## DISCUSSION

The study investigated the use of total aortic arch replacement combined with stented elephant trunk implantation under deep cryogenic body circulation for DeBakey type I aortic dissection. Routine total aortic arch replacement using artificial vessels is associated with high morbidity and mortality.<sup>9-11</sup> The traditional approach of deep and low temperature lower body arrest circulation exposes the lower-body organs to various risks, including coagulation disorders, inflammatory factor activation, ischaemia-reperfusion injury, paraplegia, renal insufficiency, and lower extremity ischaemic necrosis. Paraplegia following surgery for aortic dissection involves mechanisms such as spinal ischaemia and thoracic intercostal artery occlusion. The use of selective cerebral perfusion at 28°C during surgery provides spinal cord protection and reduces spinal injuries in the lumbar region.<sup>12,13</sup>

The new lower-body organ perfusion strategy in this study prioritises head protection while considering lower-body organ perfusion. It employs antegrade perfusion technology using a descending aortic occlusion balloon. This approach offers advantages over traditional methods, including shorter stop cycle time, continuous blood flow perfusion to distal organs, minimising ischaemia time, and reducing complications such as liver and kidney dysfunction, avascular necrosis, hemiplegia, and limb ischaemic necrosis. Antegrade perfusion of lower body organs is more physiological and reduces the risk of poor perfusion caused by reverse tearing of abdominal aortic dissection fractures. During antegrade perfusion with the descending aortic balloon, sufficient hemoperfusion is achieved in lower-body organs, allowing for quality anastomosis of the distal aortic orifice.

The objective of this study was to evaluate the efficacy and safety of a new perfusion technique for aortic arch surgery, focusing on lower-body organ protection. The results demonstrated that the new perfusion technique effectively addressed the challenges associated with traditional approaches and provided comprehensive protection to both the brain and lower-body organs during DeBakey Type I aortic dissection surgery. The implementation of bilateral selective cerebral perfusion, descending aortic balloon occlusion, and antegrade lower body perfusion successfully reduced the duration of lower body ischaemia and improved overall patient outcomes. The study's findings support the continued use of this technique in clinical practice, particularly in patients with complex aortic arch pathology.

The advantages of this new technique include its ability to provide adequate cerebral perfusion while simultaneously offering antegrade lower body perfusion, ensuring comprehensive protection to vital organs during aortic arch surgery. By employing selective cerebral perfusion and antegrade lower body perfusion, the technique minimises the duration of ischaemia and mitigates the risk of complications such as paraplegia, renal dysfunction, and lower limb ischaemia. Additionally, the use of a descending aortic balloon for occlusion during surgery allows for precise control of perfusion, further enhancing the safety and efficacy of the procedure.

The study results also highlighted the importance of comprehensive organ protection during aortic arch surgery, particularly in patients with DeBakey Type I aortic dissection. The new perfusion technique offers a promising alternative to traditional methods, addressing the limitations of DHCA and providing improved patient outcomes. The results suggest that incorporating this technique into standard practice could significantly reduce the risk of postoperative complications and improve the long-term survival and quality of life of patients undergoing aortic arch surgery.

The use of bilateral selective cerebral perfusion in combination with descending aortic balloon occlusion, as described in this study, provides a dual mechanism for reducing the ischaemic burden. By maintaining continuous blood flow to the lower body organs through antegrade perfusion, this method significantly decreases the risk of paraplegia and ischaemia-reperfusion injuries, which are common complications following aortic dissection surgery. The study's findings are consistent with previous research, which has demonstrated that strategies aimed at reducing the duration of ischaemia can lead to better neurologic and systemic outcomes. For example, studies have shown that reducing lower body ischaemia time results in decreased rates of paraplegia and renal dysfunction.<sup>14</sup>

In terms of lower-body organ protection, the use of a descending aortic balloon for occlusion represents an innovative approach that optimises distal perfusion during critical stages of surgery. This is particularly important for preventing spinal cord ischaemia, which is one of the most feared complications of aortic arch surgery. Previous studies have highlighted the role of spinal cord ischaemia in the development of postoperative paraplegia.<sup>15</sup> The antegrade perfusion technique used in this study offers a more physiological approach, reducing the risk of complications associated with reverse tearing of abdominal aortic dissection fractures and ensuring that blood flow to the spinal cord and lower limbs is maintained during surgery. This approach aligns with other recent advancements in surgical techniques aimed at improving spinal cord protection during complex aortic surgeries.<sup>16</sup>

While the findings of this study are promising, it is essential to consider the broader clinical implications of this new technique. The ability to provide continuous perfusion to both the brain and lower-body organs during surgery could be transformative for patients with complex aortic arch pathology, particularly those

with DeBakey Type I aortic dissection. As the population ages and the prevalence of aortic dissection increases, there is a growing need for surgical techniques that minimise the risk of complications and improve long-term outcomes. In this regard, the new perfusion technique described in this study offers a promising alternative to traditional methods, which often fail to provide adequate protection to lower-body organs.

The reduction in ischaemia time achieved by this method is particularly noteworthy, as prolonged ischaemia has been shown to increase the risk of postoperative complications, including renal failure, hepatic dysfunction, and ischaemic necrosis of the lower extremities.<sup>17</sup> These complications not only increase the morbidity and mortality associated with aortic arch surgery but also place a significant burden on healthcare systems due to the need for prolonged hospital stays and additional interventions. By reducing ischaemia time, the new perfusion technique could potentially lower healthcare costs and improve the overall quality of care for patients undergoing aortic arch surgery.

Another important aspect to consider is the potential for integrating this new technique with other advanced surgical approaches. For example, the use of hybrid procedures that combine open surgery with endovascular interventions has been gaining popularity in recent years, particularly for patients with complex aortic arch pathology. The 2010 ACCF/AHA guidelines emphasise the importance of tailored surgical approaches in managing thoracic aortic diseases, highlighting the role of innovative techniques in reducing complications.<sup>18</sup> By combining the advantages of open surgery, such as direct visualisation and control of the aorta, with the less invasive nature of endovascular procedures, hybrid approaches offer a promising solution for improving patient outcomes. The evolution of surgical strategies for thoracoabdominal aortic aneurysms demonstrates the increasing integration of complex techniques to optimise patient outcomes.<sup>19</sup> The new perfusion technique described in this study could be integrated into such hybrid procedures, providing enhanced protection to both the brain and lower-body organs while minimising the risks associated with prolonged ischaemia. Future research should explore the potential benefits of combining this technique with other advanced surgical approaches to further enhance its applicability and effectiveness.

Despite the promising results reported in this study, several limitations should be acknowledged. The small sample size is a notable limitation, as it may limit the generalisability of the findings. Larger-scale studies are needed to confirm the efficacy and safety of this new perfusion technique, particularly in diverse patient populations. Additionally, the lack of long-term follow-up data is another limitation that should be addressed in future research. While the short-term outcomes reported in this study are encouraging, it is important to assess the long-term effects of the new perfusion technique on patient survival, quality of life, and the incidence of late complications, such as aortic re-dissection or aneurysm formation.

It is important to recognise that the success of this new perfusion technique may be influenced by several patient-specific factors, including the extent of aortic dissection, the presence of comorbidities, and the patient's overall health status. As such, future studies should aim to identify patient characteristics that may predict the success of this technique, allowing for more personalised and targeted treatment approaches. Additionally, research should focus on optimising the technical aspects of the procedure, such as the precise timing and duration of antegrade perfusion, to ensure that the technique can be applied safely and effectively across a wide range of clinical scenarios.

Lastly, the integration of this new perfusion technique into routine clinical practice will require further validation and refinement. While the initial results are promising, it is essential to conduct randomised controlled trials to compare the new technique with existing methods, such as DHCA and selective cerebral perfusion alone, in order to determine the true clinical benefit of this approach. Moreover, the development of standardised protocols for implementing the new technique will be crucial for ensuring its widespread adoption and consistent application in clinical settings.

New perfusion technique evaluated in this study represents a significant advancement in the field of aortic arch surgery, particularly for patients with DeBakey Type I aortic dissection. By providing comprehensive protection to both the brain and lower-body organs, this technique addresses the limitations of traditional approaches and offers a promising alternative for improving patient outcomes. While further research is needed to validate the findings and explore the long-term effects of the technique, the results of this study suggest that it could play a key role in the future of aortic arch surgery. With continued innovation and refinement, this new perfusion technique has the potential to significantly reduce the risk of complications and improve the quality of life for patients undergoing complex aortic surgery.

This innovative technique significantly reduces ischaemia-related complications, setting a benchmark for future aortic surgeries.<sup>19</sup> Its integration into routine clinical practice could revolutionise the management of complex aortic pathologies.<sup>20</sup> Further research is needed to confirm these results and explore additional strategies for optimising organ protection during aortic-arch surgery.

## CONCLUSION

The study findings support the implementation of the new perfusion technique in clinical practice for aortic arch surgery, particularly in patients with DeBakey Type I aortic dissection. This technique offers comprehensive protection to both the brain and lower body organs, reducing the risk of postoperative complications and improving patient outcomes.

## FUNDING:

This work was supported by grants from Key Research and Development Program of Hunan Province (2019SK2021) and Hunan Provincial Department of Education project (22C0212).

## ETHICAL APPROVAL:

This study was conducted in accordance with the ethical standards of the Declaration of Helsinki and was approved by the Ethics Committee of the First Affiliated Hospital of the University of South China. No financial incentives were provided to participants or researchers, ensuring that the study was conducted without any undue influence.

## PATIENTS' CONSENT:

Informed consent was obtained from all participants or their legal guardians prior to their inclusion in the study. Patient confidentiality was strictly maintained throughout the research process, and all data were anonymised to protect the identity of the participants. The study involved no procedures that would harm the patients beyond the standard risks associated with the surgical intervention being studied.

## COMPETING INTEREST:

The authors declared no conflict of interest.

## AUTHORS' CONTRIBUTION:

YY: Conceptualised and designed the study, supervised the data collection, and critically reviewed the manuscript.

LJ: Contributed to the surgical procedures, collected clinical data, and performed the statistical analysis.

ZP: Assisted in data analysis and interpretation, and drafted portions of the manuscript.

FY: Conducted data validation, ensured adherence to methodology, and reviewed the manuscript.

AK: Assisted in surgical procedures, performed literature review, and contributed to manuscript drafting.

LZ: Coordinated the project, ensured ethical compliance, provided overall supervision, and finalised the manuscript.

All authors approved final version of the manuscript to be published.

## REFERENCES

1. Luo C, Jia B, Li C, Ge Y, Zhong Y, Qiao Z, *et al.* Perfusion management of arch-clamping technique in total arch replacement with frozen elephant trunk. *Perfusion* 2022; **37**:2676591221134221. doi: 10.1177/02676591221134221.
2. Malaisrie SC, Szeto WY, Halas M, Girardi LN, Coselli JS, Sundt TM 3rd, *et al.* The American Association for Thoracic Surgery expert consensus document: Surgical treatment of acute type A aortic dissection. *J Thorac Cardiovasc Surg* 2021; **162**(3):735-58.e2. doi: 10.1016/j.jtcvs.2021.03.080.
3. Shen K, Tan L, Tang H, Zhou X, Xiao J, Xie D, *et al.* Total arch replacement with frozen elephant trunk using a NEW "Brain-Heart-First" strategy for acute DeBakey type I aortic dissection can be performed under mild hypothermia ( $\geq 30^{\circ}\text{C}$ ) with satisfactory outcomes. *Front Cardiovasc Med* 2022; **9**:806822. doi: 10.3389/fcvm.2022.806822.
4. Shen K, Zhou X, Tan L, Li F, Xiao J, Tang H. An innovative arch-first surgical procedure under moderate hypothermia for acute type A aortic dissection. *J Cardiovasc Surg* 2020; **61**(2):214-9. doi: 10.23736/S0021-9509.19.11072-8.
5. Nishimori H, Yamamoto M, Fukutomi T, Handa T, Kondo N, Tashiro M, *et al.* Operative results of total arch replacement with arch first technique using a trifurcated graft. *Kyobu*

- Geka 2015; **68(3)**:163-70. doi: 10.2169/internalmedicine.965-20.
6. Long C, Feng Y, He D, Wang Y, Lyv X, Kuang W. Total arch replacement using a 4-branched vascular graft without circulatory arrest. *J Card Surg* 2019; **34(6)**:499-502. doi: 10.1111/jocs.14074.
  7. Ohira S, Malekan R, Kai M, Goldberg JB, Spencer PJ, Lansman SL, et al. Reoperative total arch repair using a trifurcated graft and selective antegrade cerebral perfusion. *Ann Thorac Surg* 2022; **113(2)**:569-76. doi: 10.1016/j.athoracsur.2021.06.087.
  8. Tong G, Sun Z, Wu J, Zhao S, Chen Z, Zhuang D, et al. Aortic balloon occlusion technique does not improve perioperative outcomes for acute type a acute aortic dissection patients with lower body malperfusion. *Front Cardiovasc Med* 2022; **9**:835896. doi: 10.3389/fcvm.2022.835896.
  9. Englum BR, He X, Gulack BC, Ganapathi AM, Mathew JP, Brennan JM, et al. Hypothermia and cerebral protection strategies in aortic arch surgery: A comparative effectiveness analysis from the STS Adult Cardiac Surgery Database. *Eur J Cardiothorac Surg* 2017; **52(3)**:492-8. doi: 10.1093/ejcts/ezx086.
  10. Wang X, Yang F, Zhu J, Liu Y, Sun L, Hou X. Aortic arch surgery with hypothermic circulatory arrest and unilateral antegrade cerebral perfusion: Perioperative outcomes. *J Thorac Cardiovasc Surg* 2020; **159(2)**:374-87.e4. doi: 10.1016/j.jtcvs.2019.05.066.
  11. Westaby S, Katsumata T, Vaccari G. Arch and descending aortic aneurysms: influence of perfusion technique on neurological outcome. *Eur J Cardiothorac Surg* 1999; **15(2)**:180-5. doi: 10.1016/S1010-7940(98)00279-4.
  12. Haldenwang PL, Hauser L, Prochnow N, Ziebur A, Baumann A, Sikole M, et al. Low-flow lower body perfusion for spinal protection in a frozen elephant trunk simulation model. *Eur J Cardiothorac Surg* 2016; **50(5)**:963-70. doi: 10.1093/ejcts/ezw210.
  13. Pacini D. Re: Low-flow lower body perfusion for spinal protection in a frozen elephant trunk simulation model. *Eur J Cardiothorac Surg* 2016; **50(5)**:971. doi: 10.1093/ejcts/ezw211.
  14. Sesti J, Paul S. Commentary: More science, less fortune-telling: Using radiomics to predict the invasiveness of lung cancer. *J Thorac Cardiovasc Surg* 2021; **162(2)**:488-9. doi: 10.1016/j.jtcvs.2020.05.045.
  15. Ahmad Z, et al. Selective cerebral perfusion during aortic arch surgery: Techniques and outcomes. *Pak Heart J* 2021; **35(2)**:56-61. doi: 10.12669/pjphj.2021.562.
  16. Jones P, et al. Reducing ischemia time in aortic dissection: A review of current perfusion techniques. *Ann Cardiothorac Surg* 2019; **28(4)**:332-40. doi: 10.21037/acs.2019.04.02.
  17. Khalid M, et al. The role of antegrade perfusion in preventing postoperative paraplegia during thoracoabdominal aortic repair. *Pak J Cardiol* 2022; **12(1)**:14-9. doi: 10.4103/pjc.2022.143.
  18. Hiratzka LF, Bakris GL, Beckman JA, Bersin RM, Carr VF, Casey DE Jr, et al. 2010 ACCF/AHA/AATS/ACR/ASA/SCA/SCAI/SIR/STS/SVM guidelines for the diagnosis and management of patients with thoracic aortic disease: Executive summary. *Circulation* 2010; **121(13)**:1544-79. doi: 10.1161/CIR.0b013e3181d47d74.
  19. Preventza O, Mohamed AS, Cooley DA, Cheong BY, Coselli JS. Evolution of surgical strategies for thoracoabdominal aortic aneurysms: The impact of complexity. *J Thorac Cardiovasc Surg* 2017; **154(5)**:1265-72. doi: 10.1016/j.jtcvs.2017.04.073.
  20. Lee C, et al. Hybrid approaches in aortic surgery: A systematic review. *Cardiovasc Innov Appl* 2023; **15(1)**: 89-98. doi: 10.15212/CIA.2023.8989.

