

Retropharyngeal Abscess Presenting as Torticollis

Gozde Orhan Kubat and Aysegul Sule Altindal

Department of Otolaryngology, Alanya Alaaddin Keykubat University School of Medicine, Alanya, Antalya, Turkey

ABSTRACT

Retropharyngeal abscess (RPA) is a deep neck infection with life-threatening complications such as airway obliteration, necrotizing mediastinitis, and pulmonary empyema, which must be diagnosed early and treated promptly. We herein present a patient who was admitted to the emergency room with limited neck movement, torticollis, difficulty in swallowing, and a feeling that something is stuck in the throat and diagnosed with RPA. Plain lateral radiograph of the neck revealed air levels at the level of C3-C5. Computed tomography (CT) scan confirmed the diagnosis of RPA. After emergency surgery, clinical condition normalised in a short time, and at a 2-week postoperative follow-up, the retropharyngeal area was completely normal on endoscopic examination. It is important to recognise and treat RPA, which has a high mortality due to its complications. RPA should be kept in mind in the differential diagnosis of patients with neck pain and torticollis, particularly in adults.

Key Words: Retropharyngeal abscess, Drainage, Trendelenburg position, Torticollis.

How to cite this article: Kubat GO, Altindal AS. Retropharyngeal Abscess Presenting as Torticollis. *J Coll Physicians Surg Pak* 2022; **32(JCPSPCR)**:CR157-CR159.

INTRODUCTION

The retropharyngeal area is one of the areas where deep neck infection occurs. Deep neck cavities consist of loose connective tissue between superficial, middle, and deep fascia.¹ The retropharyngeal area is located posterior to the pharynx. It extends from the base of the skull superiorly to the mediastinum inferiorly.² It is a risky area for the spread of infections. Infection of the retropharyngeal area is rare and may lead to the formation of retropharyngeal abscess (RPA). RPA has high mortality as it can cause airway obstruction and extend to the "dangerous area".³ It often develops secondary to childhood infections.⁴ Development of RPA in adults without a history of trauma or concomitant disease is extremely rare.⁵ There is no classic grouping for RPA. It can be classified according to the aetiology into 3 types: (1) Upper respiratory infections, (2) Trauma/foreign body and (3) Idiopathic. There are no definitive diagnostic criteria in medical history and physical examination in RPA diagnosis. Computed tomography (CT) and magnetic resonance imaging (MRI) are the preferred imaging methods for diagnosing deep neck infections. The presence of fluid accumulation in the retropharyngeal area in contrast-enhanced CT is diagnostic.⁶ Treatment involves abscess drainage in the trendelenburg position under operating conditions along with wide-spectrum antibiotics by hospitalising the patient if abscess formation has occurred.³

In this case report, we present our diagnosis, treatment, and follow-up approach for a patient who developed RPA after taking a meal.

CASE REPORT

A 39-year woman felt that a piece of food was stuck in her throat during the meal. After a short period of time, she was admitted to the emergency room with complaints of restricted neck movements, neck pain increasing with neck movement, difficulty in swallowing, and sore throat. Lateral cervical plain x-ray taken in the emergency department revealed an area with air levels extending to C3-C5 (Figure 1).

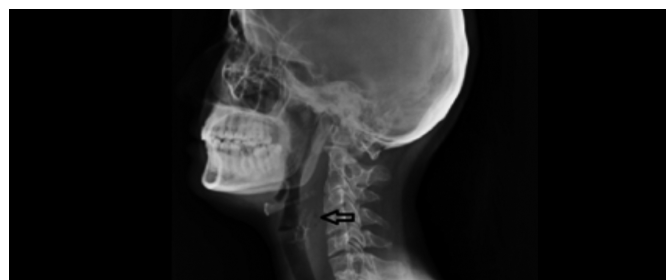

Figure 1: Prevertebral space widening in the lateral radiograph of the cervical spine with the laryngeal air column.

Upon this finding, an emergency contrast-enhanced CT of the neck was performed which showed an abscess measuring 12×33×10 mm in the retropharyngeal region (Figure 2).

The patient was hospitalised and broad-spectrum antibiotics were initiated. There was no fever during the physical examination of the patient in the emergency room. There was no pathology in the oral cavity. Endoscopic examination revealed a midline bulge that restricted the appearance of the vocal cord in the posterior pharyngeal wall. Laryngeal structures were normal. Her neck movement was restricted and she had a wry neck (torticollis).

Correspondence to: Dr. Gozde Orhan Kubat, Department of Otolaryngology, Alanya Alaaddin Keykubat University School of Medicine, Alanya, Antalya, Turkey
E-mail: gozde.orhan@alanya.edu.tr

Received: August 06, 2020; Revised: October 07, 2020;

Accepted: October 07, 2020

DOI: <https://doi.org/10.29271/jcpsp.2022.JCPSPCR.CR157>

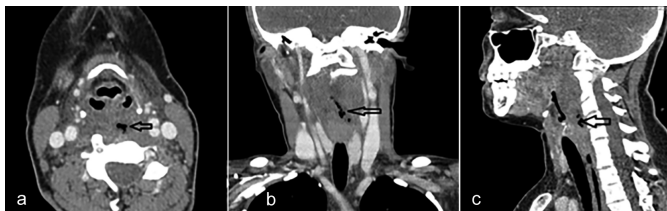


Figure 2: (a) Contrast-enhanced CT of the neck, 5 mm cross-sectional axial plane-oriented section. It shows a collection measuring 12×33×10 mm in the retropharyngeal area, compatible with abscess. (b) Coronal section. (c) Sagittal section.

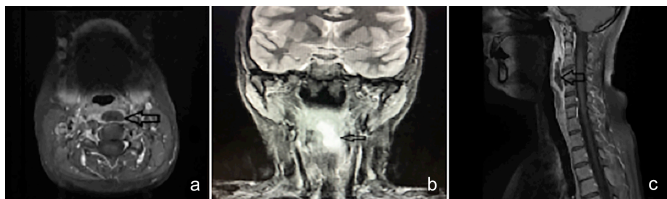


Figure 3: (a) Contrast-enhanced MRI of the neck, axial section, showing collection in the retropharyngeal area measuring 20×10×45 mm, with foci of signal loss compatible with air and peripheral opacification in post-contrast series. (b) Coronal section. (c) Sagittal section.

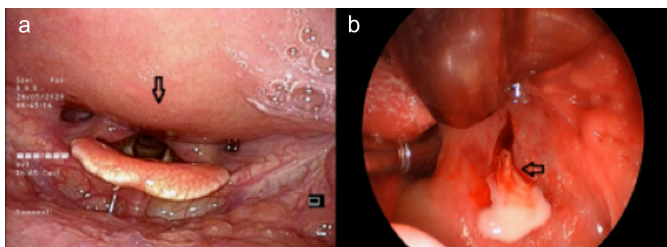


Figure 4: (a) Endoscopic view of the retropharyngeal abscess. (b) Endoscopic view of the drainage of the abscess during the operation.

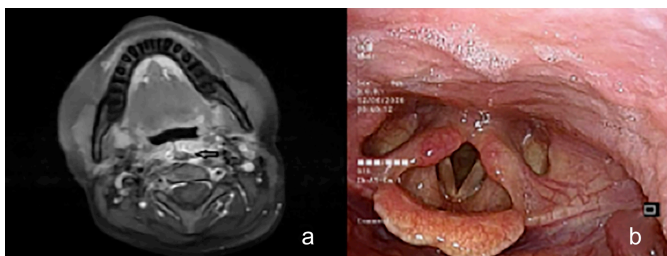


Figure 5: (a) Reduction in abscess size in follow-up MRI of the neck. (b) Normal appearance of the posterior wall in the follow-up endoscopy.

In the contrast-enhanced MRI, a collection with dimensions of 20×10×45 mm with foci of signal loss, compatible with air was observed (abscess?) (Figure 3). In the post-contrast series, this collection contained peripheral opacity. The patient was urgently taken to the operating room because of a spike of fever of 38.2°C during follow-up. Abscess drainage was performed in the trendelenburg position under general anaesthesia (Figure 4a and b).

Broad-spectrum antibiotics were continued following the drainage. On postoperative day 2, difficulty in swallowing was diminished, and neck movements returned to normal. In the follow-up neck MRI, the abscess size was reduced (Figure 5a). The patient was discharged in one week, and the endoscopic examination on the postoperative second month was normal (Figure 5b). There was no bulging, and the patient had no complaints.

DISCUSSION

RPA is a deep neck infection that can lead to fatal complications if a proper diagnosis is not made and early treatment is not given.⁷ There are lymph nodes in the retropharyngeal area. The lymphatics of the nasal cavity, paranasal sinuses, nasopharynx, oropharynx, hypopharynx, and larynx drain in this region. Untreated infections in this area lead to the suppuration of lymph nodes, edema and cellulitis. If left untreated, the infection proceeds to abscess formation.⁷ In our case, the infection occurred due to trauma caused by food particles and led to RPA.

RPA is mostly seen in childhood due to the upper respiratory tract infections spreading to the retropharyngeal lymph nodes.⁸ It is generally associated with trauma in adults.⁵ In our case report, an adult patient had a history of minor trauma, presumably caused by food particles.

Non-specific complaints such as sore throat, trismus, difficulty in swallowing, drooling, ear pain, torticollis and fever are encountered. In addition to RPA, similar complaints may occur in lymphadenitis, peritonsillar abscess, retropharyngeal oedema, retropharyngeal hematoma, Kawasaki disease, pyiform sinus cyst, calcific tendinitis of the longus colli muscles, lymphatic malformation, lymphoma, angioedema, and osteomyelitis.⁹

On physical examination, trismus and torticollis can be seen; however, abscess fluctuation is not observed on external palpation. If it can be palpated from the oral cavity, fluctuating swelling may be felt. In an endoscopic examination, bulging of the posterior pharyngeal wall may be observed. It is typical to induce pain by moving the larynx from left to right (rock maneuver).⁷

The diagnosis is based on clinical examination and imaging. In the plain lateral cervical x-ray, the measurement of the distance from the anterior surface of the C2 cervical vertebra to the posterior border of the trachea should be 7 mm or less, regardless of the patient's age. In the RPA, the expansion of soft tissues results in an increase in this distance.¹⁰

Although direct x-rays are easy and quick, they are not sufficient. CT or MRI should be evaluated according to the condition of the infection and the patient. Rapid CT results, short shooting time, and minimal interference caused by patient movements make tomography superior in emergency cases. The major advantage of MRI is that it shows soft tissues in more detail. Anatomical structures can be examined in detail on T1-weighted images, and pathological formations on T2-weighted images and contrast sections.²

In the diagnosis of RPA, contrast-enhanced CT scan will show abscess, and contrast-enhanced MRI the condition of the adjacent airway and vascular structures and the presence of epidural abscess.²

In treatment, wide-spectrum antibiotics and surgical drainage are recommended. Drainage should be performed in the trend-

lenburg position to prevent pus aspiration.³ The vast majority of cases can be drained transorally under general anaesthesia. An external approach may be required in cases with parapharyngeal drainage.⁷

Delays in the diagnosis and treatment of RPA can lead to the development of complications. When the abscess is left untreated, the abscess contents can result in aspiration if it spills into the pharynx. As a result, aspiration pneumonia may develop. Another infection-spreading route is direct transmission from facial planes to other neck areas or from the prevertebral area to the posterior mediastinum. Death may occur due to aspiration, airway obstruction, mediastinitis, and empyema or major vascular erosions.⁸ Epidural abscess, jugular vein thrombosis, carotid artery erosion, and pericarditis are other possible complications.³

In the presence of sore throat and difficulty in swallowing, torticollis or unexplained neck pain, RPA should be suspected and investigations should be done to prevent delay in diagnosis, which may lead to serious consequences. Delays in surgical interventions can cause RPA infections to spread to adjacent cavities in the cervical region, mediastinum, sepsis, and even death. Early diagnosis and treatment are crucial because of its high morbidity and mortality.

PATIENT'S CONSENT:

Informed consent was obtained from the patient.

COMPETING INTEREST:

The authors declared no competing interest.

AUTHORS' CONTRIBUTION:

GOK, ASA: Searched the literature and drafted the manuscript

GOK: Supervised the manuscript.

All the authors have approved the final version of the manuscript to be published.

REFERENCES

1. Maharaj S, Ahmed S, Pillay P. Deep neck space infections: A case series and review of the literature. *Clin Med Insights Ear Nose Throat* 2019; **12**:1179550619871274. <http://doi.org/10.1177/1179550619871274>.
2. Hurley MC, Heran MK. Imaging studies for head and neck infections. *Infect Dis Clin North Am* 2007; **21**(2): 305-53. <http://doi.org/10.1016/j.idc.2007.04.001>.
3. Kokten N, Çam O, Kılıçaslan A, Hanege F, Uzun L, Tekin M. Retropharyngeal abscess: Three unusual cases. *J Otolaryngol ENT Res* 2016; **5**(3):00144.
4. Philpott C, Langstaff L. Retropharyngeal abscess. *BMJ* 2018.
5. Tannebaum RD. Adult retropharyngeal abscess: a case report and review of the literature. *J Emerg Med* 1996; **14**(2):147-58. [http://doi.org/10.1016/0736-4679\(95\)02113-2](http://doi.org/10.1016/0736-4679(95)02113-2)
6. Hoang JK, Branstetter IV BF, Eastwood JD, Glastonbury CM. Multiplanar CT and MRI of collections in the retropharyngeal space: Is it an abscess? *AJR Am J Roentgenol* 2011; **196**(4):W426-W32. Doi:10.2214/AJR.10.5116.
7. Reilly BK, Reilly JS. Retropharyngeal abscess: Diagnosis and treatment update. *Infect Disord Drug Targets* 2012; **12**(4):291-6. Doi: 10.2174/187152612801319320.
8. Brook I. Microbiology and management of peritonsillar, retropharyngeal, and parapharyngeal abscesses. *J Oral Maxillofac Surg* 2004; **62**(12):1545-50. <http://doi.org/10.1016/j.joms.2003.12.043>.
9. Tomita H, Yamashiro T, Ikeda H, Fujikawa A, Kurihara Y, Nakajima Y. Fluid collection in the retropharyngeal space: A wide spectrum of various emergency diseases. *Eur J Radiol* 2016; **85**(7):1247-56. <http://doi.org/10.1016/j.ejrad.2016.04.001>.
10. Craig FW, Schunk JE. Retropharyngeal abscess in children: Clinical presentation, utility of imaging, and current management. *Pediatrics* 2003; **111**(6):1394-8. <http://doi.org/10.1542/peds.111.6.1394>.

.....