Is there a Correlation between Hepatic Venous Indices and Main Pulmonary Artery Diameter?

Taha Yasin Arslan, Erdogan Bulbul, Bahar Yanik, Gulen Demirpolat and Emrah Akay

Department of Radiology, School of Medicine, Balikesir University, Balikesir, Turkey

ABSTRACT

Objective: To search whether there is a correlation between middle hepatic venous indices (HVIs) obtained by pulsed waved doppler ultrasonography (PW-DUS) and the main pulmonary artery (mPA) diameter, calculated by computed tomography (CT).

Study Design: A descriptive cross-sectional study.

Place and Duration of Study: Department of Radiology, Balikesir University School of Medicine, Turkey, from February to December 2020.

Methodology: After excluding the cases with suspected COVID-19 from the cases sent to the Radiology Department for chest CT exams with the mPA included in the cross-sections, the volunteers were evaluated with PW-DUS. The study group consisted of 66 cases. Two radiologists measured the velocity values of the A, S, and D waves in the recorded PW Doppler spectra. HVIs (A/S, A/S+D, A/A+S+D) were calculated. The mPA diameter was calculated in the axial plane from the pulmonary trunk, 1cm proximally to the bifurcation manually on the workstation. The correlation between the HIVs and mPA diameter was evaluated. Interoperator reliability was also analysed.

Results: Thirty-nine males (59%) and 27 (41%) females were included in the study group. The mean HVI values were 0.50 ±0.20, 0.28 ±0.12, and 0.21 ±0.07 for A/S, A/A+S, and A/A+S+D, respectively. The mean mPA diameter was 24.0 ±3.3 mm. Correlation analysis determined that the HVIs were positively correlated with mPA diameter (r=0.730-0.765-0.751, p<0.001). Inter-observer correlation coefficients were found to be compatible between two radiologists.

Conclusion: A significant and strong correlation was found between HVIs and mPA diameter. The mPA diameter that reflects the pulmonary artery systolic pressure (PAP) increased as the HVIs increased. Therefore, PW-DUS may be helpful to evaluate PAP as a quantitative method that is cost-effective, easily accessible and radiation-free.

Key Words: *Hepatic veins, Pulmonary artery, Multidetector computed tomography, Pulmonary hypertension, Pulsed doppler ultrasonography.*

How to cite this article: Arslan TY, Bulbul E, Yanik B, Demirpolat G, Akay E. Is there a Correlation between Hepatic Venous Indices and Main Pulmonary Artery Diameter?. *J Coll Physicians Surg Pak* 2022; **32(12)**:1529-1533.

INTRODUCTION

The right heart pumps venous blood to the lungs, where oxygen and carbon dioxide exchange happens. Pulmonary circulation typically occurs in relatively lower pressure than systemic circulation. The normal pulmonary artery systolic pressure (PAP) usually is 14±3 mmHg in the right heart catheterisation.[1,2] When the mean PAP is higher than 25 mmHg, it is defined as pulmonary hypertension (PH). PH is related to functional disability and higher mortality.[1,2]

Correspondence to: Dr. Erdogan Bulbul, Department of Radiology, School of Medicıne, Balikesir Unıversity, Balikesir, Turkey
E-mail: drerdoganbulbul@yahoo.com

Received: June 02, 2022; Revised: September 15, 2022; Accepted: October 25, 2022
DOI: https://doi.org/10.29271/jcpsp.2022.12.1529

Although the right heart catheterisation is the gold standard in PH diagnosis, it is invasive.[2] On the other hand, it may be helpful in PH diagnosis by detecting morphological and physiological changes with radiologic methods like computed tomography (CT), hepatic venous Doppler ultrasonography (DUS) and echocardiography.[3-6] The main pulmonary artery (mPA) diameter increase in patients with PH can be demonstrated with CT.[2,7] In DUS, the hepatic venous flow is triphasic and has four components. The A, S, V, and D waves correspond to atrial contraction, ventricular systole, atrial filling and opening of the tricuspid valve during the cardiac cycle, respectively (Figure 1A).[8,9] The hepatic venous flow velocity is related to the right atrium and PAP.[5,6] However, operator-dependent technical parameters may affect the pulsed waved hepatic venous doppler ultrasonography (PW-DUS) outcomes, such as wave velocity. Therefore, hepatic venous indices (HVIs) calculated from the wave velocities [A / S, A / (A+S)] are used in PW-DUS spectrum analysis to minimise operator-dependent angular factors.[5,10]

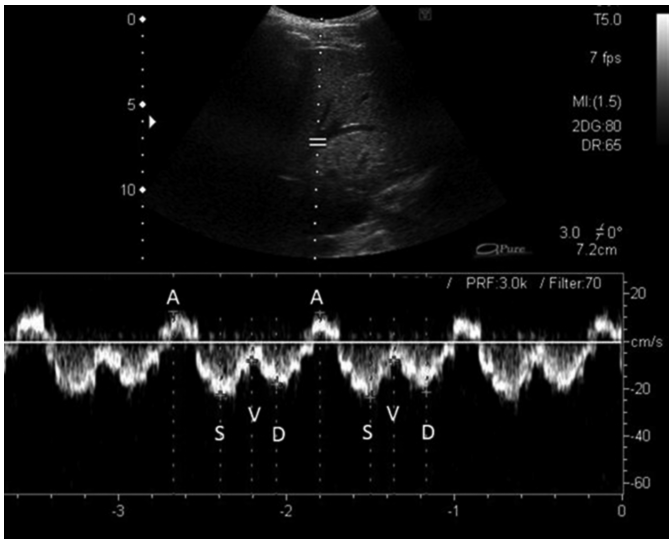

Figure 1 A: The hepatic venous waves are stated on the PW-DUS spectra.

To the best of the authors' knowledge, there are studies published about mPA diameter reflecting PAP and increased HVIs in patients with PH individually.[3,4,7,8,11] However, no study was found in the literature showing the relationship between mPA diameter and HVI. This study aims to search for whether there is a correlation between the mPA diameter and HVIs. It was hypothesised that HVIs could provide information about mPA diameter reflecting PAP.

METHODOLOGY

This descriptive cross-sectional study was performed in the Department of Radiology, Balıkesir University School of Medicine, Turkey. The study was carried out following the Helsinki Declaration, approved by the local ethics committee (No. 73023407/050.99/3043), and all study participants signed informed consent. The study was completed between February to December 2020, during the *COVID*-19 pandemic.

The study included 352 cases aged between 18 to 49 years, of both genders, without referral diagnosis of PH or pulmonary thromboembolism. These cases underwent CT scans such as contrast-enhanced thorax CT, high-resolution CT of lungs, and coronary CT angiography, which all comprised PA in the field of view. Two hundred sixty cases referred for the diagnosis of COVID-19 pneumonia were excluded. PW-DUS examination was performed on the remaining 92 volunteers after the CT scan. Cases with hepatosteatosis (n=18), pericardial effusion (n=4), cirrhosis (n=1) and non-cooperation (n=3) were excluded after PW-DUS examination; and 66 cases were included in the study.

The height and weight of cases were calculated with calibrated devices for calculating body mass index (BMI). CT imaging was performed by a 64-slice CT scanner (Toshiba Aquillon-64, Otawara, Japan). Scanning parameters were variable depending on the type of imaging protocol (contrast-enhanced thorax CT, high-resolution CT, coronary CT angiography); slice thickness: 0.5-1mm, pitch value: 1, FOV: 215-360 mm, 120 kV and 320-400 mA. The PA diameter was calculated in the axial plane from the mPA, 1cm proximally to the bifurcation manually on the workstation (Aquarius INtuition Viewer version 4.4.7; TeraRecon, San Mateo, CA, the USA, Figure 1B). The measurements were made with standard window settings for mediastinum (W=350, L=50). The PA diameter measurements were performed three times by an experienced resident and a 20-year experienced specialist individually. The averages of the three measurements were taken for each radiologist, and consistency between them was examined.

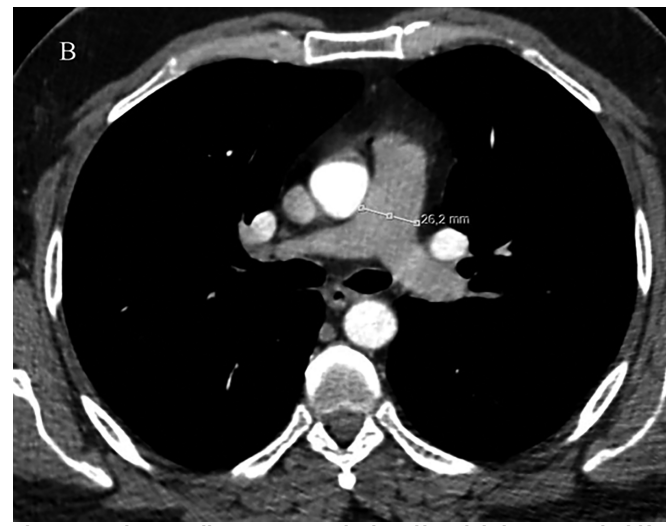

Figure 1 B: The mPA diameter was calculated in axial plane CT at the bifurcation level.

Hepatic venous PW-DUS was performed on an empty stomach immediately after CT. The radiology resident performed it in a comfortable environment, supine position, and at the end of regular inspiration. Gray scale and PW-DUS were performed using a US scanner (Aplio M-X SSA-780A, Toshiba, Tokyo, Japan) equipped with a broadband (1.6-6MHz) convex array transducer. Spectral analysis was obtained by performing a PW-DUS examination of the middle hepatic vein 3-6 cm away from the trifurcation. The images of the spectral examination were recorded in the PACS. The radiologists who calculated mPA diameters also measured the velocity values of the A, S, and D waves on the recorded spectral analysis images. They were unaware of CT findings. A/S, A/S+D, and A/A+S+D indices defined in previous studies were calculated.[4,5] The averages of the three measurements were taken for each radiologist, and consistency between them was examined. The HVIs were calculated with these averages.

Statistical analyses were performed using SPSS version 22 software (IBM SPSS Statistics, USA). The conformity of the variables to the normal distribution was examined using visual (histogram and probability graphs) and analytical methods (Kolmogorov-Smirnov/Shapiro-Wilk tests). Correlation coefficients and statistical significance were calculated with Spearman's test for the relationships between variables, at least one of which was not normally distributed. Descriptive analyses were evaluated using the mean and standard deviations for normally distributed variables. Bi-level independent and dependent variables were compared using Student's t-test and Mann-Whitney

U tests. In the presence of significant breakpoints, these limits' sensitivity, specificity and positive predictive values were calculated. Inter-observer agreement (inter-rater, inter-observer) was evaluated by Interclass Correlation Coefficient (ICC) analysis. Differences were considered statistically significant at $p<0.05$.

RESULTS

The study group comprised 66 cases, including 39 (59%) males and 27 (41%) females. The mean age was 36.2 (± 9). Demographic statistics, mPA diameter and HVIs, are given in Table I.

Table I: Demographic statistics, mPA diameter and HVIs are shown.

	Male	Female	All cases
Age	36.6 (±9.1)	35.8 (±9.2)	36.3 (±9.2)
Height (mm)	177 (±6)	160 (±7)	170 (±10)
Weight (kg)	83.7 (±15.1)	70.5 (±13.5)	78.3 (±15.8)
BMI	26.84 (±4.9)	27.7(±5.7)	27.2 (±5.2)
mPA diameter (mm)	24.6 (±3.2)	23.0 (±3.3)	24.0 (±3.3)
A/S	0.53 (±0.23)	0.46 (±0.16)	0.50 (±0.20)
A/A+S	0.30 (±0.14)	0.26 (±0.09)	0.28 (±0.12)
A/A+S+D	0.22 (±0.08)	0.20 (±0.08)	0.21 (±0.07)

In the measurements made by two radiologists, the intraclass correlation (ICC) coefficients were calculated as 0.98 for the mPA diameter, 0.97 for the A wave, 0.95 for the S wave, and 0.92 for the D wave. Intraobserver correlation coefficients were found to be compatible among researchers.

Excellent (r=0.751 and 0.765) and significant ($p<0.001$) positive correlation was found between mPA diameter and two of the HVIs (A/A+S+D and A/S+D). A very good (r=0.730) and significant ($p<0.001$) positive correlation was found between mPA diameter and A/S. A low degree (r= 0.292 and 0.313) and significant ($p<0.05$) positive correlation was found between BMI and HVIs (A/A+S+D and A/S, Table II, Figure 2).

Table II: Correlations between mPA diameter and BMI with HVIs.

		A/S	A/S+D	A/A+S+D
mPA diameter	Pearson Correlation	0.730**	0.765**	0.751**
	Sig. (2-tailed)	0.000	0.000	0.000
	N	66	66	66
BMI	Pearson Correlation	0.293*	0.313*	0.292*
	Sig. (2-tailed)	0.010	0.017	0.10
	N	66	66	66

** Correlation is significant at the 0.05 level (2-tailed); ** Correlation is significant at the 0.01 level (2-tailed).*

Significant differences were observed between height and gender ($p<0.001$), weight and gender ($p<0.001$), and mPA diameter and gender ($p<0.05$). A low (r=0.386) positive correlation was found between the height and weight data of the subjects (p<0, 01). A low (r=0.347) positive correlation was found between weight and mPA diameter (p<0, 01). No significant difference was observed between HVIs and genders ($p>0.05$).

The mPA diameter was ≥29 mm in 6 cases, and the A/S+D index was ≥0.30 in 5 of them. In 1 case A/S+D index was <0.30, although the mPA diameter was ≥29 mm. The mPA diameter was <29 mm in 60 cases. In this group A/S+D index was <0.30 in 56 cases; however A/S+D index was ≥0.30 in 4 of them.

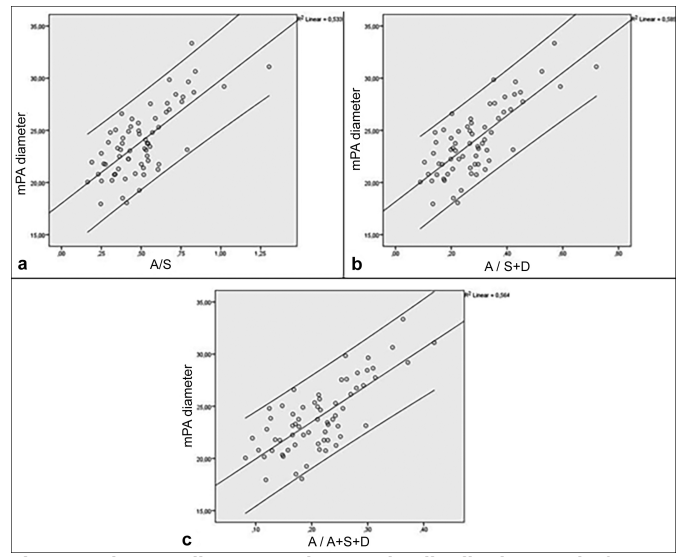

Figure 2: The mPA diameter and HVIs point distribution graphs (a. mPA diameter and A/S + D, b. mPA diameter and A/S + D, c. mPA diameter and A /A+S+D).

DISCUSSION

A positive correlation between HVIs and mPA diameter was revealed in this study, although mPA diameter was within normal values. HVIs values increased as the diameter increased. To the best of authors' knowledge, no study is investigating the relationship between mPA diameter and HVIs in the literature.

There are various studies examining hepatic venous flow (HVF) with PW-DUS.[8-10,12] While some of these studies evaluated the characteristics of HVF in the healthy population, changes in flow in various pathologies were investigated in others.[8] In healthy individuals, HVF is considered triphasic.[8,13] The A wave reflects the retrograde flow to the inferior vena cava and hepatic veins caused by atrial contraction, and the velocity value peaks at the end of atrial systole.[8,9] In PW-DUS, the A wave is above the spectral baseline. The S wave shows the flow from the vena cava and hepatic veins towards the heart with the effect of negative pressure during the systole of the ventricles. The D wave also reflects antegrade flow from the vena cava to the atrium in cardiac diastole. Both S and D waves lie below the baseline in spectral analysis. The V wave occurs when the tricuspid valve returns to its original position after systole, it may be above or below the baseline.[8,9] Therefore, the V wave is not considered when defining the HVF current as triphasic. However, some authors state that HVF is not always triphasic in healthy individuals.[13] Additionally, there may be other factors that can affect HVF.[8,13] For example, deep inspiration may cause changes in the velocities and phasities of the HVF.[13-15] In this study, HVF was triphasic in all cases when conditions such as hepatosteatosis that could affect HVF were excluded, and cases with adequate breathlessness were excluded. Since the V wave is variable, it cannot be considered in the calculation of the indices.

Pathologies that increase the right heart pressure and force the flow from the right heart cause resistance in the central

veins.[12,15] This resistance causes a compulsion inflow of the inferior vena cava and hepatic veins.[5,12] This situation creates an increase in the retrograde current that generates the A wave and a decrease in the antegrade current that creates the S and D waves. All these changes occur with an increase in HVI.[4,5] Studies have reported that HVIs are higher in patients with PH. In these studies, HVIs were higher in the group with high PAP after right heart catheterisation compared to the normal group.[4,5] In a study published by Sun *et al.,* they stated a significant positive correlation between the A/S+D and A/S ratios from the A-R indices and the mean PAP. When the value of 0.30 for the A/S+D ratio was accepted for a threshold, it was reported that the sensitivity was calculated as 85.37% and the specificity as 75.00% in detecting PH.5 A cut-off value was not calculated in this study because only 9 cases had ≥0.30 A/S+D index value; the study population had no complaint about PH, and right heart catheterisation was not performed.[5] In the previous studies, the group with normal PAP was not evaluated within itself, and the relationship between normal PAP values and HVIs was not evaluated. Although the authors did not perform central venous catheterisation or echocardiography, the study showed a strong correlation between mPA diameter increment and HIVs increment in the group with normal mPA diameter.

The mPA diameter increases with increasing mean PAP in PH, and there is a strong correlation between the mean PAP and the mPA diameter measured on CT.[6,7,11,16-18] In the same studies, they reported that when a mean mPA diameter ≥29 mm, the sensitivity is high in the diagnosis of PH. However, the mean mPA diameter <29 mm does not definitively exclude PH. Slightly increased mean PAP may also be <29 mm and overlap with normal cases.[17,19] In this study, there were 4 cases with an A/S+D index above 0.30, although the mPA diameter was <29 mm. Nevertheless, right heart catheterisation was not performed and specified the PAP in them.

The relationship between HVIs and mPA diameter was investigated, assuming that mPA diameter reflects mean PAP. There may be other factors that can affect mPA diameter other than PAP. Gender, age, and BMI were also investigated in relation to the mPA diameter in the literature.[20,21] Some studies have reported a significant correlation between mPA diameter with increasing age and BMI.[21] However, this study showed only a moderate positive correlation between age and mPA diameter. The mean mPA diameter was <29 mm, which was considered normal in most of the cases.

There are some limitations of the study. The number of cases is limited. Further studies with a larger group of participants are required for more reliable results. Catheterisation, which is the gold standard for PAP measurement, could not be performed. Therefore, PAP values were not compared with the HVIs obtained in Doppler US. Instead, the mPA diameter, which strongly correlates with PAP in the literature, was used for comparison. The probable pulmonary valve pathologies were excluded with CT findings; however, evaluating the pulmonary valve with echocardiography is better.

CONCLUSION

The clinical diagnosis of PH may be difficult due to the no specificity of its symptoms and signs. This study found a significant and robust correlation between HIVs and mPA diameter. The mean PAP measurement with right heart catheterisation is the gold standard in diagnosing PH. It is an invasive method and may cause mortality and morbidity. Some radiological examinations that help in diagnosis make the patient to be exposed to radiation. HVIs obtained from hepatic venous waveforms by PW-DUS can be used as a diagnostic aid in PH. The evaluation of HVIs with PW-DUS during routine examinations may show the changes in mPA diameter and contribute to the early detection of PAP increase. In order to evaluate the subject accurately and effectively, studies with a larger population should be conducted.

ETHICAL APPROVAL:

The study was carried out following the Helsinki Declaration, approved by the local ethics committee (No. 73023407/050.99/3043).

PATIENTS' CONSENT:

All study participants signed informed consent forms.

COMPETING INTEREST:

There are no financial or other interests in the subject matter of this original article.

DISCLOSURE:

This study was presented at the 42nd Turkish National Radiology Congress as an oral presentation.

AUTHORS' CONTRIBUTION:

TYA: The acquisition, analysis, and interpretation of data for the work. Performed the statistical analysis.

EB: The acquisition, analysis, and interpretation of data for the work.

BY, GD, EA: Revising it critically for important intellectual content.

All the authors have approved the final version of the manuscript to be published.

REFERENCES

1. Cardiovascular Disability: Updating the social security listings. Institute of medicine (US) committee on social security cardiovascular disability criteria. Washington (DC): *National Academies Press* (US) 2010; doi: 10.17226/12940.
2. Galiè N, Humbert M, Vachiery JL, Gibbs S, Lang I, Torbicki A, *et al.* 2015 "ESC/ERS guidelines for the diagnosis and treatment of pulmonary hypertension: The joint task force for the diagnosis and treatment of pulmonary hypertension of the European society of cardiology (ESC) and the European respiratory society (ERS) endors. *Eur Respir J* 2015; **46**:903-75. doi: 10.1093/eurheartj/ehv317.
3. Aluja Jaramillo F, Gutierrez FR, Díaz Telli FG, Yevenes Aravena S, Javidan-Nejad C, Bhalla S. Approach to pulmonary hypertension: From CT to clinical diagnosis. *Radiographics* 2018; **38(2)**:357-73. doi: 10.1148/rg.2018170046.

4. Hoque MH, Zaman SMM, Ahmed K, Banerjee SK, Kabir MFI, Fatema N. Hepatic venous Duplex as an alternative non-invasive diagnostic tool for diagnosis of pulmonary hypertension. *Univ Hear J* 2020; **16(2)**:86-91.doi: 10.3329/uhj.v16i2.49665.
5. Sun DD, Hou CJ, Yuan LJ, Duan YY, Hou Y, Zhou FP. Hemodynamic changes of the middle hepatic vein in patients with pulmonary hypertension using echocardiography. *PLoS One* 2015; **10(3)**:e0121408. doi: 10.1371/journal.pone.0121408.
6. Augustine DX, Coates-Bradshaw LD, Willis J, Harkness A, Ring L, Grapsa J, *et al*. Echocardiographic assessment of pulmonary hypertension: A guideline protocol from the British society of echocardiography. *Echo Res Pract* 2018; **5(3)**:G11-24. doi: 10.1530/ERP-17-0071.
7. Corson N, Armato III SG, Labby ZE, Straus C, Starkey A, Gomberg-Maitland M. CT-based pulmonary artery measurements for the assessment of pulmonary hypertension. *Acad Radiol* 2014; **21(4)**:523-30. doi:10.1016/j.acra.2013.12.015.
8. Scheinfeld MH, Bilali A, Koenigsberg M. Understanding the spectral Doppler waveform of the hepatic veins in health and disease. *Radiographics* 2009; **29(7)**:2081-98. doi: 10.1148/rg.297095715.
9. Andrade GS, Mónica AMM. Spectral Doppler waveform of the hepatic veins: everything You need to know. *Congress: ECR* 2019 Poster Number: C-3578. doi:10.26044/ecr2019/C-3578.
10. Kim MY, Baik SK, Park DH, Lim DW, Kim JW, Kim HS, *et al*. Damping index of Doppler hepatic vein waveform to assess the severity of portal hypertension and response to propranolol in liver cirrhosis: A prospective nonrandomised study. *Liver Int* 2007; **27(8)**:1103-10. doi: 0.1111/j.1478-3231.2007.01526.x.
11. Huitema MP, Spee M, Vorselaars VMM, Boerman S, Snijder RJ, van Es HW, *et al*. Pulmonary artery diameter to predict pulmonary hypertension in pulmonary sarcoidosis. *Eur Respir J* 2016; **47(2)**:673-6. doi: 10.1183/13993003.01319-2015.
12. Fadel BM , Husain A, Alassoussi N, Ziad Dahdouh Z , Mohty D. Spectral doppler of the hepatic veins in pulmonary hypertension. *Echocardiography* 2015; **32(1)**:170-3. doi: 10.1111/echo.12710.
13. Golbası Z, Caglı K. How to evaluate hepatic vein flows by transthoracic echocardiography? *Arch Turkish Soc Cardiol* 2017; **45(8)**:763-7. doi: 10.5543/tkda.2017.78070.
14. Rafique MS, Kundi S, Ziauddin A, Malik T, Maqsood A, Khan K. Do respiratory maneuvers affect the hepatic vein waveforms and maximum velocity? *P J M H S* 2022; **16**: 3:20-22 doi: 10.53350/pjmhs2216320.
15. Mittal SR. Doppler evaluation of hepatic vein flow. *J Indian Acad Echocardiogr Cardiovasc Imaging* 2018; **2(1)**:53-66. doi: 10.4103/jiae.jiae_80_17.
16. Peña E, Dennie C, Veinot J, Muñiz SH. Pulmonary hypertension: How the radiologist can help? *RadioGraphics* 2012; **32(1)**:9–32. doi: 10.1148/rg.321105232.
17. Goerne H, Batra K, Rajiah P. Imaging of pulmonary hypertension: An update. *Cardiovasc Diagn Ther* 2018; **8(3)**:279-96. doi: 10.21037/cdt.2018.01.10.
18. Lange TJ, Dornia C, Stiefel J, Stroszczynski C, Arzt M, Pfeifer M, *et al*. Increased pulmonary artery diameter on chest computed tomography can predict borderline pulmonary hypertension. *Pulm Circ* 2013; **3(2)**:363-8. doi: 10.4103/2045-8932.113175.
19. Frost A, Badesch D, Gibbs JSR, Gopalan D, Khanna D, Manes A, *et al*. Diagnosis of pulmonary hypertension. *Eur Respir J* 2019; **53(1)**:1801904. doi.org/10.1183/13993003.01904-2018.
20. Meeuwsen S, Horgan GW, Elia M. The relationship between BMI and percent body fat, measured by bioelectrical impedance, in a large adult sample is curvilinear and influenced by age and sex. *Clin Nutr* 2010; **29(5)**:560-6. doi: 10.1016/j.clnu.2009.12.011.
21. Ranasinghe C, Gamage P, Katulanda P, Andraweera N, Thilakarathne S, Tharanga P. "Relationship between body mass index (BMI) and body fat percentage, estimated by bioelectrical impedance, in a group of Sri Lankan adults: A cross sectional study". *BMC Public Health* 2013; **13**:797. doi: 10.1186/1471-2458-13-797.