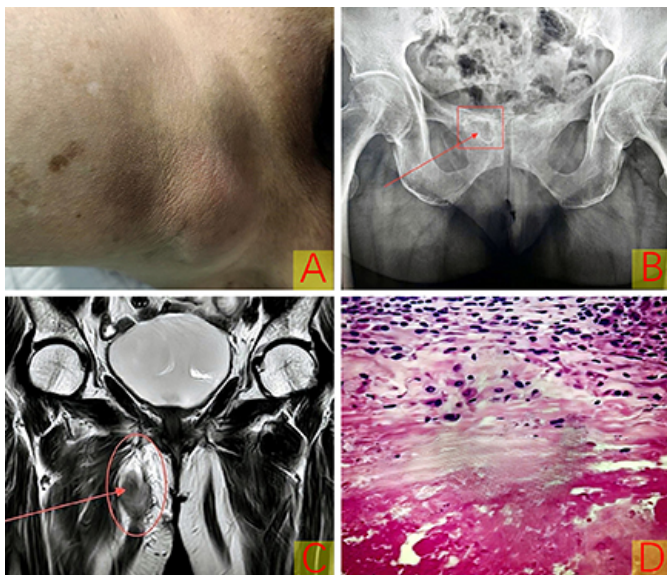


# Tuberculosis of the Right Pubic Bone Complicated by Abscess of the Right Thin Femoral Muscle

Sir,

Tuberculosis (TB) of the pubic symphysis is a rare manifestation of TB, characterised by the infection occurring in the pubic symphysis, a joint situated at the front of the pelvis where the two pubic bones meet. While TB continues to be a significant global public health concern, osteoarticular TB is relatively less common, accounting for only 2-5%<sup>1,2</sup> of all TB cases and 11-15% of extrapulmonary TB cases. Vertebral TB is the dominant form, representing around half of all cases.<sup>3,4</sup> This underscores the rarity of TB localisation in the pubic area.

A 69-year woman presented with a history of right-sided lower abdominal pain that commenced six months prior and progressively intensified, leading to discomfort during walking, sitting, and standing. Over the last month, the pain worsened and was accompanied by low-grade fever and malaise.



**Figure 1:** (A) Protruding mass observed in the right medial thigh, accompanied by tenderness in the right pubic bone region and the medial thigh. (B) Orthopaedic x-ray of the pelvis revealed uneven density in the right pubic bone. (C) MRI imaging indicated a peripheral mass with exudation in the right gracilis muscle and abnormal signal in the right pubic bone, raising suspicion of tuberculosis infection based on the patient's medical history. (D) Pathological analysis showed chronic granulomatous inflammation with evident caseous necrosis, supporting the diagnosis of tuberculosis.

Physical examination revealed a protruding mass in the right medial thigh with evident tenderness in the region of the right pubic bone and the medial thigh (Figure 1A). An x-ray of the

pelvis in orthopaedic position displayed irregular density in the right pubic bone (Figure 1B). MRI imaging exhibited a peripheral mass and oozing in the thin femoral muscle on the right side and abnormal signal in the right pubic bone, raising suspicion of TB infection in light of the patient's medical history (Figure 1C).

After admission, an examination of the right pubic bone and right medial thigh was conducted, and the lesion was resected under general anaesthesia. Intraoperatively, bone destruction of the right pubic bone and the presence of an abscess in the thin femoral and medial thigh muscle space were observed. Necrotic tissue and synovial proliferation were removed using a condenser knife, with the necrotic pubic bone was excised using biting forceps. The pathological examination revealed chronic granulomatous inflammation with evident caseous necrosis, suggestive of TB (Figure 1D). Furthermore, a mycobacterium TB DNA test yielded a positive result for TB-DNA.

Cases of TB affecting the pubic bone are uncommon, and the combination of pubic bone destruction and muscle abscesses indicates a rapid progression of the disease or ineffective treatment with antituberculous medications. In such instances, active surgical intervention is necessary to excise the necrotic bone and abscess, thoroughly irrigate the lesion with iodophor and hydrogen peroxide solutions, and administer local antituberculous medications to further sterilise the area. Following the surgery, the selection of appropriate antituberculous medications based on the results of drug sensitivity testing is crucial for continued oral treatment, in order to achieve optimal therapeutic outcomes.

## COMPETING INTEREST:

The authors declared no conflict of interest.

## AUTHORS' CONTRIBUTION:

BL: Drafted, revised, and edited the manuscript.

WX: Conducted the questionnaire survey, collected and analysed data, and interpreted the results.

GM: Conducted the questionnaire survey and collected data. All authors approved the final version of the manuscript to be published.

## REFERENCES

1. Ellis ME, el-Ramahi KM, Al-Dalaan AN. Tuberculosis of peripheral joints: A dilemma in diagnosis. *Tuber Lung Dis* 1993; **74(6)**:399-404. doi: 10.1016/0962-8479(93)90084-B.
2. Monach PA, Daily JP, Rodriguez-Herrera G, Solomon DH. Tuberculous osteomyelitis presenting as shoulder pain. *J Rheumatol* 2003; **30(4)**:851-6.
3. Benbouazza K, Allali F, Bezza A, El Hassani S, el Maghraoui A, Lazrak N, et al. [Pubic tuberculous osteo-arthritis. Apropos of 2 cases]. *Rev Chir Orthop Repar Appar Mot* 1997; **83(7)**:670-2.
4. Meena S, Gangary SK. Tuberculosis of symphysis pubis: A case report. *J Res Med Sci* 2015; **20(1)**:100-2.

Bo Liu<sup>1</sup>, Wendong Xie<sup>2</sup> and Guifu Ma<sup>1</sup>

.....  
<sup>1</sup>Orthopaedics Department, Gansu Provincial Hospital, Gansu, China

<sup>2</sup>Orthopaedics Department, Gansu University of Chinese Medicine, Gansu, China  
.....

Correspondence to: Dr. Guifu Ma, Orthopaedics Department, Gansu Provincial Hospital, No.204, Donggang West Road, Lanzhou, 730000, Gansu Province, China  
E-mail: 15693318899@163.com

.....  
Received: August 15, 2024; Revised: October 08, 2024;  
Accepted: October 12, 2024

DOI: <https://doi.org/10.29271/jcpsp.2025.01.131>

