

Osteomyelitis of the Heel Due to Delayed Treatment of a Left Heel Fracture in a 5-Year Girl

Sir,

Paediatric osteomyelitis commonly involves the femur, tibia, and humerus.¹ The occurrence of paediatric heel osteomyelitis is uncommon. Because the signs and symptoms of the latter are not as obvious as the symptoms observed in osteomyelitis of the long bones, the diagnosis is often missed or delayed.^{2,3} Delayed treatment of paediatric patients may lead to poor outcomes, such as interruption of growth processes, ultimately leading to chronic osteomyelitis and the potential for the spread of the infection to the adjacent joints.⁴ In addition, paediatric heel osteomyelitis may also occur in the context of post-traumatic conditions, or orthopaedic surgery.⁵

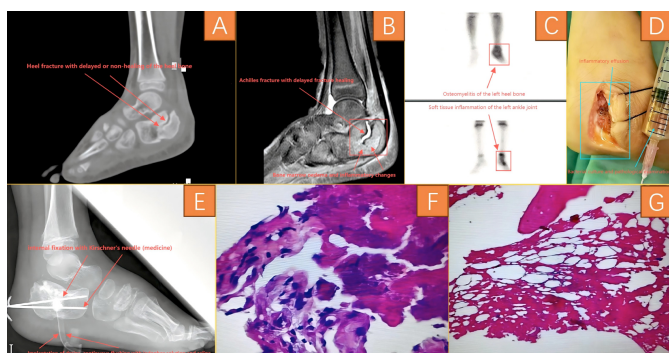


Figure 1: (A) CT scan showing that the left Achilles fracture had not healed, accompanied by soft tissue swelling. (B) MRI showed that the left Achilles fracture had not healed, with high-density images around the fracture, and soft tissue oedema. (C) An emission CT (ECT) bone scan and bone triple-phase showed that there was an increased radiological uptake of the left Achilles and left ankle joint. Radiation uptake was unevenly increased, and in combination with bone triphasic examination, osteomyelitis changes were considered along with soft tissue inflammation around the left-heel bone and left-ankle joint. (D) The fluid was extracted for bacterial culture. (E) X-ray examination showed the fracture was in good alignment, the Kirschner pin was in good position, and the drainage tube was clear. (F, G) Pathological examination showed inflammatory exudates, necrotic bone tissue as well as soft tissue.

A 5-year girl was admitted to the hospital because of pain, swelling, and limited movement of her left foot. The patient's family stated that the child had suffered an injury to her left foot due to strenuous activity three months prior to admission, and was seen in a local hospital, where an x-ray examination revealed a fracture of the left heel bone. The local doctor repositioned the fracture and gave her a plaster cast to fix it externally, and she recuperated at home, with her symptoms gradually relieved. Two months before admission, the family removed the external fixation, and the child gradually carried out functional exercises without any abnormal limb manifestations. Forty-five days before admission, the child's left foot

again showed pain and discomfort with swelling, which could be relieved during rest, and the symptoms gradually worsened 15 days before admission, so the girl was admitted to this hospital.

Physical examination showed that the left foot was swollen, with pain on pressure. The movement of the left foot and left-ankle joint was obviously restricted. CT scan showed that the left Achilles fracture had not healed, and was accompanied by soft tissue swelling (Figure 1A). MRI also showed that the left Achilles fracture had not healed, with high-density images around the fracture, and soft tissue oedema (Figure 1B). An emission CT (ECT) bone scan and bone triple-phase showed that there was an increased radiological uptake by the left Achilles and left-ankle joint. Radiation uptake was unevenly increased, and in combination with bone triphasic examination, osteomyelitis changes were considered along with soft tissue inflammation around the left heel bone and the left-ankle joint (Figure 1C).

After admission, the left foot was examined and the lesion was removed under general anaesthesia. Firstly, the skin and subcutaneous tissues were incised sequentially with a scalpel, and yellowish fluid was seen to flow out, and part of the fluid was extracted for bacterial culture (Figure 1D). Then the necrotic bone tissue was removed with an orthopaedic spatula. The surrounding necrotic soft tissue was removed with an electrocoagulation knife, and a small portion of the bone and soft tissue was taken for pathological examination. Saline and povidone-iodine solution were used to rinse the lesion repeatedly, and finally, the fracture was fixed with Kirschner's pin after repositioning and a drain was placed. One day after the operation, an x-ray examination showed the fracture in good alignment, the Kirschner's pin was in good position, and the drainage tube was clear (Figure 1E). Pathological examination five days after surgery showed inflammatory exudates, necrotic bone tissue as well as soft tissue (Figure 1F, G). The combination of clinical manifestations and imaging and pathological studies was consistent with the diagnosis of osteomyelitis of the heel bone. One month after surgery, an x-ray examination showed that the fracture healed well. At three months postoperatively, the Kirschner's pin was removed and an x-ray examination showed that the fracture was healing well and no inflammatory changes were seen. Currently, the patient has normal limb function and is walking normally.

Fractures leading to osteomyelitis of the heel bone are rare in children with delays in diagnosis. An early diagnosis and adequate treatment is especially important, particularly in children.

COMPETING INTEREST:

The authors declared no conflict of interest.

AUTHORS' CONTRIBUTION:

ZZ: Drafting, revision, and editing process of the manuscript. WX, XL: Questionnaire survey, data collection, analysis, and interpretation.

CZ: Questionnaire survey and data collection.
All authors approved the final version of the manuscript to be published.

REFERENCES

1. Trobs R, Moritz R, Buhligen U, Bennek J, Handrick W, Hormann D, *et al.* Changing pattern of osteomyelitis in infants and children. *Pediatr Surg Int* 1999; **15(5-6)**: 363-72. doi: 10.1007/s003830050600.
2. Lee MC, Tashjian RZ, Ebersson CP. Calcaneus osteomyelitis from community-acquired MRSA. *Foot Ankle Int* 2007; **28(2)**:276-80. doi: 10.3113/FAI.2007.0276.
3. Paakkonen M, Kallio MJ, Peltola H, Kallio PE. Antibiotic Treatment and surgery for acute hematogenous calcaneal osteomyelitis of childhood. *J Foot Ankle Surg* 2015; **54(5)**:840-3. doi: 10.1053/j.jfas.2015.01.006.
4. Giordano M, Aulisa AG, Guzzanti V, Careri S, Krzysztofiak A, Toniolo RM. Managing of musculoskeletal infections in children. *Eur Rev Med Pharmacol Sci* 2019; **23(2 Suppl)**: 179-86. doi: 10.26355/eurrev_201904_17488.

5. Wang H, Pei H, Chen M, Wang H. Incidence and predictors of surgical site infection after ORIF in calcaneus fractures, a retrospective cohort study. *J Orthop Surg Res* 2018; **13(1)**:293. doi: 10.1186/s13018-018-1003-y.

Zhiqi Zhang¹, Wendong Xie², Xiudong Liu² and Chao Zhang³

¹Department of Orthopaedics, Minle County Hospital of Traditional Chinese Medicine, Lanzhou, China

²Department of Orthopaedics, Gansu University of Chinese Medicine, Lanzhou, China

³Department of Orthopaedics, Gansu Provincial Hospital, Lanzhou, China

Correspondence to: Dr. Chao Zhang, Department of Orthopaedics, Gansu Provincial Hospital, Lanzhou, Gansu Province, China

E-mail: zc-315@163.com

Received: October 25, 2024; Revised: November 30, 2024;

Accepted: December 01, 2024

DOI: <https://doi.org/10.29271/jcpsp.2025.03.397>

