

An Emergency Room Case: Air in the Heart

Sir,

Upper gastrointestinal endoscopy is a widely used medical procedure with a low complication rate.^{1,2} Air embolism is a rare complication of upper gastrointestinal endoscopy and leads to potentially life-threatening events.¹ Air embolism associated with endoscopy most often occurs as a complication of endoscopic retrograde cholangiopancreatography; whereas, it is relatively rare in cases of gastroscopy, endoscopic ultrasound, colonoscopy, or in sigmoidoscopy.¹ Herein, we present a case of a patient with air in the right ventricle and pulmonary artery that was detected on his postgastroscopy computed tomography (CT) images.

A 79-year male patient presented to the Emergency Room with coughing and shortness of breath. He had history of Alzheimer's disease, Parkinson's disease, hypertension, and peptic ulcer. His medical history revealed that he had gastric bleeding and thus underwent gastroscopy two months ago. He was discharged in a healthy condition and did not develop any complications after gastroscopy. All blood parameters such as total blood count, urea, creatinine, electrolyte, platelet levels, activated partial thromboplastin time, and international normalised ratio were within normal limits. His systemic examination findings were also normal.

Contrast-enhanced CT performed to detect the cause of the patient's shortness of breath revealed air in the right ventricle, pulmonary artery, biliary tract, and gallbladder along with submassive pulmonary embolism (Figures 1 to 4). The patient was admitted to the intensive care unit due to pulmonary embolism and the detected air. No interventional procedure was performed as air embolism detected on CT images was not acute and was subclinical. Thus, after receiving treatment for pulmonary embolism for five days, the patient was discharged in a healthy condition.

For air embolism to occur, there must be a vascular passage and pressure gradient.³ During gastroscopy, the effective barrier of the normal intestinal mucosa and the low insufflation pressure, which is usually caused by the escape of the supplied air from the proximal or distal intestine, make it difficult for air embolism to occur.⁴ Systemic air embolism is rare due to venous drainage of the liver in gastroscopy, and venous air embolism can occur when the liver is bypassed.⁵ Air, entering the venous system, enters the right heart through portacaval anastomoses, as well as through the liver in a small amount.⁵ Most of the cases are diagnosed based on CT or echocardiogram findings.² Cyanosis, hypotension, tachycardia, bradycardia, cardiac arrhythmia, increased central venous pressure, neurological manifestations, and cardiovascular collapse can be detected in the affected patients.⁶ We believe that when this patient underwent

endoscopy, no imaging or treatment was performed due to the absence of clinical symptoms; hence, air embolism was missed for a long time.

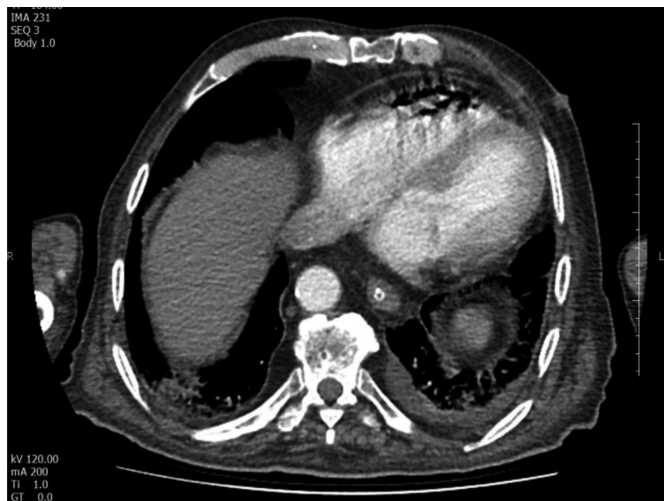


Figure 1: Contrast-enhanced axial CT scan of chest. Air is seen in the heart.

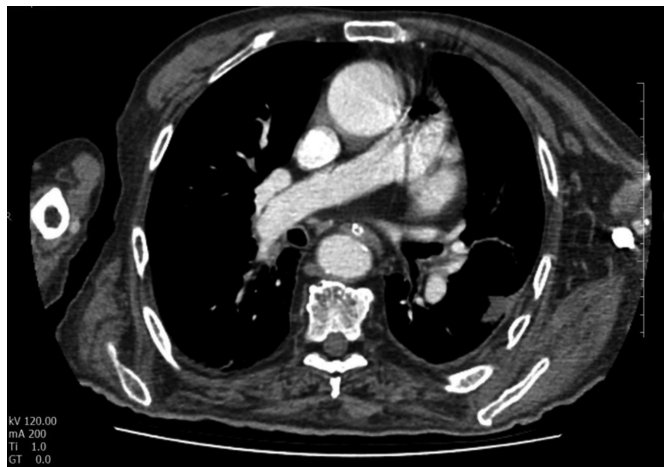

Figure 2: Contrast-enhanced axial CT scan of chest. Air is seen in the pulmonary artery.

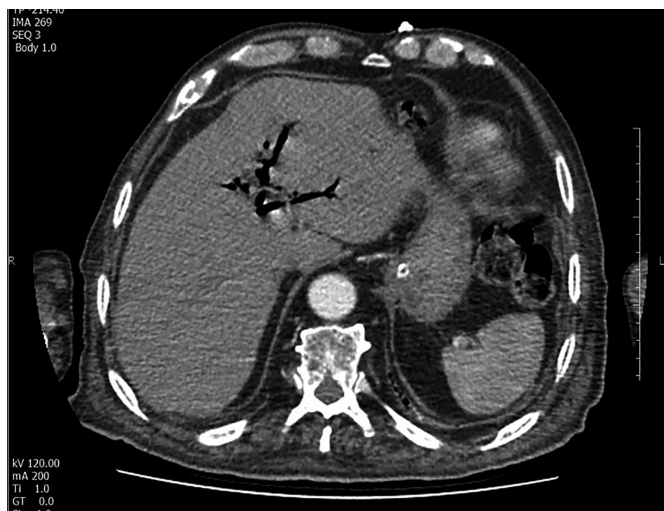


Figure 3: Contrast-enhanced axial CT scan of abdomen. Air is seen in the biliary tract.

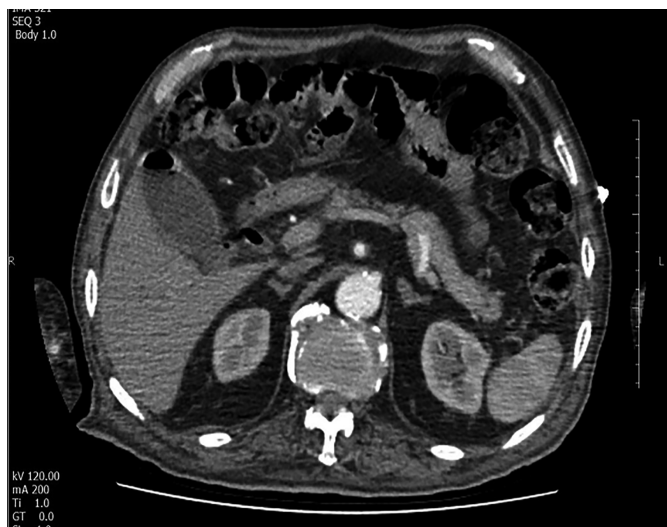

Figure 4: Contrast-enhanced axial CT scan of abdomen. Air is seen in the gallbladder.

Air embolism, a rare complication of gastroscopy, can have a subclinical course. The air can be detected on CT images even after several months. Clinicians should examine the patients' medical histories in detail, if they detect this frightening air image.

CONFLICT OF INTEREST:

The authors declared no conflict of interest.

AUTHORS' CONTRIBUTION:

FG: Connectional design of the work, analysis and interpretation of the data. Agreement to be accountable for all aspects of work.

ED: Drafting the work and revised it. Final approval of the version.

REFERENCES

1. Green BT, Tendler DA. Cerebral air embolism during upper endoscopy: Case report and review. *Gastrointest Endosc* 2005; **61**(4):620-3. doi: 10.1016/S0016-5107(04)02788-9.
2. Ha JF, Allanson E, Chandraratna H. Air embolism in gastroscopy. *Int J Sur* 2009; **7**(5):428-30. doi: 10.1016/j.ijsu.2009.08.003.
3. Ahmed K, Atiq M, Richer E, Neff G, Kemmer N, Safdar K. Careful observation of hepatic portal venous gas following esophageal variceal band ligation. *Endoscopy* 2008; **40 Suppl 2**:E103. doi: 10.1055/s-2007-966850.
4. Emir T, Denijal T. Systemic air embolism as a complication of gastroscopy. *Oxf Med Case Reports* 2019; **2019**(7). doi: 10.1093/omcr/omz057.
5. Azhar M, Upreti S, Sabath BF. Cerebral air embolism after endoscopic variceal band ligation. *ACG Case Rep J* 2020; **7**(8):e00443. doi:10.14309/crj.0000000000000443.
6. Herron DM, Vernon JK, Grysky PV, Reines HD. Venous gas embolism during endoscopy. *Surg Endosc* 1999; **13**(3): 276-9. doi: 10.1007/s004649900963.

Fatih Güneysu and Ensar Durmus

Department of Emergency Medicine, Sakarya University Education and Training Hospital, Sakarya, Turkey

Correspondence to: Dr. Fatih Güneysu, Department of Emergency Medicine, Sakarya University Education and Training Hospital, Sakarya, Turkey

E-mail: fatihgunesu55@hotmail.com

Received: August 17, 2020; Revised: December 16, 2020;

Accepted: January 02, 2021

DOI: <https://doi.org/10.29271/jcpsp.2021.08.1005>

.....