

Comparison of Videothoracoscopy and Thoracotomy in Surgical Treatment of Pulmonary Hydatid Cyst Disease

Cenk Balta¹, Ismail Can Karacaoglu², Duygu Mergan Iliklerden³ and Ali Cem Yekdes⁴

¹Department of Thoracic Surgery, Balikesir University Health Application and Research Hospital, Balikesir, Turkey

²Department of Thoracic Surgery, Van State Health Application and Research Hospital, Van, Turkey.

³Department of Thoracic Surgery, Yüzüncü Yıl University Health Application and Research Hospital, Van, Turkey

⁴Department of Internal Medicine, Balikesir University Health Application and Research Hospital, Balikesir, Turkey

ABSTRACT

Objective: To evaluate the outcomes of videothoracoscopic and open surgeries for pulmonary hydatid cysts.

Study Design: Descriptive study.

Place and Duration of Study: Department of Thoracic Surgery, Faculty of Medicine, Balikesir University, Turkey, between May 2015 and March 2020.

Methodology: Patients who underwent surgery for pulmonary hydatid cysts were evaluated retrospectively, for the age, gender, symptoms, cyst size and localisation, preferred surgery, duration of surgery, the extent of the intraoperative bleeding, duration of the chest drainage, hospitalisation time, and postoperative complications. The relationship between the categorical variables was examined with the Chi-square and Fisher's exact tests and the relationship between the non-parametric data and continuous variables with the Mann-Whitney U-test.

Results: A total of 60 patients included in the study; 23 underwent videothoracoscopic surgery and 37 had thoracotomy. There were no statistically significant differences between groups as gender, age, location and size of cyst. The videothoracoscopic surgery has superiority to thoracotomy group in terms of lower duration of operation, less perioperative bleeding ($p = 0.005$), early chest tube removal and lower hospitalisation time (both $p < 0.001$). But there were no statistical difference between groups in complication rates ($p = 0.340$).

Conclusion: Videothoracoscopic removal of pulmonary hydatid cyst is a safe and advantageous procedure comparing to thoracotomy. There is a need for prospective studies with a larger sample size.

Key Words: Hydatid cyst, Thoracoscopic surgery, Thoracotomy, VATS.

How to cite this article: Balta C, Karacaoglu IC, Iliklerden DM, Yekdes AC. Comparison of Videothoracoscopy and Thoracotomy in Surgical Treatment of Pulmonary Hydatid Cyst Disease. *J Coll Physicians Surg Pak* 2020; **30(10)**:1063-1068.

INTRODUCTION

Hydatid cyst disease is an occasional infection in humans caused by a parasite called *Echinococcus*. It is prevalent in regions like the Middle-East, South America, Africa, Australia, India, and Balkans, where animal husbandry is common and preventive medicine measures are not well developed.¹

Regarding the lifecycle of *Echinococci*, animals like goat and sheep are intermediate hosts and carnivores like dogs are definitive hosts. The most commonly involved organs are the liver (60-70%) and lungs (20-25%).² The pulmonary involvement is more common on the right side and lower lobe as a result of the higher perfusion.³

Although thoracotomy and sternotomy are the preferred methods in the treatment of pulmonary hydatid cysts, video-assisted thoracoscopic surgery (VATS) became popular recently due to its advantages. However, the published studies were rather focused on small groups, mostly pediatric patients.^{4,5}

In this study, the objective was to evaluate the results of VATS and open surgery in patients, who underwent surgery for pulmonary hydatid cyst disease.

METHODOLOGY

Patients who underwent surgery due to the pulmonary hydatid cyst in two centres (Faculty of Medicine Balikesir University and Van Training and Research Hospital) between May 2015 and March 2020 were evaluated in this retrospective study. All patients were diagnosed with the clinical and radiological examinations (*i.e.* chest x-ray and computed tomography). The demographic characteristics and clinical, radiological, and surgical data of the patients were obtained from the hospital archives. Patients, whose hospital records were not available and had multiple pulmonary hydatid cysts, were excluded from the

Correspondence to: Dr. Cenk Balta, Department of Thoracic Surgery, Balikesir University Health Application and Research Hospital, Balikesir, Turkey
E-mail: drcenkbalta@gmail.com

Received: May 20, 2020; Revised: July 25, 2020;

Accepted: August 17, 2020

DOI: <https://doi.org/10.29271/jcpsp.2020.10.1063>

study. The patients were evaluated for the age, gender, symptoms, cyst size and localisation, preferred surgery, duration of surgery, the extent of the intraoperative bleeding, duration of the chest drainage, hospitalisation time, and postoperative complications.

Both the surgeries were performed by the three surgeons, who participated in the study. The patients has been operated by thoracotomy in the early days of the study. The VATS procedure was performed in the late term of the study.

Group 1 (VATS group) underwent VATS, carried out after the double-lumen intubation in the decubitus position. A 3-4 cm long utility incision was done on the anterior axillary line at the level 5th intercostal space. After the determination of the cyst with a 30-degree videothoracoscope, gauzes impregnated with iodopovidone was placed to prevent the contamination of the thoracic cavity. After the aspiration of cystic fluid with a Veress needle and closed suction system, hypertonic solution was injected into the cyst and the process was held on for 5 minutes (Figure 1a). The fibrous capsule was opened with a bipolar tissue sealing device (LigaSure™-Covidien, Dublin, Ireland) or electro-cautery. The germinative membrane was removed with an endobag to prevent the contamination (Figure 1b). The fibrous redundant tissues were cut using a bipolar tissue sealing device to widen the cyst cavity for an adequate exposure in all patients. The cyst walls were wiped with iodopovidone impregnated gauzes. The bronchial connections were stitched, if detected. The cyst cavity was quilted (capitonnage) with absorbable stitches. Following the control of hemorrhage and air leak, a small intrapleural chest tube (16-24 Fr) was inserted through the utility incision. The incision was closed with single muscle suturing without using pericostal stitches (Figure 1c, d). Additionally, the patients who had peripheral lesions less than 3 cm, underwent wedge resection with the same utility incision following to aspiration of the cystic fluid. Following the control of hemorrhage and air leak, the same procedure was performed.

Group 2 (Thoracotomy group) underwent thoracotomy, carried out with a standard posterolateral thoracotomy incision (approx. 8-16 cm) after the double-lumen intubation. Following the incision and the cutting of the muscle layers, a rib spreader was placed in the intercostal space. After the cyst was detected, iodopovidone impregnated gauzes were placed around the cyst to prevent the contamination. Following the aspiration of the cystic content, exocyst was opened and the germinative membrane was removed. The redundant cystic tissues were cut using a bipolar tissue sealing device to widen the cyst cavity for better exposure in all patients. The bronchial connections – if detected – were stitched and the cyst cavity was quilted (capitonnage) with absorbable stitches. Following the hemorrhage and air leak control, a chest tube (28-36 Fr) was inserted and the thoracotomy incision was closed.

All patients received analgesic agents and prophylactic antibiotics during the postoperative period. Diclofenac sodium was the first medication choice for early postoperative pain management. It has been given intramuscularly three times a day.

Tramadolol hydrochloride was added to the analgesic regime, if the patient felt pain despite an adequate dose of diclofenac sodium.

The chest tube was removed when no air leak was detected and the daily drained fluid dropped below 100cc. After discharge, patients were followed up in the 1st, 2nd, 3rd and 6th months by radiologic imaging. All patients received 10mg/kg/day albendazole for postoperative 3 months.

Data were analysed by the SPSS (Statistical Package for the Social Sciences Version 22.0 (SPSS Inc. Chicago, IL, USA) software package. Normal distribution of the data was assessed with the Shapiro-Wilk test. The median value, 25 and 75 percentiles of the non-parametric data and the numeric values and percentages of the categorical variables were calculated as descriptive statistics. The relationship between the categorical variables was examined with the Chi-square and Fisher's exact tests and the relationship between the non-parametric data and continuous variables with the Mann-Whitney U-test. For all analyses, $p < 0.05$ was considered as statistically significant.

This study was approved by local Ethics Committee (Decision No: 2020/06). As the study had a retrospective design, the informed consent had not been obtained from patients. The study was performed in adherence to the World Medical Association Declaration of Helsinki Ethical Principles for Medical Research Involving Human Subjects.

RESULTS

A total of 60 patients were included in the study. The median age of the participants was 20 years (14-33 years). Thirty-four (56.67%) of them were males and 26 (43.33%) were females. Twenty-three (38.33%) patients had undergone VATS and 37 (61.67%) thoracotomy. The cough was the most common symptom ($n=32$; 53.33%). Chest pain ($n=25$; 41.67%), dyspnea ($n=16$; 26.67%), and fever ($n=7$; 11.67%) were other recorded symptoms. Four of the patients (6.67%) were asymptomatic and diagnosed incidentally in other clinics. Two patients (3.33%) had swelling in the neck veins as a result of the vena cava superior compression. One patient had hemoptysis (Table I).

The hydatid cyst was localised in the right lower lobe (RLL) in 20 patients (33.33%), left lower lobe (LLL) in 18 patients (30%), right upper lobe (RUL) in 11 patients (18.33%), left upper lobe (LUL) in 8 patients (13.33%), and right middle lobe (RML) in 3 patients (5%). The median diameter of the cysts was 73mm (52-90.75mm); and 21 patients (35%) had a ruptured cyst in the preoperative examination. Ten patients (16.67%) had also hydatid cyst in the liver (Table I).

There was no statistically significant difference between two groups regarding the age ($p=0.091$), gender ($p=0.986$), cyst localisation ($p=0.834$), and cyst size ($p=0.176$). However, the amount of the ruptured cysts were significantly higher in Group 1 ($n=13$; 56.5%) compared to Group 2 ($n=8$; 21.6%) ($p=0.006$) (Table II).

Table I: Demographic parameters.

Parameters		n=60
Age (median, 25-75)		20 (14-33)
Gender (n, %)	Men	34 (56.67%)
	Women	26 (43.33%)
Symptom (n, %)	cough	32 (53.33%)
	chest pain	25 (41.67%)
	dyspnea	16 (26.67%)
	fever	7 (11.67%)
	symptomless	4 (6.67%)
	SVCS	2 (3.33%)
	hemoptysis	1 (1.67%)
Localisation of cyst (n, %)	RLL	20 (33.33%)
	LLL	18 (30%)
	RUL	11 (18.33%)
	LUL	8 (13.33%)
	RML	3 (5%)
Cyst diameter (median, 25-75)		73 (52-90.75)
Type of surgery (n, %)	Videothoracoscopy	23 (38.33%)
	Thoracotomy	37 (61.67%)
Cystic membrane (n, %)	Intact	39 (65%)
	Ruptured	21 (35%)
Additional liver hydatid cyst (n, %)		10 (16.67%)
N: Number, RUL: Right Upper Lobe, RLL: Right Lower Lobe, LUL: Left Upper Lobe, LLL: Left Lower Lobe, RML: Right Middle Lobe, SVCS: Superior Vena Cava Syndrome.		

In all VATS patients, the procedure was started with a uniportal incision. Depending on the exposure and bronchial fistula stitching difficulties, the surgery was completed with a second camera port in 8 patients (34.78%) and with a 5-cm extension of the incision (mini-thoracotomy) in 4 patients (17.39%).

The duration of surgery was 85 minutes (70-90 minutes) in Group 1 and 160 minutes (120-210 minutes) in Group 2. VATS procedure was significantly shorter than thoracotomy ($p < 0.001$). The median duration of chest drain was 3 days (2-3 days) in Group 1 and 6 days (4-7 days) in Group 2. The duration of the chest drain who underwent VATS, was statistically shorter than thoracotomy ($p < 0.001$). Median hospitalisation time was 4 days (3-4 days) in Group 1 and 7 days (5.5-10 days) in Group 2. The hospitalisation time was significantly shorter in the VATS group compared to thoracotomy group ($p < 0.001$). The amount of perioperative bleeding was 50cc (40-80cc) in Group 1 and 85cc (60-140cc) in Group 2. These results showed that bleeding was significantly less in the VATS group compared to the thoracotomy group ($p = 0.005$, Table III).

A total of 12 patients had complications in the postoperative period. The most common complications were air leak ($n = 4$), atelectasis ($n = 3$), and seroma ($n = 3$). The liver functions tests were elevated in one patient during the postoperative period and medical treatment was initiated. Pneumothorax emerged in one patient after the removal of the chest tube and the chest tube was reinserted. There was no statistically significant difference between the groups for the complication rates (13.04%, 24.32% respectively; $p = 0.340$, Table III). No recurrence was observed in the follow-up.

DISCUSSION

According to the reports of the WHO, the incidence of hydatid cyst is 220/100,000 in the endemic regions.⁶ The aim of the treatment was the complete removal of the parasite with maximal preservation of the healthy lung tissue and prevention of the recurrence.³

Open surgery procedures were the choice of treatment for many years. The minimal invasive hydatid cyst surgery was first introduced in 1994 in pediatric patients and became an alternative method to open surgery.⁷ However, it did not become popular due to the perioperative contamination risk of the thoracic cavity, difficulties related to the capitonnage and stitching of the bronchial fistulas.^{3,8,9}

It was also reported that the VATS was contraindicated in patients with a hydatid cyst larger than 10 cm, multiple cysts in one lung, and cysts located in the hilum, and the single lung ventilation difficulties in children under the age 10.^{4,10} However, later it was demonstrated that large cysts might be removed after aspiration¹¹ and multiple or hilar cysts were operable despite of certain difficulties.¹² The localisation of cysts smaller than 2 cm is relatively more difficult to detect but this problem can be overcome with proper radiological mapping.

Although hydatid cyst can be seen in any pulmonary lobe, it is more common on the right side and in the lower lobes depending on the lower ventilation: perfusion ratio.^{2,4,13} In this study, 63.33% ($n = 38$) of cysts were in the lower lobe and 56.67% ($n = 34$) in the right lung; and these rates were consistent with other studies. The concomitant involvement of the liver and lung is common,^{1,2,6,14} and in this study, we detected a hydatid cyst in the liver of 10 patients (16.67%).

The advantages of VATS compared to the thoracotomy as duration of the surgery, intraoperative bleeding, duration of the chest drain, hospitalisation time, pain severity, duration of the narcotic analgesic administration, postoperative complications, and wound healing on the incision site were reported in several studies. According to the results of former studies, the larger incision, risk of rib fracture and intercostal nerve injury increases pain severity and consequently hospitalisation time and amount of used analgesics in the thoracotomy group.^{3,4,8-13,15}

Air leak and bronchopleural fistula are the major complications seen after the hydatid cyst surgery. It may provide long hospital stay and reoperation. Ocakcioğlu *et al.* compared the hydatid cysts surgeries performed with VATS and thoracotomy and did not find any statistically significant difference between these methods in complication rates.¹⁵

In the present study, a total of 12 patients had complications in both groups during the postoperative period and the most common complication was air leak.

Table II: Comparison of preoperative evaluations.

		Videothoracoscopy (n:23)		Thoracotomy (n:37)		p
		Median N	Percentiles %	Median N	Percentiles %	
Age		17.00	7.00-33.00	20.00	16.50-37.00	*0.091
Gender	Male (n)	13	56.5%	21	56.8%	**0.986
	Female (n)	10	43.5%	16	43.2%	
Location	LLL	6	26.1%	12	32.4%	**0.834
	RLL	9	39.1%	11	29.7%	
	LUL	4	17.4%	4	10.8%	
	RUL	3	13.0%	8	21.6%	
	RML	1	4.3%	2	5.4%	
Diameter		65.00	38.00-88.00	75.00	58.00-97.50	*0.176
Cyst rupture		13	56.5%	8	21.6%	0.006

N: Number, RUL: Right Upper Lobe, RLL: Right Lower Lobe, LUL: Left Upper Lobe, LLL: Left Lower Lobe, RML: Right Middle Lobe.

Table III: Statistical comparison of groups.

	Videothoracoscopy (n:23)		Thoracotomy (n:37)		p
	Median n	Percentiles %	Median n	Percentiles %	
Operation duration (min)	85.00	70.00-90.00	160.00	120.00-210.00	*<0.001
Time to drain removal (d)	3.00	2.00-3.00	6.00	4.00-7.00	*<0.001
Time to discharge (d)	4.00	3.00-4.00	7.00	5.50-10.00	*<0.001
Intraoperative blood loss	50.00	40.00-80.00	85.00	60.00-140.00	*0.005
Complications	3	13.04%	9	24.32%	0.340

D: Day, Min: minutes, N: Number.

The author did not perform any re-operations due to the air leak which was stopped spontaneously in all cases. We also did not find any significant difference between the groups for the postoperative complication rates (13.04%, 24.32% respectively; $p=0.340$).

Ma *et al.* reported that the mean duration of surgery was 99.90 minutes in hydatid cyst patients.³ Metha *et al.* stated that the duration of surgery was shorter in VATS (95.21 versus 137.77 minutes).¹⁶ Ocakcioğlu *et al.* determined the operating time as 80.71 minutes and 110.94 minutes, respectively.¹⁵ It was found in the present study that operating time was shorter in the VATS group (85 minutes vs. 160 minutes). The authors believe that this difference depends on the time required for the opening and closure procedures in thoracotomy incision.

Alpay *et al.* stated that mean postoperative hospitalisation was shorter in the VATS group comparing to thoracotomy group (8.35 versus 18.77 days).⁴ The same parameter was 10.5 days in the VATS group in the study conducted by Ma *et al.*³ Agarwal *et al.* stated that the mean hospitalisation

time was 5 days.¹³ In the authors' study focused on hydatid cyst patients undergoing VATS alone, hospitalisation time was 3.55 days.¹¹ In this study, the median hospitalisation time was significantly shorter in patients who undergone videothoracoscopic surgery [median value = 4 days (3-4) vs. 7 (5.5-10) days, respectively; $p<0.001$].

Postoperatively, an intrapleural chest tube is inserted to provide pulmonary expansion and to determine the volume of the postoperative drainage. The chest tube should not be removed before the expansion of the lungs and discontinuation of active drainage. In the study conducted by Ocakcioğlu *et al.*, this duration was significantly shorter in the VATS group (3.07 ± 0.83 vs. 4.15 ± 1.01 , respectively; $p<0.001$) and they also stated that the less pain levels causes the early discharge.¹⁵ Alpay *et al.* reported also the superiority of the VATS group (mean duration: 5 days vs. 8.83 days).⁴

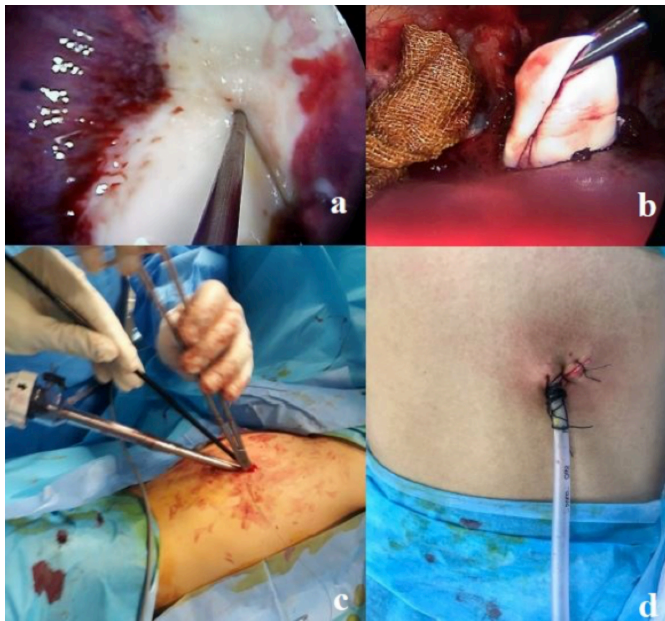


Figure 1: (a) Aspiration of cystic fluid by veress needle. (b) Removal of cystic membrane. (c) Peroperative view of cystic membrane. (d) Postoperative view of incision line.

In this study, the duration of chest drain was significantly shorter in the VATS group (median duration: 3 days (2-3) vs. 6 days (4-7 days) respectively; $p < 0.001$).

Ma *et al.* reported that peroperative bleeding was milder in the VATS group.³ Alpay *et al.* compared the postoperative drainage between VATS and thoracotomy and did not find any significant difference.⁴ In this study, the authors were determined that there was less bleeding in the VATS group. This difference depends on the larger incision and the higher number of incised muscle layers in the thoracotomy group.

Several authors stated in their studies that wedge resection could be performed in the peripheral lesions, segmentectomy could be preferred in lesions involving whole segment, and lobectomy could be the choice of treatment if the lesion is involved more than 60% of the lobe.^{3,4,10} In this study, four patients in the VATS group, who had peripheral lesions, underwent wedge resection and a patient in thoracotomy group underwent lobectomy as the cyst involved more than 90% of the lobe. Neither segmentectomy nor pneumonectomy was performed in any of these patients. In all VATS cases, with a uniportal approach, either a second port ($n=8$) was opened or mini-thoracotomy was performed [hybrid VATS (hVATS)] ($n=4$) if the exposure impaired or due to the suturing difficulties of the bronchial fistulas. These conversions occurred in the very early stage of learning process and no conversion was necessary in the recent period.

The retrospective design, lack of visual analog scale (VAS) and small study sample are the limitations of the present study. The comparative analysis of two groups with no significant difference for age, gender, cyst size, and localisation are the strength of this study.

CONCLUSION

VATS in pulmonary hydatid cyst surgery has the advantages of shorter duration of surgery, less intraoperative bleeding, short duration of chest drain, and shorter hospitalisation time. In this context, it is concluded that surgical treatment is a safe and advantageous choice in selected cases. There is a need for prospective studies with a larger sample size and cost efficiency studies for further evaluation.

ETHICAL APPROVAL:

Ethics Committee approval for the study was received from Van Training and Research Hospital Local Ethics Committee (2020/06, Date: 16/04/2020).

PATIENTS' CONSENT:

The necessary consent forms were obtained from the patients for the study.

CONFLICT OF INTEREST:

Authors declared no conflict of interest.

AUTHORS' CONTRIBUTION:

CB: Conception and design of the work, acquisition, analysis, and interpretation of the data for the work; and agreed to be accountable for all aspects of the work in ensuring that questions related to the accuracy or integrity of any part of the work were appropriately investigated and resolved; final approval of the version to be published; drafting the work; designing the work; interpretation of data for the work.

ICK: Drafting the work or revising it critically for important intellectual content; designing of the work; interpretation of data for the work.

DMİ: Substantial contributions to the conception or design of the work, or the acquisition, analysis, or interpretation of data for the work, drafting the work or revising it critically for important intellectual content.

ACY: Acquisition, analysis, or interpretation of data for the work, drafting the work or revising it critically for important intellectual content. Final approval of the version to be published.

REFERENCES

1. Auldirst AW, Blakelock R. Pulmonary hydatid disease. *Pediatric Thoracic Surgery* London. Springer 2009; pp. 161-7.
2. Dakak M, Genç O, Gürkök S, Gözübüyük A, Balkanlı K. Surgical treatment for pulmonary hydatidosis (a review of 422 cases). *J R Coll Surg Edinb* 2002; **47(5)**:689-92. PMID: 12463709.
3. Ma J, Wang X, Mamatimin X, Ahan N, Chen K, Peng C, *et al.* Therapeutic evaluation of video-assisted thoracoscopic surgery versus open thoracotomy for pediatric pulmonary hydatid disease. *J Cardiothorac Surg* 2016; **11(1)**:129. doi: 10.1186/s13019-016-0525-9. PMID: 27495934
4. Alpay L, Lacin T, Ocakcioglu I, Evman S, Dogruyol T, Vayvada M, *et al.* Is video-assisted thoracoscopic surgery adequate in treatment of pulmonary hydatidosis? *Ann*

- Thorac Surg 2015; **100(1)**:258-62. doi: 10.1016/j.athorac-sur.2015.03.011. PMID: 26004922.
5. Dokumcu Z, Arslan S, Divarci E, Erdener A, Ozcan C. Thoracoscopic treatment of pulmonary hydatid cysts may have a high morbidity risk in children: Retrospective analysis. *Eurasian J Med* 2017; **49(3)**: 172-7. doi: 10.5152/eurasian-jmed.2017.17080 PMID: 29123439.
 6. Organization WH. Guidelines for treatment of cystic and alveolar echinococcosis in humans. WHO informal working group on echinococcosis. *Bull World Health Organ* 1996; **74**:231-42.
 7. Becmeur F, Chaouachi B, Dhaoui R, Kaabar N, Popperova N, Bientz J, et al. Video-assisted thoracic surgery of hydatid cysts of the lung in children. *J Chir (Paris)* 1994; **131(12)**:541-3. PMID: 7738124.
 8. Amine K, Samia B, Jamila C, Mohamed BB, Lassad S, Sana M, et al. Thoracoscopic treatment of pulmonary hydatid cyst in children: A report of 25 cases. *Tunis Med* 2014; **92(5)**: 341-4. PMID: 25504388.
 9. Findikcioglu A, Karadayi S, Kilic D, Hatiopoglu A. Video-assisted thoracoscopic surgery to treat hydatid disease of the thorax in adults: Is it feasible? *J Laparoendosc Adv Surg Tech A* 2012; **22(9)**:882-5. doi: 10.1089/lap.2012.0272.
 10. Abbas N, Zaher Addeen S, Abbas F, Al Saadi T, Hanafi I, Alkhatib M, et al. Video-assisted Thoracoscopic Surgery (VATS) with mini-thoracotomy for the management of pulmonary hydatid cysts. *J Cardiothorac Surg* 2018; **13(1)**:35. doi: 10.1186/s13019-018-0716-7.
 11. Balta C. Uniportal-single incision thoracoscopic access for pulmonary hydatid cysts. *Curr Resp Med Rev*; 2019, **15**, 39-44. doi: 10.2174/1573398X15666190508090653.
 12. Turna A. Minimally invasive approach for pulmonary hydatid cyst. *J Vis Surg* 2019; **5**:16. doi: 10.21037/jovs. 2019.01.09.
 13. Agarwal N, Veetil KD, Rane N, Kukreja B, Prasad A, Khan AZ. Role of vats in management of pulmonary hydatid and follow up: A case series. *EC Pulmonol Resp Med* 2018; **10**:714-20.
 14. Arinc S, Kosif A, Ertugrul M, Arpag H, Alpay L, Unal O, et al. Evaluation of pulmonary hydatid cyst cases. *Int J Surg* 2009; **7(3)**:192-5. doi: 10.1016/j.ijsu.2008.11.003.
 15. Ocakcioglu I, Sayir F. Uniportal thoracoscopic approach for pulmonary hydatid cyst: Preliminary results. *Surg Laparosc Endosc Percutan Tech* 2018; **28(5)**:298-302. doi: 10.1097/SLE.0000000000000560.
 16. Mehta KD, Gundappa R, Contractor R, Sangani V, Pathak A, Chawda P. Comparative evaluation of thoracoscopy versus thoracotomy in the management of lung hydatid disease. *World J Surg* 2010; **34(8)**:1828-31. doi: 10.1007/s00268-010-0581-6.

• • • • •