

# Dyna-CT-based Image Fusion Technique Real-time-assisted Percutaneous Micro-balloon Compression in the Treatment of Trigeminal Neuralgia

Zhe Cheng, Qing Chao and Di Di Pan

*Department of Neurosurgery, The Second Affiliated Hospital of Bengbu Medical College, Bengbu City, Anhui Province, China*

## ABSTRACT

To investigate the efficacy and safety of percutaneous micro-balloon compression (PBC) assisted by Dyna-CT-based image fusion technique in the treatment of trigeminal neuralgia (TN). This study is the retrospective analysis of the efficacy and safety of 18 patients with TN treated by PBC assisted with Dyna-CT-based image fusion technique from May 2020 to May 2021. The puncture route from the skin to the foramen ovale (FO) was reconstructed after Dyna-CT scanning; and the puncture direction was adjusted according to the virtual puncture route until the puncture was completed. Dyna-CT-assisted puncture was successful in all 18 patients. The puncture was accurate and effectively shortened the operation time. Importantly, pain was relieved in all patients, and no puncture-related complications occurred. Dyna-CT-based image fusion real-time-assisted PBC for the treatment of TN is safe and effective, making the operation easier and faster, greatly improving the success rate of the puncture, and reducing the risk of operation-related complications.

**Key Words:** Dyna-CT, Percutaneous micro-balloon compression, Trigeminal neuralgia.

**How to cite this article:** Cheng Z, Chao Q, Pan DD. Dyna-CT-based Image Fusion Technique Real-time-assisted Percutaneous Micro-balloon Compression in the Treatment of Trigeminal Neuralgia. *J Coll Physicians Surg Pak* 2022; **32(04)**:544-547.

Trigeminal neuralgia (TN), the most common neurological disease, is mainly characterised by intermittent and severe pain in the facial distribution area of the trigeminal nerve; and mainly occurs in middle-aged women. In 1983, Mullan *et al.* first reported percutaneous micro-balloon compression (PBC) in the treatment of TN.<sup>1</sup> PBC is widely used in patients who could experience difficulty during micro-vascular decompression (MVD), patients with recurrence after MVD, and radiofrequency surgery, and elderly patients.

The failure of PBC is mainly due to difficulty in puncturing the foramen ovale (FO). Accurate puncture of the FO is difficult for novice surgeons, and repeated puncture failures increase the risk of unpredictable vascular and nerve injury.<sup>2,3</sup> It has been reported that Dyna-CT-assisted PBC treatment of TN can achieve visualisation and accurate FO puncture, which can reduce the risk and difficulty of the procedure.<sup>4</sup> Using Dyna-CT-assisted PBC treatment of TN, a multimodal image fusion reconstructed the skull base and the FO, and simulated the puncture route able to be generated, resulting in an FO puncture that was more accurate.

From May 2020 to May 2021, 18 patients with TN received Dyna-CT-assisted PBC in The Second Affiliated Hospital of Bengbu Medical College (Bengbu, Anhui Province, China). Inclusion criteria were primary TN, which did not respond to medication or had side effects, and the patients agreed to PBC. Exclusion criteria as secondary TN. The 3D Slicer software version 4.11 (<http://download.slicer.org/>) was used to reconstruct the trigeminal nerve and its adjacent vascular. The length and width of FO were measured. The three-dimensional (3D) anatomical structures of the trigeminal nerve, Meckel's cave, and offending vessels were reconstructed. The head was scanned by Dyna-CT, and the skull was then reconstructed. The puncture route from the skin to the FO was sketched on a post-processing workstation (GE model: Discovery IGS 630, AW AWWVOLUMESHORE7, Wisconsin, USA). Under real-time fluoroscopy, 0.2–0.8 ml of non-ionic contrast medium was injected into the balloon until a typical pear-shaped structure appeared. The balloon was emptied after continuous compression for 2–5 mins, then image fusion reconstruction was performed after another Dyna-CT scan to confirm the position and shape of the balloon.

The preoperative images of the 18 patients were reconstructed by the 3D slicer. The average FO was  $4.37 \pm 0.59$  mm in length and  $2.21 \pm 0.61$  mm in width. The offending vessels of 12 of the 18 patients were ipsilateral superior cerebellar arteries. Dyna-CT scanning was performed before the operation, and the puncture route from skin to the FO was constructed and simulated.

Correspondence to: Di Di Pan, Department of Neurosurgery, The Second Affiliated Hospital of Bengbu Medical College, Bengbu City, Anhui Province, China  
E-mail: 17521199596@163.com

Received: November 21, 2021; Revised: December 28, 2021;  
Accepted: January 18, 2022  
DOI: <https://doi.org/10.29271/jcpsp.2022.04.544>

**Table I: Clinical data of 18 patients with TN treated with Dyna-CT-assisted PBC.**

No.	Sex/Age	Side	Symptoms	Preoperative BNI score	Length of FO	Width of FO	Offending vessels	Operation time (min)	Compression time (min)	Outcome	Facial numbness
1	M/56	R	V2	IV	4.39	2.89	AICA	60	3	NO pain	++
2	M/57	R	V2	V	4.4	1.96	SCA	70	2.5	NO pain	+
3	M/83	R	V2	IV	5.24	2.93	AICA	60	2.5	NO pain	++
4	M/56	R	V1, 2, 3	IV	3.51	1.26	SCA	80	2.5	NO pain	+
5	F/59	L	V2	IV	4.6	3.08	SCA	65	2.5	NO pain	+
6	F/68	R	V2, 3	V	4.7	2.17	SCA	90	3	NO pain	+++
7	M/74	R	V2, 3	IV	4.6	3.08	SCA	60	2	NO pain	+
8	F/59	R	V2	IV	3.7	2.59	BA	105	2.5	NO pain	+
9	F/87	L	V2	IV	3.47	1.52	AICA	60	3.5	NO pain	++
10	F/56	R	V2	III	5.2	2.21	AICA	115	2.5	NO pain	+
11	M/69	R	V2	IV	4.24	1.83	AICA	75	3.5	NO pain	+++
12	F/70	L	V3	IV	3.79	1.5	SCA	105	3.5	NO pain	+
13	F/66	L	V3	IV	3.7	2.44	SCA	70	3	NO pain	+
14	F/64	R	V1, 2	IV	3.93	1.7	SCA	35	2	NO pain	+
15	F/65	R	V2	IV	4.62	2.37	SCA	70	2	NO pain	+
16	M/57	L	V2	IV	5.1	3.42	SCA	60	2.5	NO pain	+
17	F/84	R	V2, 3	IV	4.32	1.53	SCA	60	3	NO pain	+
18	F/84	L	V2	IV	5.24	2.14	SCA	45	4	NO pain	+++

M: Male; F: Female; R: Right; L: Left; BNI: Barrow neurological institute; FO: Foramen ovale; Millimeters (mm) for the length and width of FO; V1 (Ophthalmic); V2 (maxillary) and V3 (mandibular); Mild: +; Moderate: ++; Severe: +++.

The puncture was carried out according to the virtual puncture route during the operation until the typical pear-shaped structure appeared, and then Dyna-CT scan was performed again to confirm the shape and position of the balloon. Overall, the success rate of PBC was 100%, the operation time was  $71.39 \pm 20.92$  minutes and the compression time was  $3.44 \pm 0.48$  minutes. The pain was completely relieved after the operation in all 18 patients. There was no recurrence during the follow-up period of half to one year (Figure 1, Table I).

MVD and PBC are the most widely used surgical treatments for TN. It has been proven that PBC has the advantages of being minimally invasive, simple, effective, low cost and safe. However, studies have reported that puncture-related complications of PBC due to incorrect location of FO during punctures, such as internal carotid artery injury, cerebrospinal fluid leakage, nerve injury caused by puncture into the infraorbital fissure or orbital wall, are common.<sup>5</sup> Recently, a series of studies have found that some methods can assist puncture to improve the success rate of PBC and reduce complications. Xiao *et al.* used Dyna-CT to achieve accurate puncture of the FO, which improved the success rate of the surgical puncture and reduced operative complications.<sup>6</sup> Personalised 3D printing guide plate was used to assist PBC to accurately locate the puncture point. Electromagnetic neuronavigation technology assists PBC to achieve accurate and rapid puncture of the FO.

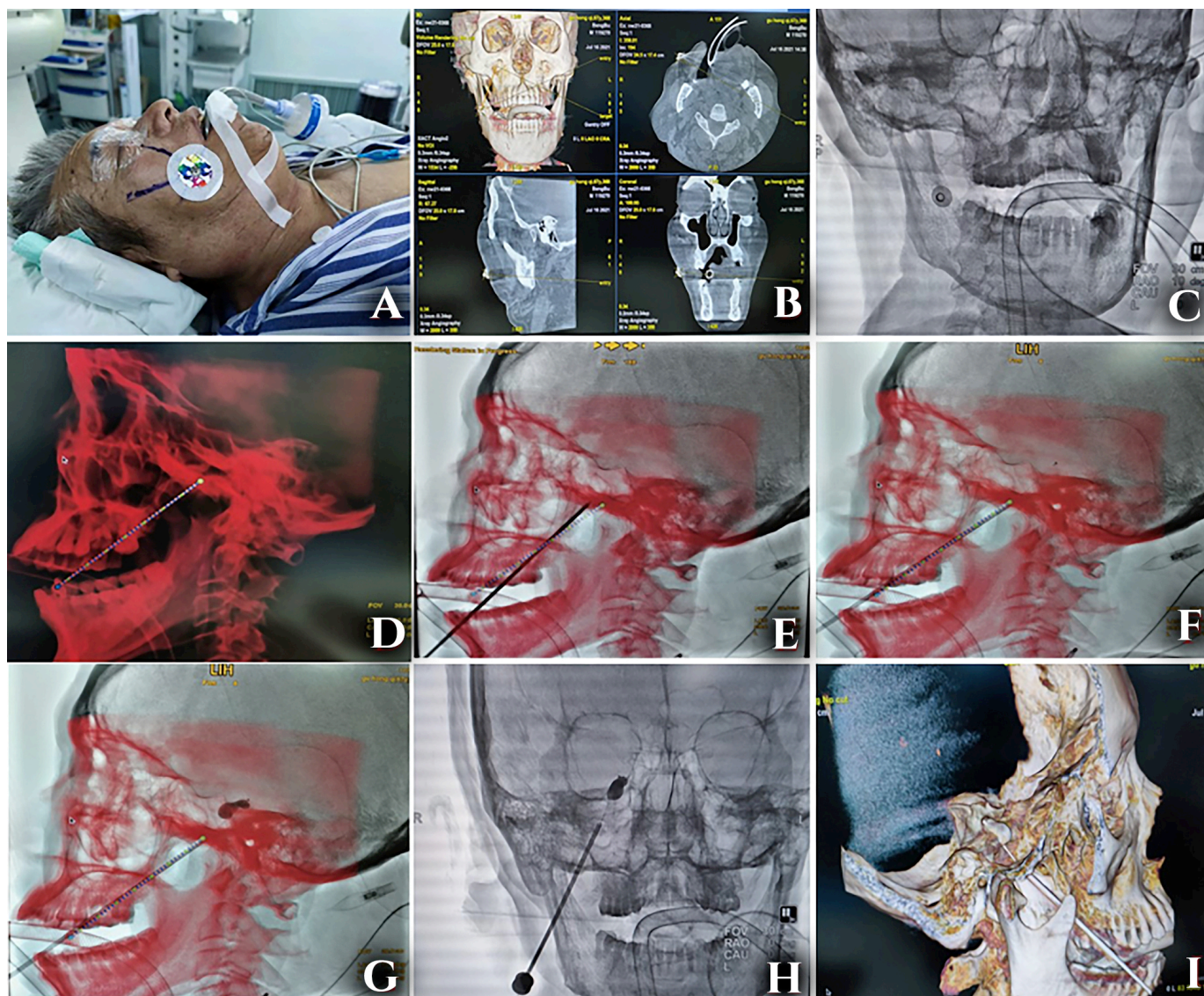
In this study, 18 patients underwent preoperative multi-modal image fusion with 3D slicer, and the FO, trigeminal

nerve, and offending vessels were reconstructed. Skull base reconstruction was able to accurately reconstruct the shape and size of the FO. Unfortunately, it is unable to evaluate the offending vessels from veins. Dyna-CT 3D scanning fusion was used to simulate the puncture path from skin to the FO, and the puncture direction was adjusted in real-time to make the puncture more accurate, greatly improving the puncture efficiency and shortening the operation time. Image fusion reconstruction was performed again postoperation to determine the position and shape of the balloon.

The number of patients is limited and there is no controlled comparison, so this study has some limitations. The future research will have larger sample size, with a control group and longer follow-up time.

An accurate and rapid puncture can shorten the operation time and reduce the related complications caused by the puncture. In this study, Dyna-CT-assisted PBC treatment of TN, which provided accuracy in locating the FO, avoided repeated punctures, shortened the operation time, and improved the success rate of the puncture. The image fusion processing after Dyna-CT scan can assist PBC in real-time during the treatment of TN by simulating the puncture path and correcting the puncture direction, which can significantly improve the success rate of puncture, and avoid complications caused by puncture errors. Dyna-CT-assisted PBC treatment of TN is safe and effective, making the operation easier and faster, greatly improving the success rate of the puncture, and reducing the risk of operation-related complications.





**Figure 1: Dyna-CT-assisted PBC treatment of TN.** (A) The lateral corner of the mouth was marked with metal; (B) Dyna-CT scanning; (C) Reconstruction the puncture path; (D) The dotted line is the puncture path from the skin to the FO; (E) The black solid line is the puncture needle, and the direction and position of the puncture are adjusted according to the dotted line; (F) The coincidence of the solid line and the dotted line indicates that the puncture is successful; (G,H,I): The pear-shaped structure was reconstructed after Dyna-CT scanning.

#### FUNDING:

This work was supported by the Scientific Research Innovation Program of Postgraduates in Bengbu Medical College (Byycx20098), the National Natural Science Foundation of Anhui Province (No. 1908085QH334).

#### ETHICAL APPROVAL:

This study protocol was reviewed and approved by the Ethics Committee of The Second Affiliated Hospital of Bengbu Medical College.

#### CONFLICT OF INTEREST:

The authors declared no conflict of interest.

#### AUTHORS' CONTRIBUTION:

ZC: Funding acquisition, conceptualisation, formal analysis, writing original draft.

QC: Data curation, investigation.

DDP: Image analysis, funding acquisition, writing review and editing.

#### REFERENCES

1. Mullan S, Lichtor T. Percutaneous microcompression of the trigeminal ganglion for trigeminal neuralgia. *J Neurosurg* 1983; **59**(6):1007-12. doi: 10.3171/jns.1983.59.6.1007.
2. Kefalopoulou Z, Markaki E, Constantoyannis C. Avoiding abducens nerve palsy during the percutaneous balloon compression procedure. *Stereotact Funct Neurosurg* 2009; **87**(2):101-4. doi: 10.1159/000202976.
3. Toda K. Operative treatment of trigeminal neuralgia: Review of current techniques. *Oral Surg Oral Med Oral Pathol Oral Radiol Endod* 2008; **106**(6):788-805, 805.e1-6. doi: 10.1016/j.tripleo.2008.05.033.
4. Huo X, Sun X, Zhang Z, Guo W, Guan N, Luo J. Dyna-CT-assisted percutaneous microballoon compression for trigem-

- inal neuralgia. *J Neurointerv Surg* 2014; **6(7)**:521-6. doi: 10.1136/neurintsurg-2013-010676.
5. Kaplan M, Erol FS, Ozveren MF, Topsakal C, Sam B, Tekdemir I. Review of complications due to foramen ovale puncture. *J Clin Neurosci* 2007; **14(6)**:563-8. doi: 10.1016/j.jocn.2005.11.043.
6. Xiaochuan H, Xiaoyun S, Junsheng L, Ning G, Wenshi G, Zhenxing Z. Percutaneous microballoon compression for trigeminal neuralgia using Dyna-CT. *Interv Neuroradiol* 2013; **19(3)**:359-64. doi: 10.1177/159101991301900314.

• • • • •