

# Preoperative 3D Planning and Intraoperative Navigation in Robot-Assisted Laparoscopic Surgery for Complex Pheochromocytoma

Jingyang Guo<sup>1</sup>, Deqiang Gu<sup>2</sup>, Yang Yu<sup>1</sup>, Yong Suo<sup>1</sup>, Bolun Su<sup>2</sup> and Tao Ma<sup>1</sup>

<sup>1</sup>Department of Urology, The Affiliated Hospital of Hebei University, Hebei, China

<sup>2</sup>Department of Urology, The Number 2 Hospital of Baoding, Hebei, China

## ABSTRACT

**Objective:** To evaluate the value of preoperative 3D planning and intraoperative navigation in robot-assisted laparoscopic surgery for complex pheochromocytoma.

**Study Design:** Observational study.

**Place and Duration of the Study:** Department of Urology, The Affiliated Hospital of Hebei University, from July 2022 to July 2023.

**Methodology:** Sixty patients with complex pheochromocytoma were divided into the study group (n = 30) and the control group (n = 30) according to the treatment method. The study group was treated with robot-assisted laparoscopic surgery, with preoperative 3D printing-based planning, and intraoperative 3D navigation, and the control group underwent conventional retroperitoneal robot-assisted laparoscopic surgery. Surgical-related indicators and intraoperative and postoperative complication rates between the two groups were compared.

**Results:** The operation time, postoperative hospital stay, and drainage tube retention time in the study group were significantly shorter than in the control group (p < 0.001), and the intraoperative blood loss in the study group was significantly less than in the control group (p < 0.001). The study group exhibited a significantly lower incidence of intraoperative haemodynamic instability (HI), use of vasoactive drugs, and postoperative ICU transfer rate than the control group (p < 0.05). The incidence of surgical complications in the study group was significantly lower than in the control group (p = 0.04). The non-recurrence rate in the study and control groups after 1-year follow-up was 96.7% and 90%, respectively ( $\chi^2 = 2.77$ , p = 0.10).

**Conclusion:** Robot-assisted surgery, performed through renal surface, has the advantages of less bleeding, shorter surgical time, faster recovery, fewer complications related to chromaffin cell inflammation and postoperative complications, and is safe and effective in treating complex pheochromocytoma.

**Key Words:** 3D planning and navigation, Robot-assisted surgery, Complex pheochromocytoma.

**How to cite this article:** Guo J, Gu D, Yu Y, Suo Y, Su B, Ma T. Preoperative 3D Planning and Intraoperative Navigation in Robot-Assisted Laparoscopic Surgery for Complex Pheochromocytoma. *J Coll Physicians Surg Pak* 2024; **34(10)**:1469-1473.

## INTRODUCTION

As a common neuroendocrine tumour in adrenal diseases,<sup>1</sup> pheochromocytoma (PHEO) can synthesise and store catecholamines, which can lead to symptoms such as increased blood pressure and heart rate when catecholamines are released. In particular, a large number of catecholamines can be released into the blood when stimulated by factors such as surgery irritation or anaesthesia induction, leading to life-threatening cardiovascular complications. Laparoscopic surgery is an effective treatment for pheochromocytoma.

However, controversies about the effect of laparoscopic adrenalectomy (LA) in complex adrenal tumours remain due to the malignant risks and high technical difficulties associated with complex pheochromocytomas.<sup>2</sup> Pahwa *et al.* concluded that robot-assisted laparoscopic adrenalectomy provides a clearer view and more precise controllability compared with conventional laparoscopic surgery,<sup>3</sup> especially for patients with complex resections, potentially improving their postoperative outcomes.<sup>4</sup>

Minimally invasive adrenal surgery *via* the retroperitoneal approach involves dissecting through the fat capsule surface of the adrenal gland. However, due to the deep location of the adrenal gland within the fat, freeing the fat can make it difficult to locate and manage blood vessels during surgery. Meanwhile, excessive local operation may lead to excessive hormone release due to tumour stimulation, increasing haemodynamic instability (HI) during the procedure.<sup>5</sup> Complex adrenal tumours come with significant surgical challenges due to the close proximity to the surrounding tissues, combined tissue adhe-

Correspondence to: Dr. Tao Ma, Department of Urology, Affiliated Hospital of Hebei University, Hebei, China  
E-mail: vkk743@163.com

Received: May 31, 2024; Revised: September 17, 2024;

Accepted: September 28, 2024

DOI: <https://doi.org/10.29271/jcpsp.2024.10.1469>

sions and excessive tumours, and unclear anatomical layers. In particular, for tumours adjacent to the renal hilum, the complex surrounding anatomical structures, and proximity to major blood vessels increase the risk of significant intraoperative bleeding. Liu *et al.* suggested that laparoscopic resection of large pheochromocytomas requires vigilance against haemodynamic fluctuations and carries a higher risk of intraoperative bleeding and collateral damage compared with small pheochromocytomas.<sup>6</sup> With the gradual application of emerging technology-3D printing technology in the medical field, it has been applied in surgeries for urological tumours, stones, as well as other organs such as the liver, bones, and brain. However, there have been no reports on the application of 3D printing technology in the treatment of complex pheochromocytoma. Based on this, the objective of this study was to use the 3D printing technology with robot-assisted laparoscopic surgery to treat complex pheochromocytoma and evaluate the application value of preoperative 3D planning and intraoperative navigation in complex pheochromocytoma surgery.

## METHODOLOGY

The study was a retrospective descriptive analyses of 60 patients with complex pheochromocytoma, admitted to the hospital from July 2022 to July 2023. The patients were divided into the study group ( $n = 30$ ) and the control group ( $n = 30$ ) according to the treatment method. Data of all the patients were retrieved from the hospital information and management system. Specifically, the study group was treated with robot-assisted laparoscopic surgery through the renal surface, with 3D printing technology-based preoperative planning and intraoperative 3D navigation, while the control group underwent conventional retroperitoneal robot-assisted laparoscopic surgery.

Patient aged  $\leq 70$  years with complex unilateral adrenal tumours and without coexistent cardiopulmonary and other systemic diseases, or other surgical contraindications, with normal blood pressure and heart rate, complete clinical data, agreeable to participate in the study after signing informed consent forms, and had good treatment compliance were recruited into the study.<sup>7</sup> Patients who underwent retroperitoneal surgery or contracted infectious diseases on the affected side in the past, who could not tolerate surgery, those with unstable blood pressure and heart rate, unable to cooperate with the researcher to complete the study, bilateral lesions, and those who had recently taken medicines that may affect the research results were excluded.

The patient was treated with general anaesthesia, with the retroperitoneal space established and mechanical arms and lenses placed. Firstly, the extraperitoneal fat was cleaned from the diaphragm to the iliac fossa and then the lateral conal fascia was opened near the peritoneal reflection, with the perinephric fat near the peritoneum incised directly to the surface of the parenchyma. Afterwards, blunt and sharp dissection was performed along this plane to free the kidney surface,

completely freeing the upper pole of the kidney and surrounding tissues, and the kidney was shifted posteriorly and downward to separate the upper pole of the kidney from the tumour, fully exposing the adrenal area. At this point, the adrenal tumour and surrounding fat were suspended above the kidney. The tumour and perirenal fat appeared as distinct oval cleft-like structures, and the larger the tumour, the more pronounced this cleft was due to the expansion effect. Later, the tumour's surrounding fat and perirenal fat were separated along this cleft, extending anteriorly to the peritoneum and posteriorly to the psoas muscle, with these two planes expanded and fused at the base of the tumour. At this stage, the tumour was essentially freed. If the normal adrenal tissues was minimal or indistinguishable, the adrenal gland and tumour were completely removed. If some part of the adrenal gland could be preserved, normal adrenal tissues were appropriately retained, and the tumour was excised along with a small amount of adrenal gland.

The raw radiological data of the preoperative thin-section (1mm) CT of the patient were collected and then processed using E3D modelling software to create a visual 3D imaging model containing the adrenal tumour, kidney and surrounding tissues, and blood vessels on the affected side. Afterwards, the renal vascular branching pattern and the relationship between the tumour and the renal collecting system were further identified based on the 3D imaging model, with the model printed using silicone material and stained to differentiate various tissues. Finally, a comprehensive surgical plan was developed based on the printed model, which was used for preoperative discussions and to guide the surgical procedure during the operation.

Retroperitoneal robot-assisted laparoscopic surgery was used in this study, with preoperative and intraoperative visualisation of a 3D impact model using a 3D printer for evaluation and guidance, while the control group underwent retroperitoneal robot-assisted laparoscopic adrenal surgery.

The differences in surgical time (from cleaning of extraperitoneal fat to the end of the surgery, excluding disinfection, placement of robotic arms, postoperative placement of drainage tubes, and skin suturing time), intraoperative blood loss, mobilisation time, drainage tube removal time, and hospitalisation time were compared between the two groups. The frequency of intraoperative HI, use of vasoactive agent, and postoperative ICU transfer rate (HI: blood pressure  $> 180$  mmHg or mean arterial pressure  $< 60$  mmHg) between two groups were calculated.<sup>8</sup> The differences in the postoperative complications between two groups, including adrenal crisis, arrhythmia, infection, and stress ulcers were compared. All patients were followed up for one year, and the proportion of recurrence-free patients between the two groups was compared and analysed.

SPSS 20.0 software was used for the statistical analysis of all data, and measurement data were expressed as  $(\bar{x} \pm s)$ , categorical data were expressed *via*  $n$  (%). Data analysis between the study and control groups was performed using the two-group Independent-sample t-test, and rates were compared by the  $\chi^2$  test. A  $p < 0.05$  was considered statistically significant.

**Table I: Comparative analysis of patient profile between the two groups ( $\bar{x} \pm s$ ) n = 30.**

Indicator	Study group	Control group	t/ $\chi^2$	p-value
Age	47.63 ± 18.15	46.78 ± 19.73	0.17	0.86 <sup>Δ</sup>
Left side (%)	16 (53.3%)	18 (60%)	0.27	0.60*
Duration of disease (years)	4.76 ± 1.33	5.20 ± 1.42	1.24	0.22*
Complex tumour				
>6cm (%)	29 (97%)	30 (100%)	1.02	0.31*
Adjacent to major blood vessels (%)	12 (40%)	10 (33%)	0.29	0.60*
Peritumoural adhesion (%)	6 (20%)	5 (17%)	0.11	0.74*
Obesity (%)	17 (57%)	21 (70%)	1.15	0.28*
Accompanying symptoms				
Hypertension	11 (36.7%)	13 (43.3%)	0.28	0.59*
Palpitations	5 (16.7%)	4 (13.3%)	0.13	0.72*
Low potassium	7 (23.3%)	5 (16.7%)	0.42	0.52*
Asymptomatic	7 (23.3%)	8 (26.7%)	0.09	0.77*

Note: <sup>Δ</sup>Independent-sample t-test, \* $\chi^2$  test.

**Table II: Comparative analysis of surgeries between the two groups ( $\bar{x} \pm s$ ) n = 30.**

Group	Operation time (min)	Blood loss (ml)	Off-bed activity time (d)*	Postoperative hospital stay (d)*	Drainage tube intention time (min)*
Study	18.73 ± 2.62	63.06 ± 9.37	2.32 ± 0.47	3.34 ± 0.76	18.63 ± 7.40
Control	45.76 ± 12.83	92.47 ± 12.06	2.41 ± 0.53	5.31 ± 1.64	24.72 ± 9.05
t	11.31	10.54	0.70	5.97	2.85
p <sup>Δ</sup>	<0.001	<0.001	<0.001	<0.001	<0.001

Note: <sup>Δ</sup>Independent-sample t-test.

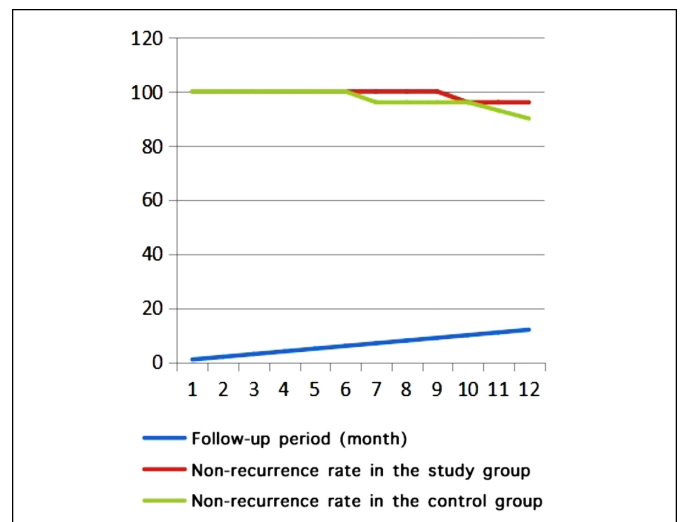
## RESULTS

Among them, the patients in the study group were aged 28 ~ 66 years, with an average of 47.63 ± 18.15 years; those in the control group were aged 32 ~ 67 years, with an average of 46.78 ± 19.73 years. There was no significant difference in the general profile between the two groups (all p >0.05), exhibiting inter-group comparability (Table I).

Comparative analysis of surgical indicators was performed between the two groups. The operation time, postoperative hospital stay, and drainage tube retention time in the study group was significantly shorter than those in the control group, with statistically significant differences (all p <0.001). Meanwhile, the intraoperative blood loss in the study group was significantly less than that in the control group, and the differences were statistically significant (p <0.001). However, the postoperative off-bed activity time was not significantly different from that of the control group (p = 0.49, Table II).

Comparative analysis of pheochromocytoma-related complications was performed between the two groups. The incidence of intraoperative HI (10% vs. 33%), the use of vasoactive drugs (3% vs. 20%), and the postoperative ICU transfer rate (3% vs. 23%) in the study group were significantly lower than those in the control group, with statistically significant differences ( $\chi^2 = 4.81$  p = 0.03,  $\chi^2 = 4.04$  p = 0.04,  $\chi^2 = 5.19$ , p = 0.02).

Comparative analysis of the incidence of surgical complications was performed between the two groups. The incidence of surgical complications in the former was significantly lower than that of the latter, and the differences were statistically significant (7% vs. 27%,  $\chi^2 = 4.32$ , p = 0.04).



**Figure 1: Comparative analysis of the non-recurrence rate in the two groups.**

Comparative analysis of follow-up indicators was performed between the two groups. Patients in both groups were followed up for 1 year after the operation, no significant differences were observed in the non-recurrence rate between the two groups ( $\chi^2 = 2.77$ , p = 0.10, Figure 1).

## DISCUSSION

Pheochromocytoma is a rare neuroendocrine tumour with an incidence rate of 0.1% in the whole population.<sup>9</sup> Surgery is the main treatment method, but due to the instability of intraoperative haemodynamics, the risk of fatal complications still exists.<sup>10</sup> Therefore, minimally invasive surgery for the removal of large pheochromocytoma is a challenging procedure.<sup>11</sup> With the development of laparoscopy and robotic systems, minimally invasive surgery has made significant

progress in adrenal gland treatment.<sup>12</sup> Laparoscopic adrenal surgery has minimal interference with abdominal organs and fast postoperative recovery. Rah *et al.* concluded that the depth of the adrenal tumour location from the skin is an independent predictor of surgical time,<sup>13</sup> but due to the adrenal gland being located within the fat of the upper pole of the kidney, local fat accumulation may lead to visualisation and surgical difficulties, resulting in prolonged surgical time. In addition, excessive local stimulation and compression can increase the release of catecholamines into the bloodstream, further exacerbating HI.<sup>14,15</sup>

The 3D printing technology is a rapidly developing rapid prototyping technology.<sup>16</sup> The application of 3D printing technology can reconstruct and print adrenal models before surgery, which helps to determine the resection range of the adrenal gland before surgery, measure the volume of the adrenal gland before and after surgery, and thus more accurately preserve blood supply and normal adrenal tissue.<sup>17,18</sup> The results of this study showed that the study group compared with the control group, had significantly shorter surgical time, postoperative hospitalisation time, and drainage tube retention time, and the difference was statistically significant ( $p < 0.001$ ). In addition, the intraoperative bleeding in the study group was significantly less than that in the control group, and the difference was statistically significant ( $p < 0.001$ ). The angiogenesis of pheochromocytoma is extremely active, and some of them have vascular course and morphological abnormalities. The 3D printing technology can predict the course of nourishing blood vessels and possible vascular damage caused by vascular variations in pheochromocytoma and paraganglioma in advance, reduce intraoperative bleeding, shorten surgical time, and reduce drainage tube retention time and patient hospitalisation time.<sup>19,20</sup>

Research has shown that during surgery for large adrenal tumours, one or more complications often occur,<sup>21</sup> including hypertensive crisis and HI, which can be life-threatening.<sup>22</sup> Intraoperative haemodynamic fluctuations are an independent risk factor for surgical complications in pheochromocytoma, and are closely related to higher ICU occupancy rates. In this study, the incidence of HI, use of vasoactive drugs, postoperative ICU transfer rate, and incidence of complications in the research group were significantly lower than those in the control group ( $p < 0.05$ ). This is because the 3D digital model constructs a visualised 3D image model from the patient's imaging data.<sup>23</sup> Preoperative doctors can clearly determine the location, depth, blood supply, etc. of the tumour, and develop detailed surgical plans to improve surgical results. Combined with intraoperative navigation, it can enhance precise control of specific tumour conditions, reduce unnecessary tumour compression during surgery, reduce HI and complications, and increase surgical safety. In addition, there was no significant difference in the recurrence rate between the two groups of patients who were followed up for 1 year after surgery ( $p > 0.05$ ), indicating that the use of robot-assisted laparoscopic surgery for preop-

erative 3D planning and intraoperative navigation treatment of complex pheochromocytoma can also remove the tumour completely.

However, this study also comes with the limitations of a small sample size and the lack of analysis of the changes in hormone levels in patients before and after intraoperative tumour treatment. In the future, the sample size should be accumulated, along with the comparison of hormone level changes before and after tumour treatment to provide a more detailed and objective evaluation of the pros and cons of this treatment regimen, thereby benefiting more patients. Additionally, due to the higher cost of hospitalisation using robot-assisted surgery and 3D technology compared with conventional surgery, medical centres should select appropriately based on the financial conditions of the patients.

## CONCLUSION

Preoperative 3D planning and intraoperative navigation using robot-assisted laparoscopic surgery on the renal surface have advantages in treating complex pheochromocytoma, such as less bleeding, shorter surgical time, faster recovery, and fewer complications.

### FUNDING:

The study is supported by Hebei University Campus Youth Fund (No. 2022QC37).

### ETHICAL APPROVAL:

The study was approved by the Ethics Committee of the Hospital (Approval No.: HDFYLL-KY-2023-010).

### PATIENTS' CONSENT:

Written consent was taken from the patients before the initiation of the study.

### COMPETING INTEREST:

The authors declared no conflict of interest.

### AUTHORS' CONTRIBUTION:

JG, TM: Concept, study design, conduction of study, and manuscript writing.

DG, YS: Data collection, analysis, and manuscript writing.

YY, BS: Revision of the manuscript.

All authors approved the final version of the manuscript to be published.

## REFERENCES

1. Shiraishi K, Kitahara S, Ito H, Oba K, Ohmi C, Matsuyama H. Transperitoneal versus retroperitoneal laparoscopic adrenalectomy for large pheochromocytoma: Comparative outcomes. *Int J Urol* 2019; **26(2)**:212-6. doi: 10.1111/iju.13838.
2. Prakobpon T, Santi-Ngamkun A, Usawachintachit M, Ratchanon S, Sowanthip D, Panumatrassamee K. Laparoscopic transperitoneal adrenalectomy in the large adrenal tumour from single center experience. *BMC Surg* 2021; **21(1)**:68. doi: 10.1186/s12893-021-01080-y.

3. Pahwa M. Robot-assisted adrenalectomy: Current perspectives. *Robot Surg* 2017; **4**:1-6. doi: 10.2147/RSR-R.S100887.
4. Wake N, Nussbaum JE, Elias MI, Nikas CV, Bjurlin MA. 3D Printing, Augmented Reality, and virtual reality for the assessment and management of kidney and prostate cancer: A systematic review. *Urology* 2020; **143**:20-32. doi: 10.1016/j.urology.2020.03.066.
5. Uludag M, Aygun N, Isgor A. Surgical indications and techniques for adrenalectomy. *Sisli Etfal Hastan Tip Bul* 2020; **54**(1):8-22. doi: 10.14744/SEMB.2019.05578.
6. Liu H, Li B, Yu X, Huang Y. Perioperative management during laparoscopic resection of large pheochromocytomas: A single-institution retrospective study. *J Surg Oncol* 2018; **118**(4):709-15. doi: 10.1002/jso.25205.
7. Huang K, Wang Y, Gu X, Xiao Q, Tu X. Retroperitoneal laparoscopic surgery in the treatment of complex adrenal tumours. *Cancer Manag Res* 2020; **12**:5787-91. doi: 10.2147/CMAR.S257310.
8. Bianchi L, Barbaresi U, Cercenelli L, Bortolani B, Gaudiano C, Chessa F, et al. The impact of 3d digital reconstruction on the surgical planning of partial nephrectomy: A case control study. still time for a novel surgical trend? *Clin Genitourin Cancer* 2020; **18**(6):e669-78. doi: 10.1016/j.clgc.2020.03.016.
9. Inversini D, Manfredini L, Galli F, Zhang D, Dionigi G, Rausei S. Risk factors for complications after robotic adrenalectomy: A review. *Gland Surg* 2020; **9**(3):826-30. doi: 10.21037/gs.2020.04.10.
10. Hyde ER, Berger LU, Ramachandran N, Hughes-Hallett A, Pavithran NP, Tran MGB, et al. Interactive virtual 3D models of renal cancer patient anatomies alter partial nephrectomy surgical planning decisions and increase surgeon confidence compared to volume-rendered images. *Int J Comput Assist Radiol Surg* 2019; **14**(4):723-32. doi: 10.1007/s11548-019-01913-5.
11. Fajardo R, Garcia N, Diaz F. Transperitoneal laparoscopic adrenalectomy for the resection of large size pheochromocytoma: Case report and literature review. *Int J Surg Case Rep* 2020; **71**:353-9. doi: 10.1016/j.ijscr.2020.05.027.
12. Bihain F, Klein M, Nomine-Criqui C, Brunaud L. Robotic adrenalectomy in patients with pheochromocytoma: A systematic review. *Gland Surg* 2020; **9**(3):844-8. doi: 10.21037/gs-2019-ra-05.
13. Rah CS, Kim WW, Lee YM, Chung KW, Koh JM, Lee SH, et al. New predictive factors for prolonged operation time of laparoscopic posterior retroperitoneal adrenalectomy; retrospective cohort study. *Int J Surg* 2021; **94**:106113. doi: 10.1016/j.ijisu.2021.106113.
14. Huang YS, Yan L, Li ZY, Fang ZQ, Liu Z, Xu ZH, et al. Risk factors for hemodynamic instability during laparoscopic resection of pheochromocytoma. *BMC Urol* 2022; **22**(1):158. doi: 10.1186/s12894-022-01109-1.
15. Fagundes GFC, Almeida MQ. Perioperative management of pheochromocytomas and sympathetic paragangliomas. *J Endocr Soc* 2022; **6**(2):bvac004. doi: 10.1210/jendso/bvac004.
16. Alesina PF, Walz MK. Adrenal tumours: Are gender aspects relevant? *Visc Med* 2020; **36**(1):15-9. doi: 10.1159/000505788.
17. Mete O, Erickson LA, Juhlin CC, de Krijger RR, Sasano H, Volante M, et al. Overview of the 2022 WHO classification of adrenal cortical tumours. *Endocr Pathol* 2022; **33**(1):155-96. doi: 10.1007/s12022-022-09710-8.
18. Shalaby H, Abdelgawad M, Omar Md M, Zora Md G, Alawwad S, Alameer E, et al. Robotic and laparoscopic approaches for adrenal surgery in obese patients. *Am Surg* 2021; **87**(4):588-94. doi: 10.1177/0003134820951498.
19. Amparore D, Pecoraro A, Piramide F, Verri P, Checcucci E, De Cillis S, et al. Three-dimensional imaging reconstruction of the kidney's anatomy for a tailored minimally invasive partial nephrectomy: A pilot study. *Asian J Urol* 2022; **9**(3):263-71. doi: 10.1016/j.ajur.2022.06.003.
20. Mercader C, Vilaseca A, Moreno JL, Lopez A, Sebastia MC, Nicolau C, et al. Role of the three-dimensional printing technology in complex laparoscopic renal surgery: A renal tumour in a horseshoe kidney. *Int Braz J Urol* 2019; **45**(6):1129-35. doi: 10.1590/S1677-5538.IBJU.2019.0085.
21. Araujo-Castro M, Garcia Centeno R, Lopez-Garcia MC, Lamas C, Alvarez-Escuela C, Calatayud Gutiérrez M, et al. Risk factors for intraoperative complications in pheochromocytomas. *Endocr Relat Cancer* 2021; **28**(11):695-703. doi: 10.1530/ERC-21-0230.
22. Bai S, Yao Z, Zhu X, Li Z, Jiang Y, Wang R, et al. Comparison of transperitoneal laparoscopic versus open adrenalectomy for large pheochromocytoma: A retrospective propensity score-matched cohort study. *Int J Surg* 2019; **61**:26-32. doi: 10.1016/j.ijisu.2018.11.018.
23. Krokker L, Szabo B, Nemeth K, Tohati R, Sarkadi B, Meszaros K, et al. Three dimensional cell culturing for modeling adrenal and pituitary tumours. *Pathol Oncol Res* 2021; **27**:640676. doi: 10.3389/pore.2021.640676.z.

••••••••••