

Spontaneous Closure of Bile Leak in Abdominal Drain after Cholecystectomy: A Systematic Review

Muhammad Tahir Ghani¹, Hafiz Muhammad Ijaz Ul Haq², Ibad Ur Rehman³ and Nain Sukh⁴

¹Department of Surgery, Aero Hospital, Hassan Abdal, Pakistan

²Department of Surgery, Torbay Hospital, Torquay, United Kingdom

³Department of Surgery, Akbar Niazi Teaching Hospital, Islamabad, Pakistan

⁴Department of Surgery, HITEC Medical College, Taxila Cantt, Pakistan

ABSTRACT

Bile leakage in abdominal drain after cholecystectomy is reported to close spontaneously without any intervention. The aim of this systematic review was to find out the amount and source of bile leaks that can be closed spontaneously and various factors associated with this closure. A systematic search of PubMed, Google Scholar, and Cochrane under preferred reporting items for systematic reviews and meta-analyses (PRISMA) guidelines was performed. Ten studies were finally included in the review. Five studies were found from India, two from Pakistan, and one each from Mexico, Nepal, and Romania. Maximum volume of bile reported to close spontaneously was 500 ml per day and took seven days to close. Overall 66.6% cases of bile leaks were laparoscopically operated. Bile leakage in abdominal drain after cholecystectomy up to 500 ml per day closes spontaneously in a week time provided patient has no major ductal injury and peritonitis.

Key Words: Bile leakage, Abdominal drain, Endoscopic retrograde cholangiopancreatography.

How to cite this article: Ghani MT, Haq HMIU, Rehman IU, Sukh N. Spontaneous Closure of Bile Leak in Abdominal Drain after Cholecystectomy: A Systematic Review. *J Coll Physicians Surg Pak* 2024; **34(09)**:1084-1089.

INTRODUCTION

Bile leakage after cholecystectomy is a serious complication and carries significant morbidity and mortality.¹⁻³ It may be seen after simple or difficult cholecystectomy and both after laparoscopic or open cholecystectomy.^{1,4} However, bile leakage is reported more after difficult and laparoscopic cholecystectomy.^{4,7} Postoperative bile leakage can be caused by unrecognised injury to extra hepatic biliary tree during surgery, leakage from cystic duct stump, leakage from gallbladder remnant after partial cholecystectomy, leakage from accessory duct or liver bed.^{1,8} Most common presentation of postoperative bile leakage is biliary peritonitis and biloma formation.^{5,7} Pain abdomen and fever are predominant symptoms however patient may have jaundice, vomiting, and tachypnoea depending upon the nature of injury and septic load.^{2,9} Treatment in modern era is minimally invasive starting from percutaneous aspiration of biloma under ultrasound or CT guidance and drain placement. This is followed by magnetic resonance cholangiopancreatography (MRCP) to find out the site of bile leak and if necessary endoscopic retrograde cholangiopancreatography (ERCP).^{10,11}

ERCP has revolutionised the treatment of postoperative biliary leakage and open surgery is seldom carried out which carries significant morbidity and mortality. In majority of cases, ERCP and stent insertion with or without sphincterotomy is the definite treatment.^{11,12}

There is another group of patients who present with bile leakage in abdominal drain which was inserted during cholecystectomy. Although routine drain placement after cholecystectomy is not recommended and many studies suggest that routine drain placement after cholecystectomy is associated with more complications and prolongs hospital stay.¹³⁻¹⁵ However, during difficult cholecystectomy when extensive dissection is carried out, surgeons still use subhepatic drains to avoid intra-abdominal collection of bile or blood.¹⁶ Patients who present with bile leakage in abdominal drain, may not have any abdominal symptoms as drain serves as controlled biliary fistula. Many studies suggest that bile leakage in these cases stops spontaneously over time provided that there is no major injury to the extra hepatic biliary tree.^{6,17} Such patients in developed world are again treated by ERCP and stenting which reduces pressure gradient between common bile duct and duodenum and fastens the recovery.^{12,18}

This spontaneous closure of bile leak in abdominal drain is a blessing in disguise in poor resources, underdeveloped countries where ERCP facilities are not readily available and are costly as well.¹⁹ However, there are no strict guidelines available on the amount and nature of bile leakage that can be expected to close spontaneously. The aim of this systematic

Correspondence to: Dr. Muhammad Tahir Ghani, Department of Surgery, Aero Hospital, Wah Cantt, Pakistan
E-mail: doctortahir226@gmail.com

Received: October 02, 2023; Revised: February 18, 2024;

Accepted: May 12, 2024

DOI: <https://doi.org/10.29271/jcpcsp.2024.09.1084>

review was to find out the amount and source of bile leakage that can be managed conservatively and expected to close spontaneously in abdominal drain after cholecystectomy. Also, various factors associated with the success of conservative treatment will be explored. This review will help surgeons in developing the word to confidently wait for bile leak to close spontaneously where ERCP facilities are not readily available.

METHODOLOGY

This systematic review was conducted as per preferred reporting items for systematic reviews and meta-analyses (PRISMA) guidelines.²⁰ PubMed, Google Scholar, and Cochrane databases were searched between 15th and 30th January 2023. Following keywords including bile leak, biliary leak, abdominal drain, cholecystectomy, difficult cholecystectomy, and subtotal cholecystectomy were searched for in each database (Figure 1). First two authors separately searched and screened the studies and no conflict was noted during the research process. All retrospective, prospective studies, clinical trials, case reports, and randomised clinical trials were included. Only studies with free full-text and English language were selected. All cases of cholecystectomies, whether open or laparoscopic or lap converted to open, performed electively or in an emergency after which bile leakage was observed in abdominal drain after cholecystectomy were included in the study. Those cases in which abdominal drain was inserted after aspiration of biloma under ultrasound or CT guidance were also included in the study. All those cases were selected in which bile leakage stopped spontaneously without any intervention. Corresponding authors of the studies, where additional information was needed, were contacted through E-mail or telephone. Only those studies were included in which bile volume and duration of stopping of bile were clearly mentioned and information was received from corresponding author. All cases where extrahepatic biliary tree was damaged peroperatively were excluded. The cases in which ERCP was performed to treat bile leak were excluded as well. Studies in which volume and duration of bile from drainage until stoppage were not clearly mentioned were excluded as well.

RESULTS

Ten studies met the inclusion criteria to be included in this systematic review. Five studies from India, two from Pakistan, and one each from Mexico, Nepal, and Romania were found. Four retrospective observational, four prospective, and two case reports were included (Table I). Most recent spontaneous closure of bile was reported in a case report from Mexico in 2022 while the oldest study was conducted in Romania in 2003. Maximum volume of bile reported to close spontaneously was 500 ml and took 7 days to close. Maximum time duration for bile leak to close was 4-34 days (range) and was noted in a study conducted by Pandit *et al.* in Nepal in six patients.⁶ All these patients presented with biloma formation and it was drained percutaneously and drain placed. Asif *et al.* from India mentioned that the maximum time duration for bile to close was 18 days in abdominal drain.²¹ Six studies mentioned the percentages of laparoscopic or open cholecystectomies in patients with

bile leaks. These percentages when combined, showed that overall 66.6% cases of bile leaks were laparoscopically operated while 33.4% were operated for open cholecystectomies (Table II). Four studies showed more cases of bile leaks that were laparoscopically operated than open while two studies had more leaks in the open cholecystectomy group than laparoscopic.

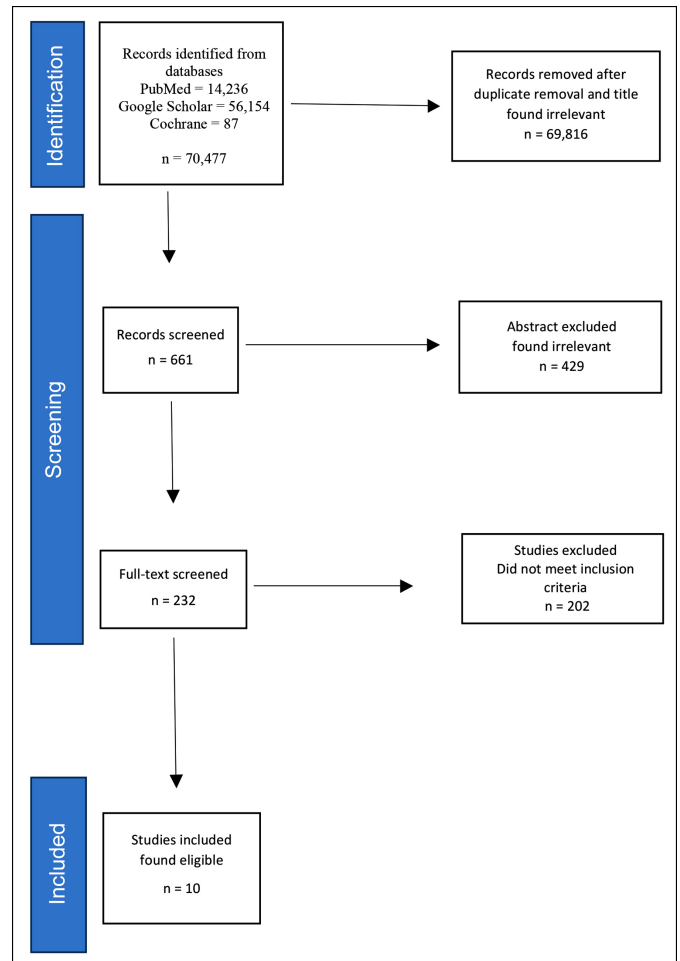


Figure 1: Prisma flow diagram.

DISCUSSION

Bile leak in abdominal drain after cholecystectomy is a serious complication and has many potential causes.^{7,8,10} It may be because of unrecognised injury to biliary tree during surgery or may be because of thermal injury to biliary tree that may present after a few days of cholecystectomy.^{10,29} Other common causes include leakage from cystic duct stump, leakage from accessory duct, leakage from gallbladder remnant after partial cholecystectomy or leakage from liver bed.^{1,8,30} Such patients may not have sign and symptoms of biliary peritonitis and the only presenting complaint is bile in abdominal drain. In developed countries where modern endoscopic facilities are readily available, treatment of such patients is ERCP and stent insertion after localisation of the site of biliary injury by MRCP.^{10,11,18} ERCP reduces pressure gradient between CBD and duodenum and lessens the bile drain and recovery is early.^{7,18}

Table I: Summary of the included studies.

Study authors	Country	Year of publication	Type of study	No. of total bile leaks	Leaks closed spont.	Max. vol. closed spont.	Max. days to close	Lap. chole	Open chole/ converted
Asif <i>et al.</i> ²¹	India	2018	Prospective	07	07	120ml	18	140	80
Ahmed <i>et al.</i> ²²	Pakistan	2020	Retrospective	05	04	400ml	14	48	0
Chatterjee <i>et al.</i> ²³	India	2013	Case report	02	01	200ml	09	02	Nil
Duka <i>et al.</i> ²⁴	Romania	2003	Retrospective	34	19	300ml	10	9,542	184
Goswami <i>et al.</i> ²⁵	India	2017	Prospective	20	10	500ml	07	405	785
Hadi <i>et al.</i> ²⁶	Pakistan	2016	Prospective	4	4	<300ml	05	101	09
Kishore <i>et al.</i> ¹⁷	India	2016	Retrospective	25	7	<500ml	07	146	195
Pandit <i>et al.</i> ⁶	Nepal	2020	Retrospective	18	7	200ml	(4 - 34) days mean 11 days	15	03
Roy <i>et al.</i> ²⁷	India	2020	Prospective	110	70	≥100 ml	07	1436	49
Saveedra <i>et al.</i> ²⁸	Mexico	2022	Case report	01	01	<200 ml	05	01	-

NR: Not reported, Spont: Spontaneously, Vol: Volume.

Table II: Summary of the studies included.

Study authors	No. and percentage leak lap chole	No. and percentage leak open chole	Type of surgery
Asif <i>et al.</i> ²¹	5 (3.57%)	2 (2.5%)	Lap and open cholecystectomies
Ahmed <i>et al.</i> ²²	5 (10.4%)	Not done	Lap partial cholecystectomy
Chatterjee <i>et al.</i> ²³	01	Nil	Lap cholecystectomy
Duka <i>et al.</i> ²⁴	17 (0.17%)	2 (1.08%)	Lap and open cholecystectomies
Goswami <i>et al.</i> ²⁵	7 (35%)	13 (65%)	Lap and open cholecystectomies
Hadi <i>et al.</i> ²⁶	NM	NM	Lap and open cholecystectomies
Kishore <i>et al.</i> ¹⁷	7 (4.8%)	18 (9.2%)	Lap and open cholecystectomies
Pandit <i>et al.</i> ⁶	83.3%	16.7%	Lap and open cholecystectomies
Roy <i>et al.</i> ²⁷	76.19%	9.52%	Laparoscopic and open cholecystectomies
Saveedra <i>et al.</i> ²⁸	01	Nil	Subtotal cholecystectomy

Chole: Cholecystectomy, NM: Not mentioned, NA: Not applicable.

Although modern diagnostic and therapeutic facilities such as MRCP and ERCP localise the site of the bile leak and help in early closure of leak respectively, many studies suggest that such bile leaks in abdominal drain close spontaneously without any intervention.^{22-25,31-33}

The facilities of ERCP have improved in developing countries as well but still, they are not widely available and are costly as well.^{19,31} Ten studies were found in which the patients with post-cholecystectomy bile leak were managed conservatively with wait and see policy with abdominal drains without any intervention. Out of the ten studies, five were from India, two from Pakistan, and one was from Nepal, which are poor resource third-world countries and facilities of ERCP in the countries are limited and costly. Only one study each from Romania and Mexico were included. Pandit *et al.* in his study conducted in Nepal, has mentioned that those patients who were managed conservatively with drain were offered ERCP at far distant centres which were costly but they refused to travel and afford the expenses.⁶ Chatterjee *et al.*'s study conducted in India also reported that the patient refused to go for ERCP due to financial issues and opted to wait for controlled biliary fistula to close.²³

The amount of bile that can be closed spontaneously is a matter of debate. In a study conducted by Goswami *et al.* in India, 14 out of 20 patients with post-cholecystectomy bile

leak were managed without any intervention with controlled external biliary fistula.²⁵ In this study, maximum amount of 500 ml bile per day was found to close spontaneously and it took 7 days to close. In another study conducted by Kishore *et al.* in India, 56% patients with postcholecystectomy bile leaks were managed without any intervention with simple abdominal drains and a maximum of 500 ml daily output of bile in abdominal drain was recorded and took 7 days to close.¹⁷

The bile that closes spontaneously either leaks from cystic duct stump, small accessory duct, liver bed, and other smaller source.^{6,26,27} Major ductal injuries that go unrecognised during surgery and present as bile in abdominal drain are seldom closed with conservative means and require intervention in the form of ERCP, stenting after confirming the site of biliary injury by MRCP. Kishore *et al.* mentioned that six drains that continued to drain bile beyond 2 weeks showed ductal injuries on ERCP later.¹⁷ The maximum time for bile to close spontaneously was found in a study conducted by Pandit *et al.*, in which the maximum time reported for biliary fistula to close is 4-34 days (range) with a mean of 11 days.⁶ The patients where biloma aspiration was performed and drains were placed percutaneously, took longer to close than the patients where drains were placed peroperatively. Asif *et al.* in India, reported that the maximum time for bile to close was 18 days in one patient.²¹ However, if bile leakage

continues in abdominal drain beyond 2 weeks without significant reduction in volume, major ductal injury should be suspected and MRCP followed by ERCP should be performed to diagnose and treat the injury.

This review revealed that the incidence of bile leakage after cholecystectomy was collectively more common after laparoscopic than open cholecystectomy. Overall 66.6% cases of bile leaks were laparoscopically operated while 33.4% were operated as open cholecystectomy. However, few studies showed that the bile leakage was more common after the open cholecystectomy than laparoscopic. Study conducted by Kishore *et al.* in India showed that more cases of bile leaks were operated by open than laparoscopic (9.2% >4.8%) means.¹⁷ In a study conducted by Pandit *et al.*, out of 18 cases of bile leaks, 15 (83.7%) were found to be operated laparoscopically.⁶ Goswami *et al.* in his study reported 20 cases of bile leaks in which 7 (35%) were operated laparoscopically while 65% cases were operated as open cholecystectomy.²⁵ In a study conducted by Asif *et al.* in India, the incidence of bile leak in laparoscopic and open cholecystectomy did not show statistically significant difference (3.5% vs. 2.5%).²¹ Patients who presented with biloma formation after cholecystectomy were treated initially by percutaneous drainage under ultrasound or CT guidance and drain placement as well.³⁴ Such patients may not need ERCP or any other intervention later, if they develop low output controlled biliary fistula which will close spontaneously. In the study conducted by Pandit *et al.*, six patients presented with biloma formation postcholecystectomy who were managed by percutaneous aspiration of biloma and drain placement.⁶ All six patients settled with drain as they had low output fistula which closed in a week time and none required the ERCP or any other intervention. If conservative management of biliary leakage is planned, it is important that the common bile duct is distally clear of stones or any obstruction and bile flows freely in the duodenum. MRCP is non-invasive diagnostic modality to clearly define the nature of injury to biliary tree and to detect stones in bile duct.^{32,33} In developing countries, occasionally clinicians have to rely on basic clinical findings and cheaper investigations, such as abdominal ultrasound and liver function tests to confirm biliary tree status.¹⁹

Routine drain placement after cholecystectomy is no longer recommended.¹³⁻¹⁵ Studies suggest that surgeons still prefer subhepatic drain placement after difficult cholecystectomy when there is extensive dissection and adhesiolysis carried out during the surgery, although evidence to support drain placement is lacking.^{35,36} Asif *et al.* placed abdominal drains in all patients undergoing difficult cholecystectomy as a routine protocol in their hospital.²¹ In difficult situations when Calot's triangle dissection is not possible, surgeons have to perform subtotal or partial cholecystectomy which

is associated with more complications including post-operative bile leak and the surgeons prefer to place drain in gallbladder fossa after surgery.^{37,38}

CONCLUSION

Bile leakage in abdominal drain after cholecystectomy can close spontaneously without any intervention provided patient has no major ductal injury, no peritonitis, and the CBD is distally clear. Bile leakage up to 500 ml per day may serve as controlled biliary fistula and closes in a week's time in the absence of above mentioned conditions.

COMPETING INTEREST:

The authors declared no conflict of interest.

AUTHORS' CONTRIBUTION:

MTG: Conceptualisation of the study, data search and analysis, and writing of the manuscript.

IUH: Data search and analysis and critical revision of the manuscript.

IUR: Manuscript revision, editing, and finalising the manuscript.

NS: Editing and proofreading.

All authors approved the final version of the manuscript to be published.

REFERENCES

- Gustafsson A, Enochsson L, Tingstedt B, Olsson G. Bile leakage and the number of metal clips on the cystic duct during laparoscopic cholecystectomy. *Scand J Surg* 2022; **111(2)**:14574969221102284. doi: 10.1177/14574969221102284.
- Ahmad DS, Faulx A. Management of postcholecystectomy biliary complications: A narrative review. *Am J Gastroenterol* 2020; **115(8)**:1191-8. doi: 10.14309/ajg.0000000000000704.
- Fong ZV, Pitt HA, Strasberg SM, Loehrer AP, Sicklick JK, Talamini MA, *et al.* Diminished survival in patients with bile leak and ductal injury: Management strategy and outcomes. *J Am Coll Surg* 2018; **226(4)**:568-76. doi: 10.1016/j.jamcollsurg.2017.12.023.
- Ljubicic N, Biscanin A, Pavic T, Nikolic M, Budimir I, Mijic A, *et al.* Biliary leakage after urgent cholecystectomy: Optimization of endoscopic treatment. *World J Gastro-intest Endosc* 2015; **7(5)**:547-54. doi: 10.4253/wjge.v7.i5.547.
- Kohga A, Suzuki K, Okumura T, Yamashita K, Isogaki J, Kawabe A, *et al.* Risk factors for postoperative bile leak in patients who underwent subtotal cholecystectomy. *Surg Endosc* 2020; **34(11)**:5092-7. doi: 10.1007/s00464-019-07309-5.
- Pandit N, Yadav TN, Awale L, Deo KB, Dhakal Y, Adhikary S. Current scenario of postcholecystectomy bile leak and bile duct injury at a tertiary care referral centre of Nepal. *Minim Invasive Surg* 2020; **2020**:4382307. doi: 10.1155/2020/4382307.

7. Gawlik C, Carneval M. A review of the management of bile leaks. *Cureus* 2021; **13(5)**:e14937. doi: 10.7759/cureus.14937.
8. Hassan AM, Mohammed, Qasemb A. Biliary leak after laparoscopic cholecystectomy: Incidence and management. *Egypt J Hosp Med* 2021; **40(2)**:685-94. doi: 10.4103/ejs.ejs_62_21.
9. Haidar H, Manasa E, Yassin K, Suissa A, Kluger Y, Khamaysi I. Endoscopic treatment of post-cholecystectomy bile leaks: A tertiary center experience. *Surg Endosc* 2021; **35(3)**: 1088-92. doi: 10.1007/s00464-020-07472-0.
10. Kim KH, Kim TN. Endoscopic management of bile leakage after cholecystectomy: A single-center experience for 12 years. *Clin Endosc* 2014; **47(3)**:248-53. doi: 10.5946/ce.2014.47.3.248.
11. Rio-Tinto R, Canena J. Endoscopic treatment of post-cholecystectomy biliary leaks. *GE Port J Gastroenterol* 2021; **28(4)**:265-73. doi: 10.1159/000511527.
12. Yachimski P, Orr JK, Gamboa A. Endoscopic plastic stent therapy for bile leaks following total vs. subtotal cholecystectomy. *Endosc Int Open* 2020; **8(12)**:1895-9. doi: 10.1055/a-1300-1319.
13. Picchio M, De Cesare A, Di Filippo A, Spaziani M, Spaziani E. Prophylactic drainage after laparoscopic cholecystectomy for acute cholecystitis: A systematic review and meta-analysis. *Updates Surg* 2019; **71(2)**:247-54. doi: 10.1007/s13304-019-00648-x.
14. Valappil MV, Gulati S, Chhabra M, Mandal A, Bakshi S, Bhattacharyya A, et al. Drain in laparoscopic cholecystectomy in acute calculous cholecystitis: A randomised controlled study. *Postgrad Med J* 2020; **96(1140)**:606-9. doi: 10.1136/postgradmedj-2019-136828.
15. Xu M, Tao YL. Drainage versus no drainage after laparoscopic cholecystectomy for acute cholecystitis: A meta-analysis. *Am Surg* 2019; **85(1)**:86-91.
16. Bawahab MA, Abd El Maksoud WM, Alsareii SA, Al Amri FS, Ali HF, Nimeri AR, et al. Drainage vs. non-drainage after cholecystectomy for acute cholecystitis: A retrospective study. *J Biomed Res* 2014; **28(3)**:240-5. doi: 10.7555/JBR.28.2013.0095.
17. Kishore PK, Sruthi BM, Obulesu G. Study of post cholecystectomy biliary leakage and its management. *Int Arch Integr Med* 2016; **3(9)**:222-7. Available from: http://iaimjournal.com/wp-content/uploads/2016/08/iaim_2016_0309_32.pdf.
18. Di Lascia A, Tartaglia N, Fersini A, Petruzzelli F, Ambrosi A. Endoscopy for treating minor post-cholecystectomy biliary fistula A review of the literature. *Ann Ital Chir* 2018; **89**: 270-7.
19. Talukdar R, Nageshwar Reddy D. ERCP in developing countries: The way forward. *Gastrointest Endosc* 2016; **84(4)**: 667-9. doi: 10.1016/j.gie.2016.04.037.
20. Paje MJ, McKenzie JE, Bossuyt PM, Boutron I, Hoffmann TC, Mulrow CD, et al. The PRISMA 2020 statement: An updated guideline for reporting systematic reviews. *BMJ* 2021; **29(3)**:371-2. doi: 10.1136/bmj.n71.
21. Asif S, Yadav SPS, Thair S, Singh AA, Rai S, Singh S, et al. Comparison of biliary leakage in laparoscopic and open cholecystectomy. *J Evol Med Dent Sci* 2018; **7(18)**: 2274-80. doi: 10.14260/jemds/2018/511.
22. Ahmed N. Clinical outcome of laparoscopic partial cholecystectomy: Experience in a tertiary care hospital setting. *J Med Sci* 2020; **28(4)**:327-30. doi: 10.52764/jms.20.28.4.4.
23. Chatterjee C, Khan D, De U. Cystic duct stump leak: A report of two cases. *J Surg Pak* 2013; **18(1)**:48-50.
24. Duca S, Bala O, Al-Hajjar N, Lancu C, Puia IC, Munteanu D, et al. Laparoscopic cholecystectomy: Incidents and complications. A retrospective analysis of 9542 consecutive laparoscopic operations. *HPB (Oxford)* 2003; **5(3)**:152-8. doi: 10.1080/13651820310015293.
25. Goswami A, Gogoi M, Rahman MA. A study on biliary leakage after cholecystectomy. *Int J Contemp Med Res* 2017; **4(5)**:1212-5. Available from: http://www.ijcmr.com/uploads/7/7/4/6/77464738/ijcmr_1482_jun_20.pdf.
26. Hadi A, Shah F, Qureshi H, Muhammad S. Postoperative outcome of early laparoscopic and open cholecystectomy for acute calculous cholecystitis. *J Surg Pak* 2016; **21(2)**: 49-53. doi: 10.21699/jsp.21.2.3.
27. Roy AK, Das NN, Deka UJ. Management of postcholecystectomy biliary leakage: Five-year experience of a tertiary centre in Northeast India. *Saudi Surg J* 2020; **8(1)**:15. doi: 10.4103/ssj_39_20.
28. Saavedra GC, Segovia DR, Centeno RH, Perez NJF. Laparoscopic subtotal reconstituting cholecystectomy in type II & III Mirizzi syndrome: Case series of 5 patients. *Int J Surg Case Rep* 2022; **97**:107425. doi: 10.1016/j.ijscr.2022.107425.
29. Abdelgawad MS, Eid M, Abokoura S, Elmazaly MA, Aly RA. Iatrogenic bile duct injuries after laparoscopic cholecystectomy: Evaluation by MRCP before management. *Egypt Liver J* 2023; **13(1)**:2. doi: 10.1186/s43066-023-00238-y.
30. Nassar AHM, Ng HJ. Risk identification and technical modifications reduce the incidence of postcholecystectomy bile leakage: Analysis of 5675 laparoscopic cholecystectomies. *Langenbecks Arch Surg* 2022; **407(1)**:213-23. doi: 10.1007/s00423-021-02264-z.
31. Abbas A, Sethi S, Brady P, Taunk P. Endoscopic management of postcholecystectomy biliary leak: When and how? A nationwide study. *Gastrointest Endosc* 2019; **(2)**:233-41.e1. doi: 10.1016/j.gie.2019.03.1173.
32. Taghavi A, Azizi M, Rasekhi A, Gholami Z. Anatomic variations of the cystic duct in magnetic resonance cholangiopancreatography in Shiraz: A cross-sectional study. *Iran J Med Sci* 2022; **47(1)**:48-52. doi: 10.30476/IJMS.2021.88447.1918.
33. Angileri SA, Roda GM, Savoldi AP, Meglio LD, Signorelli G, Ierardi AM, et al. Imaging findings and available percutaneous techniques for the treatment of bile leaks after hepatobiliary surgery. *Ann Gastroenterol* 2020; **33(6)**: 675-9. doi: 10.20524/aog.2020.0532.

34. FaisalUddin M, Bansal R, Iftikhar PM, Khan J, Arastu AH. A rare case report of biloma after cholecystectomy. *Cureus* 2019; **11(8)**:e5459. doi: 10.7759/cureus.5459.
35. Calini G, Brollo PP, Quattrin R, Bresadola V. Predictive factors for drain placement after laparoscopic cholecystectomy. *Front Surg* 2022; **8**:786158. doi: 10.3389/fsurg.2021.786158.
36. Lee SJ, Choi IS, Moon JI, Yoon DS, Choi WJ, Lee SE, *et al.* Optimal drain management following complicated laparoscopic cholecystectomy for acute cholecystitis: A propensity-matched comparative study. *J Minim Invasive Surg* 2022; **25(2)**:63-72. doi: 10.7602/jmis.2022.25.2.63.
37. Lucocq J, Hamilton D, Scollay J, Patil P. Subtotal cholecystectomy results in high peri-operative morbidity and its risk-profile should be emphasised during consent. *World J Surg* 2022; **46(12)**:2955-62. doi: 10.1007/s00268-022-06737-0.
38. Acar N, Acar T, Sur Y, Bag H, Kar H, Yilmaz BY, *et al.* Is subtotal cholecystectomy safe and feasible? Short- and long-term results. *J Hepatobiliary Pancreat Sci* 2021; **28(3)**:263-71. doi: 10.1002/jhbp.847.

•••••