

Correlation of Air-Bone Gap on Pure Tone Audiometry with the Size of Perforation Assessed on Oto-Endoscopy

Aiman Fatima Naqvi¹, Syeda Uzma Naqvi², Nida Khan³, Murtaza Ahsan Ansari² and Iqbal A. Muhammad Khyani²

¹Department of ENT / Head and Neck, Karachi Institute of Medical Sciences, Karachi, Pakistan

²Department of ENT / Head and Neck, Dow University of Health Sciences, Karachi, Pakistan

³Department of ENT / Head and Neck, Shaheed Mohtarma Benazir Bhutto Medical College, Karachi, Pakistan

ABSTRACT

Objective: To determine the correlation between the air-bone gap on pure tone audiometry with size of perforation oto-endoscopically.

Study Design: A descriptive study.

Place and Duration of the Study: Department of ENT - Head and Neck Surgery, Dow University of Health Sciences (DUHS), from February 2020 to August 2021.

Methodology: A total of 43 patients with dry central pars tensa tympanic membrane perforation were diagnosed through oto-endoscopy during the study. The mean air-bone gap was calculated by assessing each air-bone gap through pure tone audiometry at different frequencies i.e., 250 Hz, 500 Hz, 1,000 Hz, 2,000 Hz, and 4,000 Hz. Air-bone gap was found to be the average value of these frequencies. The photograph of the tympanic membrane was taken oto-endoscopically, and the ratio between size of the perforation to the entire area of the tympanic membrane was measured.

Results: During the course of the study, a total of 43 patients agreed to provide consent for this study. Out of the 43 patients, 16 (37.2%) were males and 27 (62.8%) were females. The age range was from 18 to 50 years with average age of 38.302 ± 5.74 years. The mean perforation size was $28.255 \pm 9.16\%$ while the mean air-bone gap was 28.000 ± 3.89 dB. It was concluded that the Pearson's correlation coefficient is directly correlated to perforation size and air-bone gap ($r = 0.898$, $p < 0.001$). Further, hearing loss decreases with decreased middle ear volume and mastoid pneumatization. Moreover, no change was seen in the mean air-bone gap according to the location of perforation.

Conclusion: The hearing loss due to perforation of the tympanic membrane was correlated to the size of the perforation. Further, hearing loss decreases with reduced middle ear volume and mastoid pneumatization.

Key Words: Size of perforation, Hearing loss, Air-bone gap, Oto-endoscopy, Conductive deafness, Mastoid pneumatization.

How to cite this article: Naqvi AF, Naqvi SU, Khan N, Ansari MA, Khyani IAM. Correlation of Air-Bone Gap on Pure Tone Audiometry with the Size of Perforation Assessed on Oto-Endoscopy. *J Coll Physicians Surg Pak* 2024; **34(11)**:1322-1326.

INTRODUCTION

The function of the tympanic membrane is to conduct the sound waves for the purpose of hearing. In case when there is perforation, it often causes initial hearing impairment to some extent.¹ The air-bone gap is the difference between air conduction and bone conduction at certain frequencies on a pure tone audiogram. Conductive hearing loss and mixed sensorineural hearing loss can be determined by calculating this gap. The air-bone gap is negligible or within normal limits in case of normal hearing in the audiogram while, the air-bone gap is always present in case of conductive or mixed type of hearing loss.²

The perforation of the tympanic membrane mainly results from infections of middle ear, trauma, or idiopathic cause. Sometimes after an episode of acute otitis media, spontaneous perforation occurs which can lead to a tubotympanic or atticofurrow type of diseases. The causes of traumatic perforation include sudden water entry during swimming or water sports, barotrauma, explosion injuries or temporal bone fractures. These perforations reduce the surface area of the tympanic membrane. Consequently, the surface area available for sound transmission also reduces, thus resulting in hearing loss. Until the ossicles are not involved, the conductive deafness ranges from 0 to 40 dB.³ The primary reasons for conductive deafness in developing countries include high illiteracy rates, poor medical care, and lack of hygiene.⁴ Perforations mainly persist due to inadequate management of infections of the middle ear or traumatic perforations. It clearly indicates that prolonged perforations are one of the causes for hearing loss.⁵

The extent of damage to the tympanic membrane can be interpreted by an air-bone gap which can predict the size of perforation and extent of damage in the middle ear.⁶⁻¹⁰ The vision through microscope is limited at times and hidden areas cannot

Correspondence to: Dr. Aiman Fatima Naqvi, Department of ENT / Head and Neck, Karachi Institute of Medical Sciences, Karachi, Pakistan
E-mail: aimann394@gmail.com

Received: March 05, 2024; Revised: September 24, 2024;

Accepted: October 04, 2024

DOI: <https://doi.org/10.29271/jcpsp.2024.11.1322>

be addressed adequately. The extent of damage to the hearing mechanism can be anticipated before surgery and this will help in deciding the exact procedure for surgery. In this way, better outcomes can be achieved postoperatively and will be beneficial for the patients. No such study has been conducted within Pakistan to the authors' knowledge. Therefore, this study was conducted to determine the correlation between hearing impairment on pure tone audiometry with size of perforation with the aid of oto-endoscope.

METHODOLOGY

This is a descriptive cross-sectional study conducted in the department of ENT - Head and Neck Surgery at the Dow University Hospital, from February 2020 to August 2021. A total of 43 patients, meeting the inclusion criteria of age 18-50 years, both genders with dry central pars tensa tympanic membrane perforation, were included in this research study after diagnosis through oto-endoscope. An informed consent was sought from patients, and they were explained about the benefits of this research prior to include them in this study. The patients with soft tissue density in middle ear, active discharge at the time of presentation, attic perforation, and patients with the need for revision surgery were excluded from this study.

The sample size was calculated through an online sample size calculator web 'GitHub' with Pearson's Correlation formula. The sample correlation (r) = 0.42,¹¹ was used to determine the appropriate size with the power of test = 80%, level of significance = 5%, confidence level = 95%, and resultantly the sample size was 43.

The mean air-bone gap was calculated by measuring each air-bone gap on pure tone audiometry at different frequencies i.e., 250 Hz, 500Hz, 1,000 Hz, 2,000 Hz, and 4,000 Hz. The picture of

the tympanic membrane (ear drum) was captured through oto-endoscopy as shown in Figure 1 (A-C). The ratio of size of perforation to the total tympanic membrane area was measured by processing the image through 'Image J of Wayne Rasband' of the National Institutes of Health U.S.A Geometrical Package. The data on air-bone gap and size of perforation was collected by the researcher herself on purposely designed proformas.

Statistical Package for the Social Sciences Software (IBM-SPSS 20.0; SPSS Inc.) was used for analysis of data. For qualitative variable, gender was presented as percentage and frequency. Similarly, for quantitative variables, age, air-bone gap, and perforation size were presented as mean \pm standard deviation. The Pearson's correlation analysis was used to determine the correlation between the air-bone gap and perforation size. Factors such as age, gender, size of perforation, and air-bone gap on PTA were controlled by stratification. Post-stratification Pearson's Chi-square test was used and a p-value of ≤ 0.05 was considered significant.

RESULTS

A total of 43 patients meeting the inclusion criteria were included after taking an informed consent. Out of 43 patients, 16 (37.2 %) were males and 27 (62.8%) were females. The age range was from 18 to 50 years with mean age of 38.3 ± 5.74 years. The mean air-bone gap was 28.00 ± 3.89 dB on PTA. Stratification of the air-bone gap with respect to gender and age is depicted in Table I and II, respectively. The mean size of perforation was $28.25 \pm 9.16\%$ with the highest air-bone gap found in perforations involving 21-30% of the ear drum. The Pearson's correlation coefficient showed a significant correlation between size of perforation and air-bone gap ($r = 0.898$; $p < 0.001$). Stratification of the air-bone gap with respect to the perforation size is shown in Table III.

Table I: Stratification of the air-bone gap with respect to gender.

Gender	Air-bone gap (dB)		Pearson's Chi-square	p-value
	≤ 25	> 25		
Male	5 (31.2%)	11 (68.8%)	1.64	0.20
Female	4 (14.8%)	23 (85.2%)		
Total	9 (20.9%)	34 (79.1%)		

Table II: Stratification of the air-bone gap with respect to age.

Age (years)	Air-bone gap (dB)		Pearson's Chi-square	p-value
	≤ 25	> 25		
18-30	2 (33.3%)	4 (66.7%)	0.648	0.42
31-50	7 (18.9%)	30 (81.1%)		
Total	9 (20.9%)	34 (79.1%)		

Table III: Stratification of the air-bone gap with respect to perforation size.

Perforation size (%)	Air-bone gap (dB)		Pearson's Chi-square	p-value
	≤ 25	> 25		
Up to 10	2 (100%)	0 (0%)	37.276	< 0.001
11-20	6 (100%)	0 (0%)		
21-30	1 (5.3%)	18 (94.7%)		
> 30	0 (0%)	16 (100%)		
Total	9 (20.9%)	34 (79.1%)		

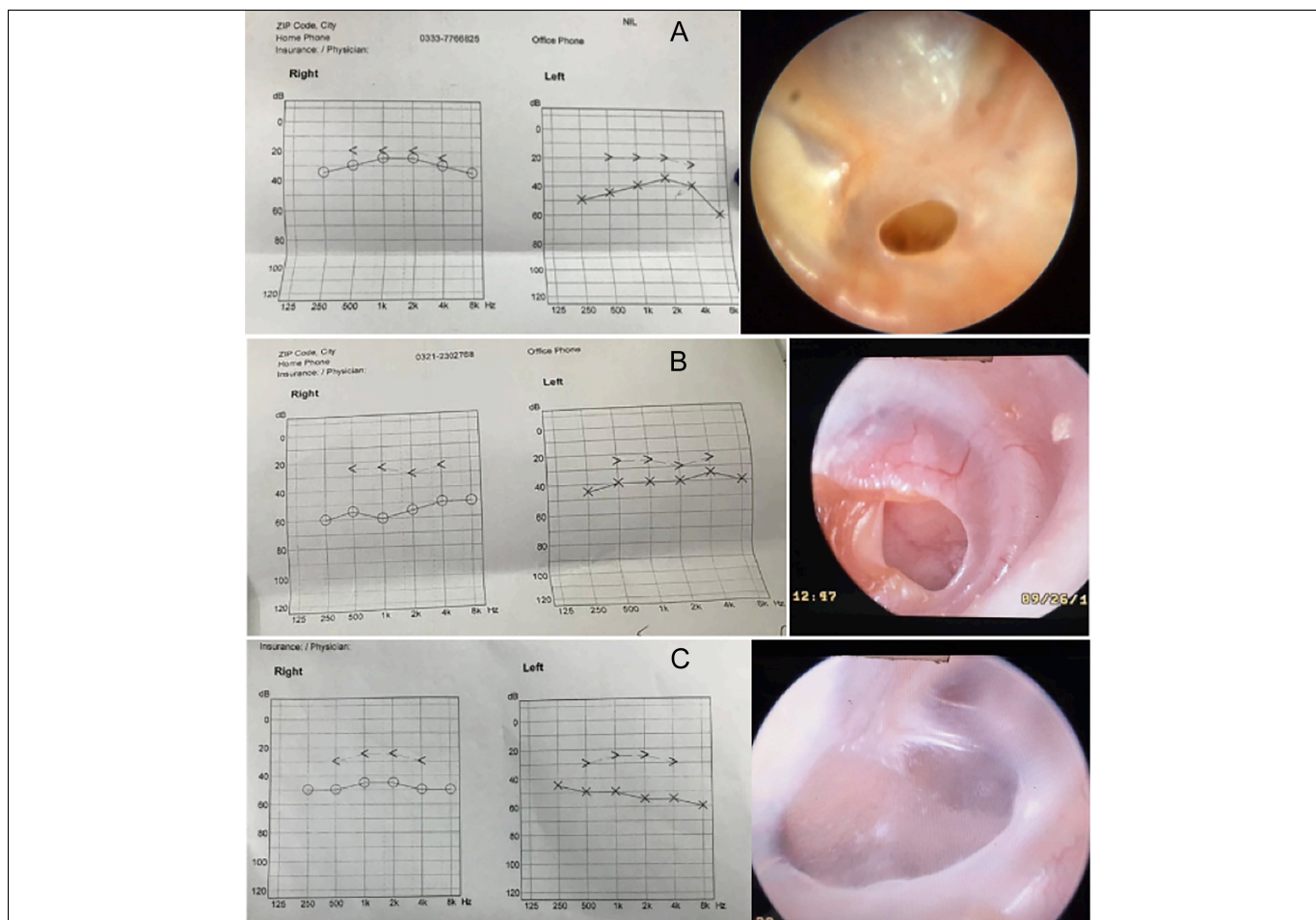


Figure 1 (A-C): Variations in tympanic membrane-perforation with PTA readings.

DISCUSSION

Vibratory movements are produced when external sound waves strike the tympanic membrane. These vibratory movements in tympanic membrane create movements in the ossicular chain. This results in production of sound in the ear. Numerous researchers reported in their studies that loss of hearing in cases of perforation in the tympanic membrane is due to a difference in pressure between the external ear and middle ear. Researchers used different models and predicted that when there is a large perforation, the hearing impairment is also more on audiogram. Also, hearing impairment increases with small middle ear and mastoid volume.

A similar trend in a different research was observed during the assessment of patients that mean air-bone gap was substantially increased with larger perforation size, small mastoid, and middle ear volumes. However, no difference was seen in the mean air-bone gap with the site of perforation.¹¹

In a study by a few researchers, tympanometry was performed for the assessment of middle ear volume and a presence of any pathology.¹² It was concluded that hearing impairment also depends on the pathology and volume of the middle ear. The same is evident from the clinical significances referred in

a study and as outlined here. It gives justification for why patients with smaller perforations have hearing loss. It can be the reason for the difference in loss of hearing with the same perforation in patients when they are having an infection. Volume of middle ear may vary due to oedema of mucosa or fluid in middle ear spaces. It is seen that patients who underwent canal-wall-down mastoidectomy have a greater hearing loss even if the size of perforation is the same due to the reason that operated ears have less middle ear volume after surgery.¹³ Some studies show that among the groups of patients who have ossicular chain defects, and those with either stapes involvement or complete ossicular chain involvement, exhibit more air conduction and bone conduction gaps. This is evident that damage to the ossicles also contributes to hearing loss.¹⁴ It has been observed that the key factor which has the most influence on mastoid pneumatization is chronically discharging ear and middle ear inflammation in childhood that can lead to tympanic membrane perforations. Thus, this can result in childhood hearing loss. In case both factors are simultaneously present, then this can result in larger air-bone gaps on an audiogram.¹⁵ There are some factors that affect mastoid pneumatization, for example, eustachian tube dysfunction, recurrent otitis media, or repeated attacks of otitis media with effusion. All these causes are responsible for disturbed pneumatization of mastoid and have shown an

effect on hearing loss.¹⁶ A study revealed one more important outcome that the patients who had larger air-bone gaps preoperatively, their air-bone gaps were decreased on pure tone audiogram postoperatively. Further, hearing recovery was also observed in the postoperative group.¹⁷ Among the ossicles, malleus was showing erosion in 40 (28.6%) cases while the head of the malleus was most eroded in (17.9%) cases. The incus was seen as the most involved ossicle, it was partially necrosed in 85 (60.7%) and absent in 44 (31.4%) cases. Stapes was intact in the majority of the cases i.e. 95 (67.9%).¹⁸ Another study showed that mild hearing loss is most commonly seen among patients with moderate size of perforation. Subtotal or total perforations resulted in increase of hearing loss to a greater extent.¹⁹ According to a study, a minimum of 0.5 ml of air space volume is required in the middle ear to maintain the pressure necessary for sound transmission. If the tympanic membrane is perforated, then this space is affected and results in impairment of hearing. There is a need for continuous awareness among the population for ear hygiene and immediate consultation with a specialist ENT clinic for evaluation and clinical diagnosis of perforation of the tympanic membrane and hearing loss associated with it.²⁰ This research is a single-centred study with a small sample size, which is its main limitation. The results of this study will pave the way for further research on this subject in indigenous populations. The authors of this study are of the view that additional research(es) may be required on mastoid pneumatisation and middle ear through developing 3-dimensional imaging of temporal bone computed tomography scan (TBCT) for in-depth study on this topic.

CONCLUSION

The loss of hearing was directly correlated to perforation size and the degree of middle ear and mastoid pneumatisation. The hearing loss increased with increased perforation size and was less in patients with less middle ear volume and mastoid pneumatisation. Therefore, the surgeon needs to consider the degree of the middle ear and mastoid pneumatisation before operating rather than focusing solely on the size of the perforation.

DISCLOSURE:

This research was an independent study conducted for the purpose of a dissertation.

ETHICAL APPROVAL:

The synopsis was approved by the Research Evaluation Unit (REU) of CPSP.

PATIENTS' CONSENT:

A written informed consent was obtained from the patients.

COMPETING INTEREST:

The authors declared no conflict of interest.

AUTHORS' CONTRIBUTION:

AFN: Idea conception, study design, data collection, analysis

and interpretation, literature search, and drafting of the manuscript.

SUN: Analysis, interpretation, and data comparison.

NK, MAA: Interpretation and critical revision of the manuscript.

IAMK: Proofreading and critical revision of the manuscript.

All authors approved the final version of the manuscript to be published.

REFERENCES

1. Stephen Agbomhekhe Ogah. Traumatic tympanic membrane perforation in Lokoja, Nigeria: A review of 43 Cases. *J Health Allied Sci* 2016; **6(4)**:68-70. doi: 10.1055/s-0040-1708678.
2. Adelman C, Cohen A, Regev-Cohen A, Chordekar S, Fraenkel R, Sohmer H. Air conduction, bone conduction, and soft tissue conduction audiograms in normal hearing and simulated hearing losses. *J Amer Acad Audiol* 2015; **26(1)**:101-8. doi: 10.3766/jaaa.26.1.11.
3. Ristovska L, Jachova Z, Filipovski R, Atanasova N. Correlation between tympanic membrane perforation and hearing loss. *J Educ Rehabil* 2016; **17(1-2)**:36. doi: 10.19057/jser.2016.2.
4. Deosthale NV, Kumar P, Khadakkar SP, Harkare VV, Dhoke PR, Dhote KS, et al. Outcome of type I tympanoplasty in tubotympanic chronic suppurative otitis media in relation to site and size of tympanic membrane perforation. *J Evolu Med Dental Sci* 2015; **4(93)**:15834-8. doi: 10.14260/jemds/2015/2295.
5. Gudepu P, Kesavan B, Kanchumurthy A. Comparative study of hearing loss with site and size of perforation. *J Evid Based Med Healthc* 2016; **3(41)**. doi: 10.18410/jebmh/2016/454.
6. Sogebi OA, Oyewole EA, Manifah TO, Ogunbanwo O. Hearing dynamics in patients with traumatic tympanic membrane perforation. *J West Afri Coll Surg* 2017; **7(2)**:15-30.
7. Virk RS, Kudawla K, Bansal S, Rathod R, Behera S. Correlation of site and size of tympanic membrane perforation and middle ear air space volume with magnitude of hearing loss. *Annals Otol Neurotol* 2019; **2(1)**:10-5. doi: 10.1055/s-0039-1693095.
8. Pannu KK, Chadha S, Kumar D. Evaluation of hearing loss in tympanic membrane perforation. *Indian J Otolaryngol Head Neck Surg* 2011; **63(3)**:208-13. doi: 10.1007/s12070-011-0129-6.
9. Ibekwe TS, Nwaorgu OG, Ijaduola TG. Correlating the site of tympanic membrane perforation with hearing loss. *BMC Ear Nose Throat Disord* 2009; **9(1)**:1. doi: 10.1186/1472-6815-9-1.
10. Matsuda Y, Kurita T, Ueda Y, Ito S, Nakashima T. Effect of tympanic membrane perforation on middle-ear sound transmission. *J Laryngol Otol* 2009; **123(S31)**:81-9. doi: 10.1017/S0022215109005155.
11. Park H, Hong SN, Kim HS, Han JJ, Chung J, Seo MW, et al. Determinants of conductive hearing loss in tympanic membrane perforation. *Clin Experiment Otorhinolaryngol* 2015; **8(2)**:92-6. doi: 10.3342/ceo.2015.8.2.92.
12. Voss SE, Rosowski JJ, Merchant SN, Peake WT. Middle-ear function with tympanic-membrane perforations. I.

- Measurements and mechanisms. *J Acoustical Society Am* 2001; **110(3)**:1432-44. doi: 10.1121/1.1394195.
13. Mehta RP, Rosowski JJ, Voss SE, O'Neil E, Merchant SN. Determinants of hearing loss in perforations of the tympanic membrane. *Otology Neurotol* 2006; **27(2)**: 136-43. doi: 10.1097/01.mao.0000176177.17636.53.
14. Albera R, Canale A, Piumetto E, Lacilla M, Dagna F. Ossicular chain lesions in cholesteatoma. *Acta Otorhinolaryngo Ital* 2012; **32(5)**:309.
15. Ichijo H, Hosokawa M, Shinkawa H. The relationship between mastoid pneumatisation and the position of the sigmoid sinus. *Eur Arch Otorhinolaryngol* 1996; **253(7)**: 421-4. doi: 10.1007/BF00168495.
16. Bayramoglu I, Ardic FN, Kara CO, Ozuer MZ, Katircioglu O, Topuz B. Importance of mastoid pneumatization on secretory otitis media. *Int J Pediatric Otorhinolaryngol* 1997; **40(1)**:61-6. doi: 10.1016/s0165-5876(97)01505-x.
17. Haksever M, Akduman D, Solmaz F, Gundogdu E. Inlay butterfly cartilage tympanoplasty in the treatment of dry central perforated chronic otitis media as an effective and time-saving procedure. *Eur Arch Oto-Rhino-Laryngol* 2015; **272(4)**:867-72. doi: 10.1007/s00405-014-2889-6.
18. Shreepaili A, Tripathi P, Neupane Y, Kharel B. Ossicular chain erosion in chronic otitis media with cholesteatoma in tertiary care hospital in Nepal. *Nepalese J ENT Head Neck Surg* 2018; **9(2)**:3-5.
19. Ediale J, Adobamen PR, Ibekwe TS. Audiometric assessment of adolescents and adults with tympanic membrane perforation in Benin City. *Int J Otorhinolaryngol Head Neck Surg* 2018; **4(4)**:901-6. doi: 10.18203/issn.2454-5929.ijohns20182699.
20. Aslier M, Ozay H, Gurkan S, Kirkim G, Guneri EA. The effect of tympanic membrane perforation site, size, and middle ear volume on hearing loss. *Turkish Arch Otorhinolaryngol* 2019; **57(2)**:86. doi: 10.5152/tao.2019.4015.

• • • • •