

Fistulectomy and Primary Sphincteroplasty for Transsphincteric Fistula

Ahmet Cihangir Emral, Merter Gulen and Bahadir Ege

Department of General Surgery, Atilim University, Faculty of Medicine, Ankara, Turkiye

ABSTRACT

Objective: To evaluate the results of patients treated with fistulectomy and primary sphincteroplasty for uncomplicated perianal fistula.

Study Design: Observational study.

Place and Duration of the Study: Medicana International Hospital affiliated with Atilim University, Faculty of Medicine, Ankara, Turkiye, from January 2020 to September 2023.

Methodology: In this study, patients who were operated on for perianal fistula between 2020 and 2023 were retrospectively examined. Data were obtained retrospectively. All patients underwent preoperative perianal MRI. Clinical notes were evaluated with the Cleveland Clinic Incontinence Score (CCIS) by physical examination. All patients were followed up on the first postoperative day, 1st week, 1st and 3rd postoperative months.

Results: A total of 44 patients who underwent fistulectomy with primary sphincteroplasty were included in the study. Twenty-six patients (59.1%) had a history of perianal abscesses. It was observed that 34 (77.3%) of the patients had posterior, 7 (15.9%) anterior, and 3 (6.8%) lateral fistulas. A total of 3 patients (6.8%) were observed to have minor worsening in their incontinence scores. There was no statistically significant difference between the preoperative and postoperative 3rd month Cleveland Clinic Incontinence Score values of the patients (CCIS mean 1.6 vs. 1.7, respectively, $p > 0.05$). Recurrence was observed in 1 patient (2.3%) during follow-ups.

Conclusion: Fistulectomy with primary sphincteroplasty is an effective and reliable method to preserve anal continence and improve quality of life.

Key Words: *Fistulectomy, Sphincteroplasty, Perianal fistula, Continence, Perianal abscess.*

How to cite this article: Emral AC, Gulen M, Ege B. Fistulectomy and Primary Sphincteroplasty for Transsphincteric Fistula. *J Coll Physicians Surg Pak* 2025; **35(03)**:363-366.

INTRODUCTION

Perianal fistula (PF) is a complex and common disease. Aetiology may include cryptoglandular abscess, inflammatory diseases, infection, tumour, and idiopathic.¹ When treating perianal fistula, the aim is to preserve anal continence, prevent the development of postoperative complications, and minimise the risk of recurrence.^{2,3} Different techniques have emerged in the treatment of PF, such as fistulotomy / fistulectomy, fistulectomy and primary sphincteroplasty (FIPS), endorectal advancement flaps (ERAF), seton (loose-cutting), laser, fibrin glue, ligation of the fistula tract (LIFT), and anal plug (anal fistula plug). Although surgery is the only curative treatment, no surgical technique has been shown to be absolutely superior in terms of effectiveness and recurrence rate.^{1,3,4}

Today, with long-term results in simple superficial fistulas, fistulotomy / fistulectomy are still the most successful method in terms of maintaining continence and low recurrence rates.^{5,6} However, in transsphincteric and complicated fistulas (recurrent fistula, high transsphincteric, extrasphincteric, suprasphincteric, and horseshoe fistulas), preserving continence and reducing the risk of recurrence is the crucial problem. The operating technique must be chosen by taking into account the balance between preserving faecal continence and eliminating the disease. In cases accompanied by perianal abscess, the Seton technique, which involves draining the abscess followed by treating the fistula tract, can be used.^{5,7}

The objective of this study was to evaluate the complications (bleeding, dehiscence, and incontinence, infection) and recurrence in the early follow-up of patients who underwent FIPS for uncomplicated perianal fistula.

METHODOLOGY

In this study, 284 patients who were operated on for perianal fistula between 2020 and 2023 were retrospectively examined. The patients' demographic information, additional diseases, anatomical fistula locations, perianal abscess history, operation techniques, and clinical notes were examined.

Correspondence to: Dr. Ahmet Cihangir Emral, Department of General Surgery, Atilim University, Faculty of Medicine, Ankara, Turkiye

E-mail: cihangiremral@hotmail.com

Received: March 15, 2024; Revised: July 04, 2024;

Accepted: August 22, 2024

DOI: <https://doi.org/10.29271/jcpsp.2025.03.363>

Exclusion criteria for the study were suprasphincteric fistulas, extrasphincteric fistulas, transsphincteric fistulas with >30% external sphincter involvement, patients with a history of previous anorectal surgery, diabetes, inflammatory bowel disease, and patients in whom the fistula was due to other specific pathologies (malignancy, tuberculosis, etc.). Patients treated with fistulectomy and sphincteroplasty for low-medium transsphincteric perianal fistulas (<30% of external sphincter involvement) were included in the study.

For this study, the Ethics Committee approval was received from the Atilim University, Faculty of Medicine, Medicana International Ankara Hospital in September 2023.

Data were obtained retrospectively from clinical examination forms. All patients underwent preoperative perianal magnetic resonance imaging (MRI). Clinical notes were evaluated using the Cleveland Clinic Incontinence Score (CCIS). According to CCIS, (0 = perfect continence, 20 = complete incontinence) 0-5 was noted as mild, 6-15 as moderate, and 16-20 as severe incontinence.

Preoperative bowel preparation was not performed in any of the patients. Prophylactic 500mg ciprofloxacin + 500mg metronidazole were administered intravenously to all patients before induction of general anaesthesia. Postoperatively, all patients used ciprofloxacin 2 x 500mg + metronidazole 3 x 500mg oral tablets for seven days. A liquid oral diet was started at the 4th postoperative hour and liquid diet was recommended for the first three days. All patients were examined on the first postoperative day and discharged. After discharge, all patients were followed up on the 1st week, 1st and 3rd postoperative months. Clinical follow-ups of the patients were prospectively filled into examination forms. Demographic, anatomical and operational information of the patients, complications (bleeding, dehiscence, incontinence, and infection), and recurrence were evaluated retrospectively from prospectively filled examination forms.

All patients were operated on by the same surgical team (BE, MG, ACE) in the prone jack-knife position under general anaesthesia. The internal orifice was exposed by crossing the fistula tract with the stylet placed on the external orifice (Figure 1). The fistula tract was unroofed up to the transsphincteric part (Figure 2). Subsequently, the transsphincteric part was held and cut with the surgical clamps. The fistula tract was irrigated with saline after mechanical irrigation. The transsphincteric part was held with surgical clamps. Overlapping sphincteroplasty was performed primarily with 2-0 polydioxanone suture (Figure 3).

Data were collected retrospectively from prospectively-filled examination forms. Data were expressed as the mean (\pm standard deviation), and categorical data were presented as counts and percentages. Inter-group analysis was performed using the paired t-test. A p-value of less than 0.05 was considered to be statistically significant. Analysis was carried out with SPSS version 20.0 software for Windows (IBM-SPSS, Chicago, IL, USA).

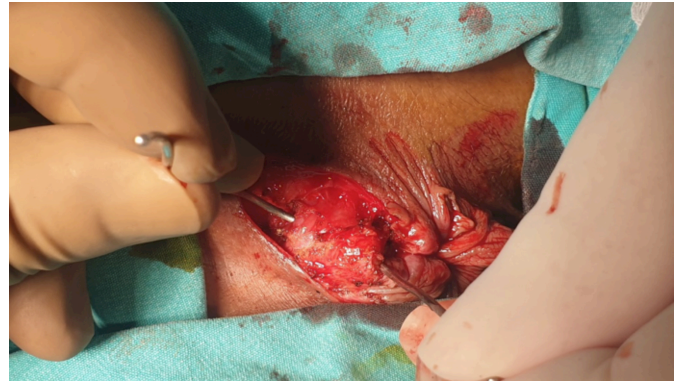


Figure 1: External anal sphincter and transsphincteric fistula tract.

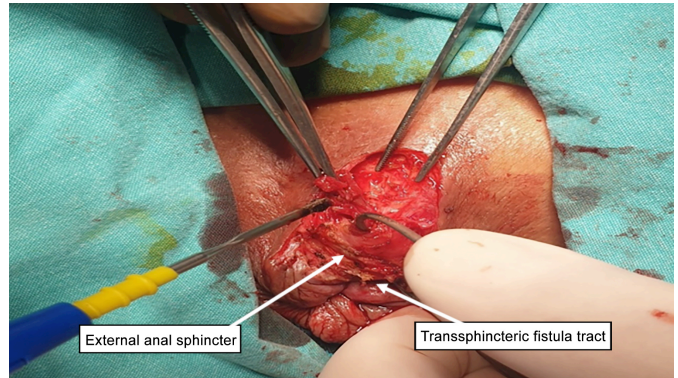


Figure 2: Fistulotomy + sphincterotomy.

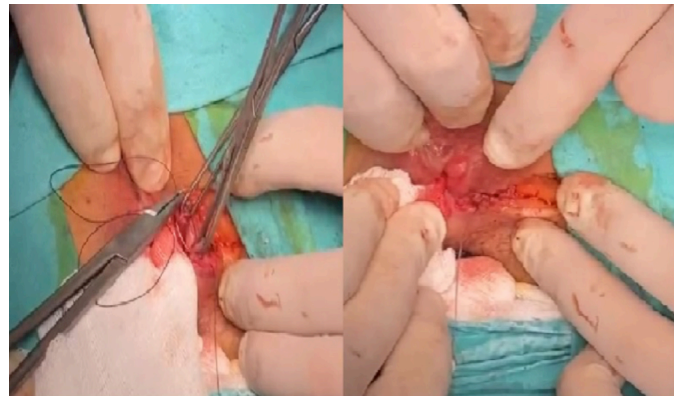


Figure 3: Overlapping primary sphincteroplasty.

RESULTS

Between 2020 and 2023, 284 patients were operated on for perianal fistula. A total of 44 patients, 19 (43.2%) males and 25 (56.8%) females, who underwent fistulectomy with primary sphincteroplasty and met the study criteria, were included in the study.

The average age of the patients was 50.8 ± 6.9 years. Twenty-six patients (59.1%) had a history of perianal abscesses. It was observed that 34 (77.3%) of the patients had posterior, 7 (15.9%) anterior, and 3 (6.8%) lateral fistulas. All patients were examined on the 1st day and followed up on the 1st week, 1st and 3rd months postoperatively. No patient was lost to follow-up. No postoperative bleeding or dehiscence of the sphincteroplasty was observed in any of the patients. A total of 3 patients (6.8%) were observed to have minor worsening in their incontinence

scores. Two of these patients were women and their ages were 42 and 53, respectively. Both patients had a history of 2 vaginal births. There was no additional comorbidity in either of them. It was observed that CCIS increased from 2 to 4 and from 2 to 3 points, respectively. Apart from these patients, an increase in incontinence score from 3 to 4 was observed in a 65-year male patient. The patient had no comorbidities other than coronary artery disease and hypertension. There was no statistically significant difference between the preoperative and postoperative 3rd month Cleveland Clinic Incontinence Score values of the patients (CCIS mean 1.6 ± 1.1 vs. 1.7 ± 1.2 ($p > 0.05$)).

During the follow-up of the patients, a recurrence was observed in 1 (2.3%) patient. This patient, a 53-year female, had a recurrence in the 3rd postoperative month, but it was observed that the patient did not develop a perianal abscess and there was no worsening in the patient's continence (preoperative CCIS and postoperative, CCIS = 4).

DISCUSSION

The gold standard treatment for anal fistula is surgery. The most effective and minimal complication of the treatment of this disease, which has a great impact on the quality of life of patients, is still a matter of debate among surgeons interested in proctology. The selection of the treatment method by experienced surgeons according to the type of fistula and the underlying pathology, if any, is the main factor that ensures success and low complication rates. From the author's perspective, the most important factor affecting postoperative success is the experience of the surgeon specialised in proctology. Successful treatment of the disease depends on the evaluation of the patient by an expert surgeon, good preoperative and peroperative fistula mapping, and the selection and successful implementation of the best surgical treatment specific to the patient.

Surgeons avoid the fistulectomy technique due to the fear of developing irreversible incontinence, especially in fistulas involving the external sphincter. However, studies have shown that this technique is safe when applied by surgeons specialised in proctology.⁸⁻¹⁰ Incontinence rates of up to 35% in advancement flap applications and 67% in seton applications have been reported.^{6,11-13} In this study, worsening of continence was observed in 6.8% of cases, and this is acceptable in terms of fistula surgery. For sphincteroplasty, the technique of an experienced and proctology-specific surgeon plays an essential role in avoiding incontinence. With this technique, fistula can be treated comfortably in one go and in a short time. In addition, anal discomfort (such as post-defaecation soiling and anal itching) seen due to seton application is not seen after this technique.^{4,10,12}

Ratto *et al.* reported an overall success rate of 93.2% in 666 patients who underwent FIPS. In this study, the fistulectomy/fistulotomy ratio was 10/4, and it was observed that the choice between fistulectomy and fistulotomy did not influence the treatment's success.¹⁰ In addition, many studies have shown that overlapping sphincteroplasty provides better results in terms of

reducing the risk of sphincter dehiscence and long-term anal function compared to end-to-end sphincteroplasty.^{8,9} As a result of overlapping sphincteroplasty, Arroyo *et al.* observed no patient, and Roig *et al.* observed only 1 case of dehiscence.^{14,15} In this study, overlapping sphincteroplasty technically was preferred and no dehiscence were observed.

Arroyo *et al.* compared the short-term and long-term results in terms of recurrence and found them to be 5.7% vs. 8.6%, respectively.^{14,16} Ratto *et al.* found that 4.2% of patients developed recurrence after an average of 17.3 months in their study.¹⁷ In this study, short-term recurrence results (2.3%) are good, but long-term results need to be followed up.

The most important limiting feature of FIPS treatment is that it must be performed by surgeons experienced in proctology. It is a treatment that requires knowledge of anal fistula disease and the anatomy of the anorectal region. FIPS can be preferred as a reliable method in experienced hands. The most important limiting factor in this study is the small number of patients and the unknown long-term results. In addition, there is no comparison with other techniques used for anal fistula surgery.

CONCLUSION

The results of this study convey that this method is successful in fistula healing and maintaining continence. Fistulectomy with primary sphincteroplasty is seen as an effective and reliable method for preserving anal continence and improving quality of life.

ETHICAL APPROVAL:

This study was approved by the Atilim University Medicana International Ankara Hastanesi's Ethics Committee (Decision No: 20, Dated: 22.09.2023).

PATIENTS' CONSENT:

Informed consent and the last follow-up details were obtained by examining medical records and conducting telephone interviews.

COMPETING INTEREST:

The authors declared no conflict of interest.

AUTHORS' CONTRIBUTION:

ACE: Design of the manuscript, data collection, interpretation, and proofreading.

MG: Wrote the final manuscript, collected the data, and analysed the results.

BE: Contributed to data analysis and reviewed the manuscript.

All authors approved the final version of the manuscript to be published.

REFERENCES

1. Abbas MA, Jackson CH, Haigh PI. Predictors of outcome for anal fistula surgery. *Arch Surg* 2011; **146(9)**:1011-6. doi: 10.1001/archsurg.2011.197.
2. Lindsey I, Jones OM, Smilgin-Humphreys MM, Cunningham C, Mortensen NJ. Patterns of fecal incontinence after anal surgery. *Dis Colon Rectum* 2004; **47(10)**:1643-9. doi: 10.1007/s10350-004-0651-7.

3. Gulen M, Sariyildiz GT, Pala MI, Ege B. The effect of hybrid seton on anal continence and quality of life in transsphincteric fistulas. Long-term follow-up. *Ann Ital Chir* 2022; **93**:716-9.
4. Mascagni D, Pironi D, Pontone S, Tonda M, Eberspacher C, Panarese A, et al. Total fistulectomy, sphincteroplasty and closure of the residual cavity for trans-sphincteric perianal fistula in the elderly patient. *Aging Clin Exp Res* 2017; **29(Suppl 1)**:101-8. doi: 10.1007/s40520-016-0652-0.
5. Daodu OO, O'Keefe J, Heine JA. Draining setons as definitive management of fistula-in-ano. *Dis Colon Rectum* 2018; **61(4)**:499-503. doi: 10.1097/DCR.0000000000001045.
6. Bleier JI, Moloo H, Goldberg SM. Ligation of the intersphincteric fistula tract: An effective new technique for complex fistulas. *Dis Colon Rectum* 2010; **53(1)**:43-6. doi: 10.1007/DCR.0b013e3181bb869f.
7. Malik AI, Nelson RL, Tou S. Incision and drainage of perianal abscess with or without treatment of anal fistula. *Cochrane Database Syst Rev* 2010; **7(7)**:CD006827. doi: 10.1002/14651858.CD006827.pub2.
8. Fernando RJ, Sultan AH, Kettle C, Thakar R. Methods of repair for obstetric anal sphincter injury. *Cochrane Database Syst Rev* 2013; **2013(12)**:CD002866. doi: 10.1002/14651858.CD002866.pub3.
9. Perez F, Arroyo A, Serrano P, Sanchez A, Candela F, Perez MT, et al. Randomized clinical and manometric study of advancement flap versus fistulotomy with sphincter reconstruction in the management of complex fistula-in-ano. *Am J Surg* 2006; **192(1)**:34-40. doi: 10.1016/j.amjsurg.2006.01.028.
10. Ratto C, Litta F, Donisi L, Parello A. Fistulotomy or fistulectomy and primary sphincteroplasty for anal fistula (FIPS): A systematic review. *Tech Coloproctol* 2015; **19(7)**:391-400. doi: 10.1007/s10151-015-1323-4.
11. Tabry H, Farrands PA. Update on anal fistulae: Surgical perspectives for the gastroenterologist. *Can J Gastroenterol* 2011; **25(12)**:675-80. doi: 10.1155/2011/931316.
12. Aguilar JG, Belmonte C, Wong DW, Goldberg SM, Madoff RD. Cutting seton versus two-stage seton fistulotomy in the surgical management of high anal fistula. *Br J Surg* 1998; **85(2)**:243-5. doi: 10.1046/j.1365-2168.1998.02877.x.
13. Schouten WR, Zimmerman DD, Briel JW. Transanal advancement flap repair of transsphincteric fistulas. *Dis Colon Rectum* 1999; **42(11)**:1419-22; discussion 1422-3. doi: 10.1007/BF02235039.
14. Arroyo A, Legaz JP, Moya P, Armananzas L, Lacueva J, Vicente FP, et al. Fistulotomy and sphincter reconstruction in the treatment of complex fistula-in-ano: Long-term clinical and manometric results. *Ann Surg* 2012; **255(5)**:935-9. doi: 10.1097/SLA.0b013e31824e9112.
15. Roig JV, Armengol JG, Jordan JC, Moro D, Granero EG, Alos R. Fistulectomy and sphincter reconstruction for complex cryptoglandular fistulas. *Colorectal Dis* 2010; **12(7 Online)**:e145-52. doi: 10.1111/j.1463-1318.2009.02002.x.
16. Perez F, Arroyo A, Serrano P, Candela F, Perez MT, Calpena R. Prospective clinical and manometric study of fistulotomy with primary sphincter reconstruction in the management of recurrent complex fistula-in-ano. *Int J Colorectal Dis* 2006; **21(6)**:522-6. doi: 10.1007/s00384-005-0045-x.
17. Ratto C, Litta F, Parello A, Zacccone G, Donisi L, De Simone V. Fistulotomy with end-to-end primary sphincteroplasty for anal fistula: Results from a prospective study. *Dis Colon Rectum* 2013; **56(2)**:226-33. doi: 10.1097/DCR.0b013e31827aab72.

