

# Lumbar Erector Spinae Plane Block Provides Effective Postoperative Analgesia in Hip Fracture Surgery

Onur Balaban<sup>1</sup>, Ali Eman<sup>1</sup>, Onur Palabiyik<sup>1</sup> and Alauddin Kochai<sup>2</sup>

<sup>1</sup>Department of Anesthesiology and Reanimation, Faculty of Medicine, Sakarya University, Sakarya, Turkiye

<sup>2</sup>Department of Orthopaedics and Traumatology, Faculty of Medicine, Sakarya University, Sakarya, Turkiye

## ABSTRACT

**Objective:** To compare the postoperative analgesic effectiveness of ultrasound-guided lumbar erector spinae plane (LESP) block with lumbar plexus block (LPB) in patients operated for proximal femur fractures.

**Study Design:** A randomised controlled trial.

**Place and Duration of the Study:** Sakarya Training and Research Hospital Operation Theatre, Sakarya, Turkiye, between January and June 2023.

**Methodology:** Patients undergoing proximal femur fracture surgery were randomised to receive either an LESP block or an LPB block. The primary outcome was 24 hour opioid consumption, which was given via a standard patient-controlled analgesia protocol. The secondary outcome was postoperative pain scores (numerical rating scale between 0 and 10) at the 30<sup>th</sup> minute, 2<sup>nd</sup>, 6<sup>th</sup>, 12<sup>th</sup>, and 24<sup>th</sup> hour time points. Mann-Whitney U test was used to compare the primary and secondary outcomes.

**Results:** A total of 64 patients were randomised, and 53 were analysed (25 patients in the LESP group and 28 patients in the LPB group). Demographic data were comparable between the groups. Mean NRS pain scores in 30<sup>th</sup> minute, 2<sup>nd</sup>, 6<sup>th</sup>, 12<sup>th</sup>, and 24<sup>th</sup> hours were  $0.7 \pm 1.3$ ,  $1.2 \pm 1.8$ ,  $2.2 \pm 2.3$ ,  $1.8 \pm 1.9$ , and  $1.9 \pm 2.0$  in the LESP group and  $0.5 \pm 1.0$ ,  $1.1 \pm 1.8$ ,  $1.6 \pm 1.9$ ,  $1.9 \pm 1.9$ , and  $1.6 \pm 1.7$  in the LPB group, respectively without significant difference. No significant differences were observed in fentanyl consumption between the LESP group ( $183.6 \pm 171.7\mu\text{g}$ ) and LPB group ( $131.1 \pm 113.3\mu\text{g}$ ,  $p = 0.415$ ).

**Conclusion:** Single injection LESP block provided satisfactory postoperative analgesia and comparable opioid consumption without a major complication. Therefore, the LESP block is an effective method for hip fracture surgery as a strong alternative to the LPB.

**Key Words:** Lumbar erector spinae plane block, Lumbar plexus block, Ultrasound-guided, Hip surgery, Femur fracture, Postoperative analgesia.

**How to cite this article:** Balaban O, Eman A, Palabiyik O, Kochai A. Lumbar Erector Spinae Plane Block Provides Effective Postoperative Analgesia in Hip Fracture Surgery. *J Coll Physicians Surg Pak* 2025; **35(01)**:5-10.

## INTRODUCTION

The number of patients experiencing hip fractures is increasing every year.<sup>1</sup> As a result of the ageing of the population, the amount of these patients is expected to continuously increase in the near future.<sup>2</sup> Perioperative pain is a significant problem for operated hip fracture patients, which may lead to cardiovascular and pulmonary complications, poor recovery, and prolonged hospital stay.<sup>3</sup> The postoperative pain in hip surgery is procedure specific, which is important for the pain management of these patients.<sup>4</sup> Therefore, perioperative hip fracture pain needs to be carefully managed by using intravenous analgesics, neuraxial techniques, or peripheral nerve blocks.

The guideline of the European Society of Regional Anaesthesia (ESRA) gives recommendations for managing postoperative pain. The latest ESRA Prospect guideline about the management of postoperative pain after hip surgery (primarily published for total hip arthroplasty) recommends a multimodal analgesia technique, including the femoral nerve block, lumbar plexus block, and fascia iliaca blocks, as effective alternatives when a nerve block is preferred.<sup>5</sup>

The prospect-suggested lumbar plexus block (LPB) is one of the traditional methods for postoperative analgesia in hip surgery.<sup>5,6</sup> However, LPB is considered a deep block with potential risks and difficulties, and performing an LPB may be challenging even when the ultrasound is used.<sup>6,7</sup> Although LPB improves pain management in these patients, the guideline emphasises the superiority of the local infiltration analgesia and fascia iliaca blocks, where the benefits outweigh the adverse effects. The lumbar erector spinae plane (LESP) block is an appropriate alternative to the aforementioned block methods, which may provide sufficient postoperative analgesia in hip surgeries. The distribution of an LESP injection may spread up to five lumbar vertebrae levels.<sup>8</sup> It can potentially affect spinal nerves that contribute to both lumbar and sacral

Correspondence to: Dr. Onur Balaban, Department of Anaesthesiology and Reanimation, Faculty of Medicine, Sakarya University, Sakarya, Turkiye  
E-mail: obalabandr@gmail.com

Received: August 29, 2024; Revised: December 05, 2024;

Accepted: December 18, 2024

DOI: <https://doi.org/10.29271/jcpsp.2025.01.5>

plexus. In some situations, it may affect by influencing the epidural space through the intervertebral foramen acting as an epidural block.<sup>9-12</sup> LESP block was first described for hip surgery; however, the LESP block is versatile, which is performed *via* different locations and has the elasticity of being suitable for variable kinds of surgeries.<sup>10</sup>

This study aimed to test the hypothesis that LESP block may provide superior postoperative analgesia compared to the LPB in patients operated for proximal femur fractures. The primary assumption was that the local anaesthetic solution might spread to sacral levels in an LESP block and provide a wider analgesic area.

### METHODOLOGY

The study was designed as a prospective double-blinded (patient and assessor-blinded), randomised controlled trial. The study was approved by the Institutional Ethical Board (Approval No: E-16214662-050.01.04-11637-27) and was carried out at Sakarya University Hospital Operation Theatre and Orthopaedic Surgery Ward, between January and June 2023. The study was registered at the clinicaltrials.gov with the registry number NCT05817916. Patients with the American Society of Anaesthesiologists (ASA) classification I-III, aged between 40 and 99, scheduled for hip surgery due to a proximal femur fracture were included. Written informed consents were obtained from the patients before the enrolment. Exclusion criteria were patient refusal or contraindication for the block methods, having severe cardiovascular and pulmonary disease, and uncooperative patients who cannot respond to pain questioning. The study protocol was not changed except for an increase in the age range up to 99 years shortly after starting the study.

The patients were randomly allocated into two groups. Randomisation was performed by a computer programme that generates a randomised allocation list. The allocations and performance of the block procedures were done by the senior and co-authors. In the LESP group, an LESP block was performed. In the LPB group, a lumbar plexus block was performed. All blocks were performed under ultrasound (US) guidance in a lateral position after the operations in the operation theatre. A non-traumatic, echogenic needle (Sonoplex STIM, Pajunk, Geisingen, Germany) was implemented for the blocks. The patients were blinded to the procedure as all injections were performed at the same place. Blinding the clinician performing the block was not possible; however, data on post-operative pain were collected by the members of the pain-nurse team, who were all blinded to the block procedures. For surgical anaesthesia, a spinal block, after standard monitoring, was performed at L4 - L5 or L3 - L4 intervertebral level in the sitting position using a standard 25 G pencil-point needle, and isobaric bupivacaine was injected intrathecally. The dose of intrathecal local anaesthetic was 2.5 - 3 ml (12.5 - 15 mg) bupivacaine in 0.5% concentration which was principally determined depending on the patient's age, height, and injection

site. A standard lateral approach and a lateral incision were implemented in hip surgery for all patients.

The regional blocks were performed after the subarachnoid block at the end of the surgery in the operation rooms. After sterile preparation of the block site with alcohol-based disinfectants and covering the US probe with a sterile drape, the LESP block was performed in the lateral decubitus position. A curved array low frequency (2-5 MHz) ultrasound probe (M-Turbo, Fuji Sonosite) was placed in the paramedian sagittal position. The probe was adjusted to obtain a longitudinal US image of the lumbar spine showing the laminae. After finding the correct injection level (L4 vertebrae level), the probe was slid laterally to show the transverse processes. A 100 mm block needle (Braun Stimplex ultra, Melsungen; Germany) was inserted from the caudal aspect of the US probe to the cranial direction, targeting the transverse process (Figure 1). After touching the bone, 0.5 ml/kg of 0.25% bupivacaine was injected under direct ultrasound visualisation. Calculation of local anaesthetic dose was based on ideal body weight. The distribution was verified continuously at least three vertebrae levels (Figure 1).

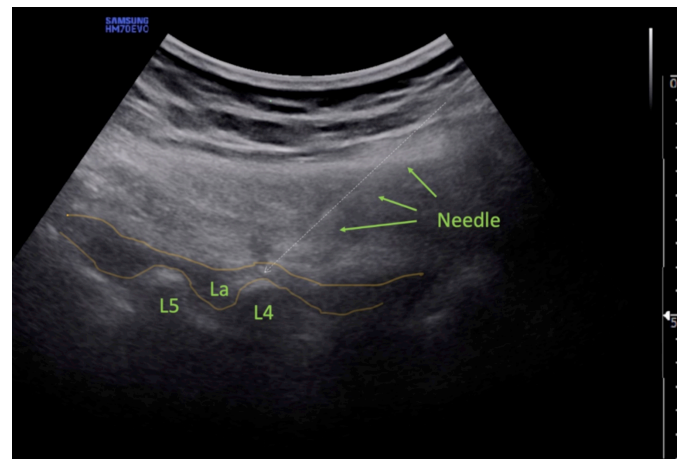


Figure 1: Ultrasound image of lumbar erector spinae plane block performance showing the needle, L4 and L5 lumbar vertebrae, and the distribution of local anaesthetic solution (La).

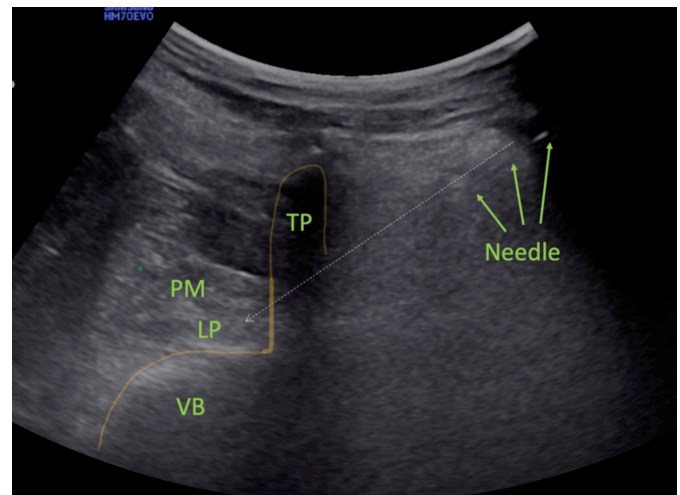


Figure 2: Ultrasound image of lumbar plexus block performance showing the needle, lumbar plexus (LP), transverse process (TP), vertebra body (VB), and the psoas muscle (PM).

For the performance of the LPB, a curved array US probe was placed transversally at the space between crista iliaca and lower costochondral joint after preparation as explained for the LESP block. A shamrock image of the psoas, quadratus lumborum, and erector spinae muscles was obtained. The lumbar plexus was imaged as a hyperechogenic white object embedded in the psoas muscle placed anterolateral to the vertebra corpus. The block needle was inserted posteriorly, 2-3 cm lateral to the spinous processes targeting the lumbar plexus. Using the in-plane technique, the needle was advanced in the posterior to anterior direction until it reached the posterior aspect of the lumbar plexus. If the needle touched the transverse process, it was redirected caudally or cephalad to pass and reach the targeted lumbar plexus. A neurostimulator was not necessary to identify the lumbar plexus. The same amount of prepared local anaesthetic solution (0.5 ml/kg of 0.25% bupivacaine) was injected to distribute around the lumbar plexus in real-time ultrasound visualisation (Figure 2).

After the blocks, the patients were transferred to the postoperative care unit and observed for at least 30 minutes. An intravenous patient-controlled anaesthesia (PCA) device was prepared and attached to the intravenous line, including fentanyl, which was programmed to give 25 µg of fentanyl boluses with 15-minute intervals and a 125 µg four-hours limit. Systemic analgesia was administered using a standardised protocol of intravenous acetaminophen three times a day routinely and intravenous tramadol as a rescue analgesic when necessary. The verbal pain scores of the patients at the 30<sup>th</sup> minute were recorded, and if the patient was haemodynamically stable, he/she was discharged to the surgery ward. The procedure was

considered a failed block if the patient's verbal pain score was equal to or over 6/10, and in all time points, the patient was excluded from the study, and additional rescue analgesics were given.

The patients were followed up for 24 hours after the surgery. Age, gender, weight, height, body mass index (BMI), comorbid diseases, and medications were recorded. Total anaesthesia times and surgery times were also recorded. Verbal pain scores (between 0 = no pain and 10 = worst pain ever) were asked and recorded at postoperative 2<sup>nd</sup>, 6<sup>th</sup>, 12<sup>th</sup>, and 24<sup>th</sup> hours. Fentanyl consumption within 24 hours was derived from the records of the PCA device. Early and late complications such as pain/bleeding or sensory loss at the block area, motor weakness, and nausea/vomiting were also recorded. The primary outcome was total intravenous opioid consumption in 24 hours, and the secondary outcomes were 24 hour pain scores and early and late complications regarding the block techniques.

The sample size was determined as 25 patients in each group (statistical power was 80% and  $\alpha$  error was 0.05) to detect a 25% decrease (from 3 to 2.25 with an effect size of 0.75) between the LESP and the LPB groups in the mean NRS pain scores.<sup>13</sup> Considering the possibility of patients being excluded from the study for any reason, such as complications and dropouts, the study was designed with 30 patients in each group. SPSS version 20 (Statistical Package for Social Sciences) software (IBM Corp., Armonk, NY) was used for the statistical analysis of the study data. Descriptive statistics were expressed as mean, standard deviation, median (minimum, maximum), and frequencies (percentages).

**Table I: Comparison of the demographic characteristics in two groups. Data were given as numbers, percentages, mean  $\pm$  standard deviation, median (min-max).**

Parameters	LESP group	LPB group	p-value
Age (year)	80.3 $\pm$ 7.9	78.2 $\pm$ 8.4	0.382 <sup>t</sup>
Gender			
Male	12 (48%)	10 (35.7%)	0.365 <sup>x2</sup>
Female	13 (52%)	18 (64.3%)	
Weight (kg)	70.0 (43.0-85.0)	64.0 (48.0-98.0)	0.432 <sup>m</sup>
Height (cm)	164.0 (150.0-185.0)	162.0 (152.0-178.0)	0.734 <sup>m</sup>
BMI (kg/m <sup>2</sup> )	25.5 (16.9-29.1)	24.5 (20.3-42.4)	0.433 <sup>m</sup>
Anaesthesia time	135.0 (80.0-270.0)	130.0 (80.0-195.0)	0.756 <sup>m</sup>
Operation time	115.0 (65.0-250.0)	105.0 (70.0-180.0)	0.507 <sup>m</sup>

BMI: Body mass index. <sup>x2</sup> Chi-square test. <sup>t</sup> Independent samples t-test. <sup>m</sup> Mann-Whitney U test.

**Table II: Comparison of pain scores in different time points. The data were given as mean  $\pm$  standard deviation in a range between 0 and 10 (which means that zero is no pain and 10 worst pain).**

Time points	LESP group	LPB group	p-value*
30 <sup>th</sup> minute	0.7 $\pm$ 1.3 0 (0-4)	0.5 $\pm$ 1.0 0 (0-3)	0.915
2 <sup>nd</sup> hour	1.2 $\pm$ 1.8 0 (0-5)	1.1 $\pm$ 1.8 0 (0-7)	0.517
6 <sup>th</sup> hour	2.2 $\pm$ 2.3 2 (0-7)	1.6 $\pm$ 1.9 2 (0-7)	0.418
12 <sup>th</sup> hour	1.8 $\pm$ 1.9 1 (0-5)	1.9 $\pm$ 1.9 2 (0-6)	0.934
24 <sup>th</sup> hour	1.9 $\pm$ 2.0 2 (0-7)	1.6 $\pm$ 1.7 1.5 (0-6)	0.712

\*Mann-Whitney U test was used to determine the p-values.

**Table III: Comparison of opioid consumption, rescue analgesics, and postoperative complications. Data were given as numbers, percentages, mean  $\pm$  standard deviation, median (min-max).**

Parameters	LESP group	LPB group	p-value
Total fentanyl consumption ( $\mu$ g)	183.6 $\pm$ 171.7 75.0 (24.0-574.0)	131.1 $\pm$ 113.3 80.0 (25.0-485.0)	0.415 <sup>m</sup>
Rescue analgesic requirement (n)			
None	16 (64.0%)	22 (78.6%)	0.240 <sup>x2</sup>
Dexketoprofen (once a day)	4 (16.0%)	2 (7.1%)	
Dexketoprofen (twice a day)	5 (20.0%)	2 (7.1%)	
Tramadol	0 (0.0%)	2 (7.1%)	
Complications			
None	21 (84.0%)	25 (89.3%)	0.570 <sup>x2</sup>
Delirium	1 (4.0%)	1 (3.6%)	
Nausea/Vomiting	0 (0.0%)	1 (3.6%)	
Motor weakness	3 (12.0%)	1 (3.6%)	

<sup>x2</sup> Chi-square test. <sup>m</sup> Mann-Whitney U test.

The data of continuous variables were presented as mean and standard deviation. Kolmogorov-Smirnov test was utilised to test the distribution of variables. Independent samples test was used in the analysis of quantitative independent data. Mann-Whitney U test was used to analyse the non-normal distributed data, which were weight, height, body mass index, anaesthesia time, operation time, pain scores, and total fentanyl consumption. Chi-square test was used to analyse rescue analgesic requirement and complications rate. The parametric and non-parametric tests used for each variable are given in detail in Table I-III. A p-value less than 0.05 was considered statistically significant.

## RESULTS

In total, 64 patients were randomised to the groups, and data from 53 patients were evaluated; 25 patients were allocated to the LESP group and 28 patients to the LPB group. Four patients were excluded (three patients in the LESP group and one patient in the LPB group) due to block failure. Seven patients were excluded (six patients in the LESP groups and one patient in the LPB group) due to missing data.

Of the patients, 22 patients were males and 31 were females. The mean age was 80.3  $\pm$  7.9 years in the LESP group and 78.2  $\pm$  8.4 years in the LPB group. Age, gender, weight, height, and body mass index were comparable in the two groups. Demographic characteristics are shown in Table I. Postoperative NRS scores at the 30<sup>th</sup> minute, 2<sup>nd</sup> hour, 6<sup>th</sup> hour, 12<sup>th</sup> hour, and 24<sup>th</sup> hour did not show a significant difference between the LESP and LPB groups ( $p > 0.05$ , Table II). The 24-hour-fentanyl consumption was 183.6  $\pm$  171.7  $\mu$ g in the LESP group and 131.1  $\pm$  113.3  $\mu$ g in the LPB group which did not differ significantly between the groups ( $p > 0.05$ , Table III).

In the LESP group, nine patients required dexketoprofen, and no patients required tramadol. In the LPB group, four patients required dexketoprofen, and two patients received tramadol. Rescue analgesic requirements between the two

groups did not differ significantly ( $p = 0.240$ , Table III). Three patients in the LESP group and one patient in the LPB group showed motor weakness in the postoperative second hour. No patient showed motor weakness in the 6<sup>th</sup> hour visit. The rate of block-related complications did not significantly differ between groups ( $p = 0.570$ , Table III).

## DISCUSSION

In the present study, no difference was observed in the analgesic effect of single injection LPB and LESP block during the postoperative 24 hours in patients undergoing proximal hip-fracture surgery. Postoperative opioid consumption was also comparable. Both LPB and LESP provided sufficient postoperative analgesia. Epidural analgesia has high analgesic efficacy and is considered as the gold standard for the analgesia of hip surgery. However, its adverse safety profile and potential side effects limit the usage of postoperative analgesia. Recent ERAS guideline published for hip and knee replacement surgeries no longer recommends epidural analgesia due to the potential for adverse effects that delay recovery.<sup>14</sup> Moreover, the superiority of motor-sparing blocks or a local anaesthetic infiltration is notified by the recent PROSPECT guideline in hip surgery instead of the epidural block.<sup>3</sup> Nonetheless, the new fascial plane blocks are still a topic of research which are not mentioned in these guidelines. The analgesic effectiveness of LESP block was demonstrated for hip arthroplasty surgeries.<sup>15,16</sup> The recommendations are made especially for hip-replacement surgery, and perioperative analgesia in hip-fracture surgery still remains unclear.

The lumbar ESP block has a high potential for postoperative analgesia with the advantages of unilateral blockade and the opportunity of prolonged effect by placing a catheter. Innervation of the hip joint is complex, with related nerves arising from both the lumbar and sacral plexus.<sup>17,18</sup> The posterior innervation of the hip capsule is supplied primarily by mechanoreceptors without any sensory fibres.<sup>19</sup> The nociceptive fibres are principally placed at the anterior capsule, which is the primary source of pain after hip surgeries involving the femoral, obturator, and accessory

obturator nerves.<sup>17</sup> LPB mostly covers nerves arising from the lumbar plexus and seems to be similarly effective as LESP.

Studies comparing LPB to LESP block have reported the achievement of adequate postoperative analgesia by using both methods. Diwan *et al.* performed single injection LESP block in 30 patients and performed LPB in 30 patients undergoing proximal femur fracture.<sup>13</sup> They found statistically better postoperative pain scores in the first 24 hours for LESP block. However, when the pain scores are reviewed, results seem to be clinically comparable with sufficient analgesic efficacy for the LPB and LESP blocks. In a retrospective study, Chen *et al.* compared continuous LESP block with continuous LPB in hip revision arthroplasty. They found similar postoperative analgesic effects and comparable opioid consumption in both methods.<sup>20</sup> They reported that LESP block is as effective as LPB for postoperative analgesia and emphasised the safety of LESP block, which may avoid the potential risks of LPB. However, the difficulty of keeping the catheter in place and the need for multiple local anaesthetic boluses through the catheter may restrict the usage of continuous blocks at the lumbar region. In contrast to these studies, Chan *et al.* found no improvement in analgesia or a reduction of fentanyl consumption with LESP block in hip-replacement surgery compared to systemic analgesia.<sup>21</sup> The researchers implemented a single-shot LESP block at the L1 vertebra level using 40 ml of 0.25% bupivacaine. Even with high volumes, the distribution of the solution may be restricted in ESP blocks at the lumbar region.

Early ambulation in these patients is important for early recovery; thus, motor-sparing analgesia is essential. Both LPB and LESP blocks have the potential to reduce muscular weakness. Three patients in the LESP group and one patient in the LPB group experienced bilateral lower-extremity motor block, which prolonged up to 2 hours. The early postoperative bilateral motor weakness was interpreted as it was related to spinal anaesthesia. Although evaluation of the motor-sparing effect of these blocks was not a primary aim of this study, no block-related quadriceps weakness was observed in the patient group. No additional serious block-related complications were observed in the study's patient group.

Limitations of the study include lacking the number of patients to detect rare block-related complications. Another limitation is that the effect of the blocks on ambulation pain and the length of hospital stay was not evaluated. Finally, patients who were receiving medicines, such as opioids or gabapentin, etc. before the operations could not be excluded from the study.

## CONCLUSION

The analgesic role of LESP block in hip fracture surgery seems promising. The LESP block provides sufficient postoperative analgesia comparable to the LPB. The prominent

advantages of the LESP block are that it is shallower than the LPB block, making it easier to perform and increasing the probability of a more extended analgesia area. Further studies are necessary to compare its effectiveness to other alternative block methods.

## ETHICAL APPROVAL:

The study was approved by the Institutional Ethical Board (Approval No: E-16214662-050.01.04-11637-27, Dated: 17.02.2021). The study was registered at the clinical trials.gov with the registry number: NCT05817916.

## PATIENTS' CONSENT:

Written informed consents were obtained from the patients before enrolment.

## COMPETING INTEREST:

The authors declared no conflict of interest.

## AUTHORS' CONTRIBUTION:

OB, AE: Conceptualisation, data curation, investigation, methodology, and writing of the original draft.

OP: Resources and software.

OB, OP: Formal analysis.

OB, AK: Project administration.

AK: Validation and visualisation.

AE, OP, AK: Writing, reviewing, and editing.

All authors approved the final version of the manuscript to be published.

## REFERENCES

1. Tang Y, Zhang X, Yi S, Li D, Guo H, Liu Y, *et al.* Ultrasound-guided pericapsular nerve group (PENG) block for early analgesia in elderly patients with hip fractures: A single-center prospective randomised controlled study. *BMC Anesthesiol* 2023; **23(1)**:383. doi: 10.1186/s12871-023-02336-1.
2. Veronese N, Maggi S. Epidemiology and social costs of hip fracture. *Injury* 2018; **49(8)**:1458-60. doi: 10.1016/j.injury.2018.04.015.
3. Anger M, Valovska T, Beloeil H, Lirk P, Joshi GP, Van de Velde M, *et al.* Prospect working group and the european society of regional anaesthesia and pain therapy. Prospect guideline for total hip arthroplasty: A systematic review and procedure-specific postoperative pain management recommendations. *Anaesthesia* 2021; **76(8)**: 1082-97. doi: 10.1111/anae.15498.
4. Shah SDBA, Khan TW, Gillani U, Durrani Z, Ayaz AKM, Khan S. Postoperative pain after hip surgery, is procedure specific. *J Med Sci Jan* 2016; **24(1)**:8-11.
5. Lee TY, Chung CJ, Park SY. Comparing the pericapsular nerve group block and the lumbar plexus block for hip fracture surgery: A single-centre randomised double-blinded study. *J Clin Med* 2023; **13(1)**:122. doi: 10.3390/jcm13010122.

6. Dong J, Zhang Y, Chen X, Ni W, Yan H, Liu Y, et al. Ultrasound-guided anterior iliopsoas muscle space block versus posterior lumbar plexus block in hip surgery in the elderly: A randomised controlled trial. *Eur J Anaesthesiol* 2021; **38(4)**:366-73. doi: 10.1097/EJA.0000000000001452.
7. Polania Gutierrez JJ, Ben-David B, Rest C, Grajales MT, Khetarpal SK. Quadratus lumborum block type 3 versus lumbar plexus block in hip replacement surgery: A randomised, prospective, non-inferiority study. *Reg Anesth Pain Med* 2021; **46(2)**:111-7. doi: 10.1136/rapm-2020-101915.
8. Balaban O, Aydin T. Lumbar erector spinae plane catheterisation for continuous postoperative Analgesia in total knee arthroplasty: A case report. *J Clin Anesth* 2019; **55**:138-9. doi: 10.1016/j.jclinane.2018.12.017.
9. Tulgar S, Aydin ME, Ahiskalioglu A, De Cassai A, Gurkan Y. Anesthetic techniques: Focus on lumbar erector spinae plane block. *Local Reg Anesth* 2020; **13**:121-33. doi: 10.2147/LRA.S233274.
10. Celik M, Tulgar S, Ahiskalioglu A, Alper F. Is high volume lumbar erector spinae plane block an alternative to transforaminal epidural injection? Evaluation with MRI. *Reg Anesth Pain Med* 2019; **16**:rapm-2019-100514. doi: 10.1136/rapm-2019-100514.
11. Sorenstua M, Zantalis N, Raeder J, Vamnes JS, Leonardsen AL. Spread of local anesthetics after erector spinae plane block: An MRI study in healthy volunteers. *Reg Anesth Pain Med* 2023; **48(2)**:74-9. doi: 10.1136/rapm-2022-104012.
12. Balaban O, Koculu R, Aydin T. Ultrasound-guided lumbar erector spinae plane block for postoperative analgesia in femur fracture: A Pediatric Case Report. *Cureus* 2019; **11(7)**:e5148. doi: 10.7759/cureus.5148.
13. Diwan S, Lonikar A, Dongre H, Sancheti P, Nair AS, Panchawagh S. Comparative study lumbar plexus block and lumbar erector spinae plane block for postoperative pain relief after proximal femoral nail for proximal femoral fractures. *Saudi J Anaesth* 2023; **17(2)**:147-54. doi: 10.4103/sja.sja.63022.
14. Wainwright TW, Gill M, McDonald DA, Middleton RG, Reed M, Sahota O, et al. Consensus statement for perioperative care in total hip replacement and total knee replacement surgery: Enhanced recovery after surgery (ERAS®) society recommendations. *Acta Orthop* 2020; **91(1)**:3-19. doi: 10.1080/17453674.2019.1683790.
15. Kaciroglu A, Ekinci M, Dikici M, Aydemir O, Demiroglu O, Erdogan D, et al. Lumbar erector spinae plane block versus infrainguinal fascia iliaca compartment block for pain management after total hip arthroplasty: A randomised clinical trial. *Pain Med* 2024; **25(4)**:257-62. doi: 10.1093/pm/pnad166.
16. Townsend D, Siddique N, Kimura A, Chein Y, Kamara E, Pope J, et al. Lumbar erector spinae plane block for total hip arthroplasty comparing 24 hour opioid requirements: A randomised controlled study. *Anesthesiol Res Pract* 2022; **3**:9826638. doi: 10.1155/2022/9826638.
17. Short AJ, Barnett JGG, Gofeld M, Baig E, Lam K, Agur AMR, et al. Anatomic study of innervation of the anterior hip capsule: Implication for image-guided intervention. *Reg Anesth Pain Med* 2018; **43(2)**:186-92. doi: 10.1097/AAP.0000000000000701.
18. Tran J, Peng PWH, Gofeld M, Chan V, Agur AMR. Anatomical study of the innervation of posterior knee joint capsule: Implication for image-guided intervention. *Reg Anesth Pain Med* 2019; **44(2)**:234-8. doi: 10.1136/rapm-2018-000015.
19. Ying H, Chen L, Yin D, Ye Y, Chen J. Efficacy of pericapsular nerve group block vs. fascia iliaca compartment block for hip surgeries: A systematic review and meta-analysis. *Front Surg* 2023; **10**:1054403. doi: 10.3389/fsurg.2023.1054403
20. Chen A, Kolodzie K, Schultz A, Hansen EN, Braehler M. Continuous lumbar plexus block vs. Continuous lumbar erector spinae plane block for postoperative pain control after revision total hip arthroplasty. *Arthroplast Today* 2021; **9**:29-34. doi: 10.1016/j.artd.2021.03.016.
21. Chan A, Ng TKT, Tang BYH. Single-shot lumbar erector spinae plane block in total hip replacement: A randomised clinical trial. *Anesth Analg* 2022; **135(4)**:829-36. doi: 10.1213/ANE.00000000000006162.

