

# Improvement of Esophageal Anastomotic Leak by Vacuum-assisted Closure in Three Cases with Gastric Cancer

Seracettin Egin and Semih Hot

*Department of Surgery, University of Health Sciences, Okmeydani Education and Research Hospital, Istanbul, Turkey*

## ABSTRACT

This case report presents three consecutive patients who developed esophageal anastomotic leak after gastric cancer surgery and were treated by the two-way vacuum-assisted closure with open abdomen technique in addition to endoscopic stent application (ESA). Esophageal anastomotic leak follow-up was performed by fluoroscopic fistulography. Total parenteral nutrition was given until cessation of leak. All applications of the two-way vacuum-assisted closure were carried out with a vacuum-assisted closure management system. In case of the improvement of the esophageal anastomotic leak detected by fluoroscopy, the two-way vacuum-assisted closure application was terminated. The subcutaneous layer was bilaterally dissected from the fascial layer of the anterior wall of the abdomen, and the abdominal skin was closed without tension. The combination of ESA and the two-way vacuum-assisted closure technique should be suggested in case of severe abdominal sepsis in patients with an esophageal anastomotic leak.

**Key Words:** *Open abdomen, Vacuum-assisted closure, Abdominal sepsis, Esophageal anastomotic leak.*

**How to cite this article:** Egin S, Hot S. Improvement of esophageal anastomotic leak by vacuum-assisted closure in three cases with gastric cancer. *J Coll Physicians Surg Pak* 2019; **29** (Supplement 2):S98-S100.

## INTRODUCTION

Esophageal anastomotic leak (EAL) is the most feared complication after gastric cancer surgery. Most leaks are limited, and can be treated conservatively with nasogastric aspiration, local percutaneous drainage, antibiotics and jejunal feeding. If there is persistent sepsis, an early reexploration is required. Esophageal stenting has been successfully used for the treatment of EAL. However, stenting is not always sufficient for control of the primary source and abdominal sepsis management. High mortality is usually caused by comorbidities and sepsis in patients undergoing relaparotomy. Conservative approaches should always be considered as the preferred treatment.<sup>1</sup> Indeed, reexploration is mandatory in case of wide dehiscence of anastomosis when conservative treatment is not sufficient. Controlled fistula formation, washing, drainage and nutrition jejunostomy might be performed during relaparotomy. Abdominal sepsis is a systemic inflammatory response of the host to bacterial or fungal peritonitis. Severe sepsis is described as sepsis associated with organ dysfunction or tissue hypo-perfusion.<sup>2</sup> The open abdomen (OA) technique is recommended as an important option in the surgical treatment of severe peritonitis.<sup>3</sup> Vacuum-

assisted closure (VAC) techniques have been extensively used in OA for temporary closure of the abdominal wall.

We, present three consecutive patients who developed EAL after gastric cancer surgery and were treated by the two-way VAC with OA technique in addition to ESA.

## CASE REPORT

The demographic data of three patients are shown in Table I, including type of operation of gastric cancers, histological type and tumour-nodes-metastasis (TNM) stage, the day of postoperative EAL and relaparotomy, the EAL diagnostic tool, the day of postoperative ESA and duration of stay, the postoperative day of the beginning of the two-way VAC, the two-way VAC application duration and number of applications, length of hospital stay, and length of intensive care unit (ICU) stay. The gastric tumours of the three patients were limited to the lesser curvature of the gastric corpus. The length of hospital stay was prolonged due to the development of a pancreatic fistula in the third patient.

Management of patients was carried out by applying the OA technique with the addition of a two-way VAC to the ESA. Our preference was primarily to perform ESA with coated stent during OA application. Afterwards, OA was carried out by closing with the two-way VAC technique. Although two-way VAC application for second and third patient was performed on the postoperative eighth and 12<sup>th</sup> day, respectively; ESA was delayed due to difficulties in supplying coated stents. ESA was performed on postoperative 17<sup>th</sup> day for the second

*Correspondence to: Seracettin Egin, Department of Surgery, University of Health Sciences, Okmeydani Education and Research Hospital, Istanbul, Turkey*  
*E-mail: seracettin\_egin@hotmail.com*

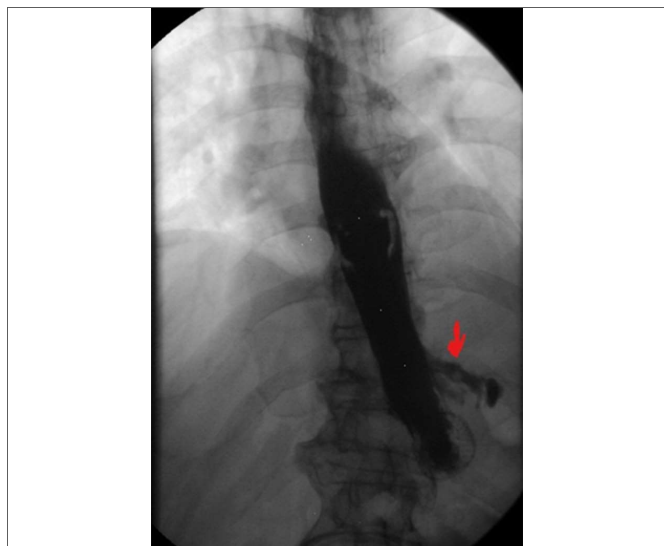
*Received: January 22, 2019; Revised: May 23, 2019;*

*Accepted: Jun 06, 2019*

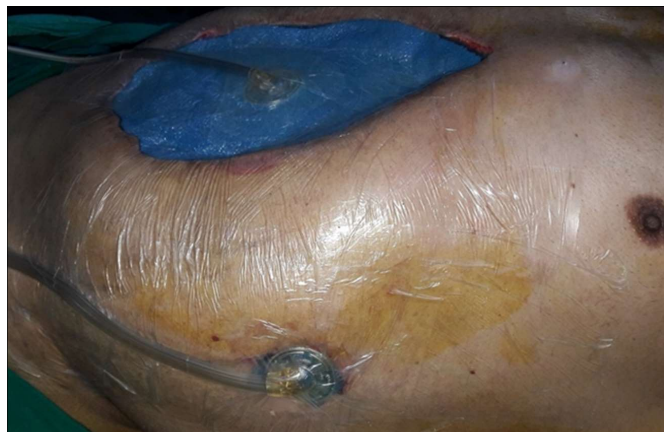**Table I:** Demographic and other relevant data of the three cases.

	Patient 1	Patient 2	Patient 3
Age (years)	55	44	68
Gender	Male	Female	Male
Type of operation	Total gastrectomy, D2 dissection, esophagojejunostomy	Proximal subtotal gastrectomy, esophagogastrostomy, caesarean section	Total gastrectomy, D2 dissection, esophagojejunostomy
Histological type	Well-differentiated adenocarcinoma	Undifferentiated carcinoma	Poorly differentiated adenocarcinoma
TNM stage	T1b N0 M0	T4b N1 M0	T3 N0 M0
Postoperative day of EAL and relaparotomy	6	8	12
Diagnosis tool of EAL	Contrast leak in ACT	Contrast leak in ACT	Bilious leak from the abdominal drain
Postoperative day of ESA	9 (uncovered stent) 15 (2 covered stent)	17 (covered stent)	15 (covered stent)
Duration of ESA (day)	19 (uncovered stent could not be removed)	24	96
Postoperative day of the two-way VAC	17	8	12
Duration of the two-way VAC	24	34	67
Number of the two-way VAC	7	9	12
Length of hospital stay (days)	60	46	144
Length of ICU stay (days)	5	8	38

TNM: Primary tumour (T), regional lymph nodes (N), distant metastasis (M), esophageal anastomosis leak (EAL), endoscopic stent application (ESA), vacuum-assisted closure (VAC), intensive care unit (ICU) and abdominal computerised tomography (ACT).



**Figure 1:** Fluoroscopic view of the third patient's anastomotic leak after application of covered stent.



**Figure 2:** External view of the two-way vacuum-assisted closure technique.

patient and on the 15<sup>th</sup> postoperative day for the third patient (Table I). The first patient was treated by another surgeon with planned relaparotomy technique from postoperative 6<sup>th</sup> day to 17<sup>th</sup> day and ESA was firstly performed with an uncovered stent on the postoperative 9<sup>th</sup> day during planned relaparotomy. Afterwards, second ESA was carried out with two covered stents, one inside, the other on the postoperative 15<sup>th</sup> day during planned relaparotomy. OA was performed with the two-way VAC technique on the 17<sup>th</sup> postoperative day (Table I).

In all applications of the two-way VAC, the intra-abdominal fluid culture was taken, and the intra-abdominal cavity washed with at least 6 L of saline solution. All applications of the two-way VAC were carried out with a VAC management system (ABThera Open Abdomen Management System; Kinetic Concepts Inc./Acelity, L.P. Inc., San Antonio, TX, USA). An Abthera system has one central sponge and six additional sponge extensions. All the sponges are covered with visceral organ protective layers. One of the additional sponge extensions was extracted from the management system. One tip of the extracted additional sponge extension was placed next to the anastomosis under the left diaphragm, and the other tip was taken out of the left upper quadrant. Five additional sponge extensions are embedded completely of the intra-abdominal cavity after washing with at least six liters warm serum saline. An elliptical uncovered sponge is applied above five additional sponge extensions. The back face of the elliptical uncovered sponge is at the fascia level and its front face is at the level of the skin. The elliptical uncovered sponge and skin of abdomen are covered by the physician with sterile and adhesive drape. It is connected with 75 mmHg negative pressure to vacuum device *via* a collecting system. Afterwards, the other tip that was

taken out of the left upper quadrant is covered by the physician with sterile and adhesive drape and is also connected with 75 mmHg negative pressure to second vacuum device via a collecting system.

The EAL follow-up was performed by fluoroscopic fistulography (Figure 1). The external appearance of the two-way VAC application can be seen in Figure 2. The two-way VAC applications were carried out with 3-5-day intervals. In the absence of mucus or biliary debris and contamination under the left diaphragm during the applications, fluoroscopic imaging with the contrast of upper gastrointestinal system was performed prior to the next application. In case, where the improvement of the esophageal anastomotic leak was detected by fluoroscopy, the two-way VAC application was terminated. The abdomen was not closed unless the EAL was terminated in fluoroscopy. Until then, the stents had not been removed. Total parenteral nutrition was performed until the end of EAL. The subcutaneous layer was bilaterally dissected from the fascial layer of the anterior wall of the abdomen, and the abdominal skin was closed without tension. The abdominal skin of the third patient was closed on the 79<sup>th</sup> postoperative day. However, the drain in the upper left quadrant placed for the pancreatic fistula was extracted on the 130<sup>th</sup> postoperative day, on which the pancreatic was fistula closed.

## DISCUSSION

The two-way VAC technique can localise peritoneal contamination by creating a separate channel for the EAL. Peritoneal contamination can be limited to a narrow area under the diaphragm, and the EAL will not infect the intra-abdominal cavity. VAC accelerates granulation and rapidly and completely closes the leak. The two-way VAC technique described here was successful in the three consecutive cases reported here. Using this technique, in the last 2 years, no patient has died in our surgery department due to the EAL that developed after gastric cancer surgery. To our knowledge, there has been no similar report in the literature.

Mediastinitis is often fatal in cases of EAL. The best results can be achieved in leaks occurring during the very early postoperative phase with a covered self-expanding stent following gastric cancer surgery.<sup>4</sup> However, radiological drainage or surgical re-exploration should be performed in case of delayed leaks.<sup>5</sup> Actually, the high mortality rate related to reoperation is due to the comorbidities of patients undergoing relaparotomy.<sup>5</sup> The two-way VAC technique does not add additional morbidity to the comorbidities of patients. This technique does not include any secondary surgical operation. This includes irrigation and aspiration of the intra-abdominal

cavity and a VAC application. The ESA should be performed in the early period of the EAL. The high mortality rate in patients with the EAL might be reduced by the combined use of the ESA and OA technique with the two-way VAC application. We suggest using a combination of ESA and two-way VAC because of the success in our three successive patients with the EAL.

In conclusion, the two-way VAC applications provide severe abdominal sepsis treatment and primary source control of infection, as well as accelerating granulation tissue development and rapidly closing the EAL. The combination of ESA with the two-way VAC technique should be suggested in case of severe abdominal sepsis in patients with EAL.

## PATIENTS' CONSENT:

We state that informed consents were obtained from three patients to publish the data concerning these cases.

## CONFLICT OF INTEREST:

Authors declared no conflict of interest.

## AUTHORS' CONTRIBUTION:

SE: Surgical and medical practices, literature search, conception or design of the work, data collection, data analysis and interpretation, drafting the article, final approval of the version to be published.

SH: Surgical and medical practices, data analysis and interpretation, critical revision of the article.

## REFERENCES

1. Sano T, Sasako M, Yamamoto S, Nashimoto A, Kurita A, Hiratsuka M, *et al.* Gastric cancer surgery: Morbidity and mortality results from a prospective randomized controlled trial comparing D2 and extended para-aortic lymphadenectomy-Japan Clinical Oncology Group study 9501. *J Clin Oncol* 2004; **22**:2767-73.
2. Dellinger RP, Levy MM, Carlet JM, Bion J, Parker MM, Jaeschke R, *et al.* Surviving sepsis campaign: International guidelines for management of severe sepsis and septic shock: 2008. *Crit Care Med* 2008; **36**:296-327.
3. Coccolini F, Montori G, Ceresoli M, Catena F, Moore EE, Ivatury R, *et al.* The role of open abdomen in non-trauma patient: WSES Consensus Paper. *World J Emerg Surg* 2017; **12**:39.
4. Hoepfner J, Kulemann B, Seifert G, Marjanovic G, Fischer A, Hopt UT, *et al.* Covered self-expanding stent treatment for anastomotic leakage: Outcomes in esophagogastric and esophagojejunal anastomoses. *Surg Endosc* 2014; **28**:1703-11.
5. Aurello P, Magistri P, D'Angelo F, Valabrega S, Sirimarco D, Tierno SM, *et al.* Treatment of esophagojejunal anastomosis leakage: A systematic review from the last two decades. *Am Surg* 2015; **81**:450-3.

....☆....