

Rectal Duplication Cyst: A Rare Cause of Rectal Prolapse in a Toddler

Samreen Khushbakht and Anwar ul Haq

ABSTRACT

Rectal duplication cysts are rare congenital anomalies. They constitute only 4% of the total gastrointestinal anomalies. They usually present in childhood. The common presenting symptoms are mass or pressure effects like constipation, tenesmus, urinary retention, local infection or bleeding due to presence of ectopic gastric mucosa. We are reporting a rare presenting symptom of rectal duplication cyst in a 4-year-old boy/toddler who presented with rectal prolapse. He also had bleeding per rectum. Rectal examination revealed a soft mass palpable in the posterior rectal wall. CT scan showed a cystic mass in the posterior wall of the rectum. It was excised trans-anally and the postoperative recovery was uneventful. Biopsy report showed rectal duplication cyst.

Key Words: Rectal duplication cyst. Rectal prolapse. Rectal bleeding.

INTRODUCTION

Rectal bleeding and prolapse are common presenting features in children having rectal polyp. They are easy to diagnose by digital rectal examination or by sigmoidoscopy as 90% are in recto-sigmoid region. But a rare cause of rectal prolapse or bleeding is rectal duplication cyst which must be borne in mind while one finds an unusual mass on digital rectal examination. Rectal duplication cysts are one of the rare duplication anomalies of intestinal duplication making only 4% of all duplication cysts.

They were first described by Ladd and Gross in 1941 as cysts having mucosal lining and smooth surface forming their wall with adherence or connection to gastrointestinal tract.¹ The most common site of duplication is small intestine accounting 44%, colon forming 15% and rectum contributing only 4% of all duplication anomalies.² They commonly present in childhood with features of mass effect or local pressure effects like tenesmus, constipation, urinary retention, local infection, bleeding due to presence of ectopic gastric mucosa or malignancy in case of delayed diagnosis.³ Rectal prolapse is one of the rare presenting features of rectal duplication cyst.

Here we are reporting a 4-year-old boy who presented with history of on and off constipation for the last 1 month, associated with rectal bleeding and prolapse defecation.

CASE REPORT

A 4-year-old boy was referred to pediatric surgical clinic with complaints of rectal prolapse and bleeding. An

Department of Pediatric Surgery, Shifa International Hospital, Islamabad.

Correspondence: Dr. Anwar Ul Haq, Department of Paediatric Surgery, Shifa International Hospital, Islamabad.

E-mail: drahaq@hotmail.com

Received: February 10, 2014; Accepted: December 31, 2014.

impression of rectal polyp was already given by the referring physician. Patient gave history of on and off constipation associated with rectal bleeding in copious amount and something coming out of anus at the time of defecation. There was no associated vomiting, fever or abdominal pain.

Abdominal examination did not show any positive finding. On inspection, the perianal skin showed no obvious lesion or evidence of bleeding. On digital examination, the sphincter tone was found normal. There was a well-defined, sessile and broad-based palpable soft tissue mass (3 cm in size) in the posterior wall of rectum, the overlying mucosa was smooth and firmly adherent to it. Anterior rectal wall was normal. The differential diagnoses of polyp, rectal duplication cyst and cystic teratoma were considered.

Baseline blood tests were within normal limits. CT scan with contrast showed a well-defined rounded hypodense soft tissue mass in the pre-coccygeal area to the right of midline at ano-rectal junction abutting and compressing contrast filled rectum, not separable from its wall (Figure 1). The differential diagnoses then included rectal duplication cyst, rectal polyp, exophytic lesion and neurogenic tumor.

In the light of clinical and CT scan findings, the lesion was considered to be a rectal duplication cyst and surgical excision was planned.

Pre-operative mechanical bowel preparation was performed. At the time of surgery, patient was put in lithotomy position. Rectal examination was performed to evaluate the extent of lesion. A trans-anal excision of the lesion was planned. A semi-circular incision was made on the overlying mucosa. The mucosal flap was raised and cyst was dissected out underneath it from surrounding wall of rectum and excised with intact capsule (Figure 2). Hemostasis was secured using bipolar diathermy. The mucosal flap was repositioned

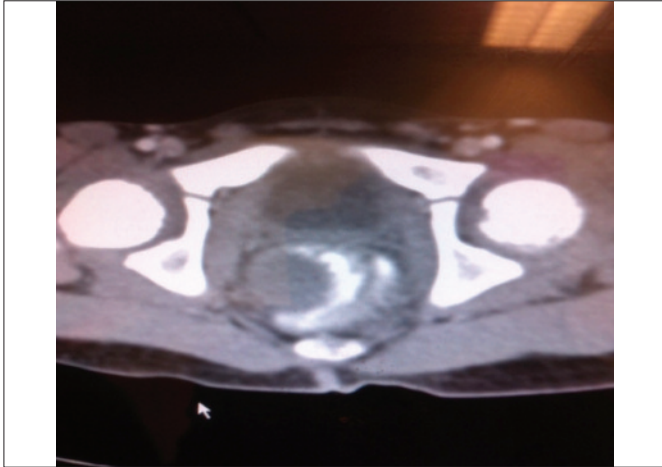


Figure 1: A rectal duplication cyst bulging into the contrast-filled rectal lumen as a filling defect.

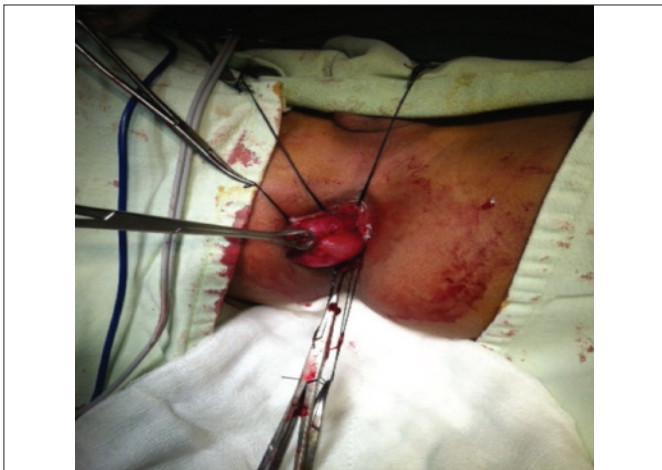

Figure 2: Cyst dissected out free from the rectal wall.

back to its normal place and repaired with vicryl interrupted sutures. After excision the cyst was opened, it contained thick tenacious white mucus.

Postoperatively child remained well. He was kept nil per oral overnight, feeding was started in the morning. He passed stool the day after surgery and was discharged home on 2nd postoperative day in stable condition, with the advise regarding perineal hygiene and high fiber diet.

Histopathology reported the cyst wall as fibromuscular layer lined by columnar epithelium, consistent with a duplication cyst. No evidence of malignancy was seen.

DISCUSSION

Rectal duplication cysts are very rare congenital anomalies, requiring a high index of suspicion for correct diagnosis. There is no definite etiology for these duplication cysts. Some of the likely causes are a split notochord, partial or attempted twinning, persistent diverticula or aberrant luminal recanalization and rarely intrauterine hypoxia; trauma is also listed in its causes.⁵

Clinical presentation of rectal duplication is bimodal, either they present in perinatal period or in childhood.⁷ They can present in many ways like bleeding, infection, fistula, rectal polyp, rectal prolapse or with features of mass effect leading to obstructive symptoms like constipation, tenesmus and painful defecation. Most of the cysts are located in the posterior wall of the rectum, i.e. pre-sacral (retro-rectal) area; anterior wall cysts are very rare.

Symptoms depend upon the size of the cyst. Diagnosis can be made with the help of clinical evaluation, digital rectal examination, CT scan and/or MRI. A number of other lesions may have similar presentation, e.g. teratoma, neurogenic tumor, chordoma etc. So final diagnosis can only be made per-operatively, although CT scan is considered as the gold standard investigation.⁸

The primary treatment for duplication cyst is complete surgical excision with preservation of anorectal anatomy.⁹ There are different approaches for its excision. The choice depends on its anatomical location, ease of surgeon and personal preference. Most commonly used and recommended approach is posterior sagittal excision (trans-sacral approach). Others are transanal (as used in this case), transcoccygeal, or abdominoperineal. Nowadays, laparoscopic excision is also practiced.^{9,10} Early and complete excision is the goal as in long standing cases there are chances of malignant degeneration.

REFERENCES

1. Jackson KL, Peche WJ, Rollins MD. An unusual presentation of rectal duplication cyst. *Int J Surg* 2012; **3**:314-5.
2. Ladd WE, Gross RE. Duplication of the alimentary tract. *South Med J* 1937; **30**:363.
3. Kocaoglu M, Frush DP. Pediatric presacral masses. *Radio Graphics* 2001; **21**:575-84.
4. Flint R, Strang J, Bissett I, Clark M, Neill M, Parry B. Rectal duplication cyst presenting as perianal sepsis: report of two cases and review of the literature. *Dis Colon and Rectum* 2004; **47**:2208-10.
5. Bentley JFR, Smith JR. Developmental posterior enteric remnants and spinal malformations. *Arch Dis Child* 1960; **35**: 76-86.
6. Kimberly H, Kishore V. Rectal duplication cyst in a 12-year-old female presenting with chronic constipation and rectal bleeding: a case report. *Int J Clin Med* 2011; **2**:5-8.
7. Gupta V, Sharma SB. Cystic rectal duplication in infants: a case report and review of literature. *J Indian Assoc Pediatr Surg* 2006; **11**:153-4.
8. Mehta MH, Mehta SD, Trivedi PS, Patel RV. Pararectal duplication. *Indian J Med Sci* 1992; **46**:83-5.
9. Hartin CW, Lau ST, Escobar MA, Glick PL. Laparoscopic excision of a newborn rectal duplication cyst. *J Pediatr Surg* 2008; **43**:1572-4.
10. Ben-Ishay O, Person B, Eran B, Hershkovitz D, Duek DS. Rectal duplication cyst in adults treated with transanal endoscopic microsurgery. *Tech Coloproctol* 201; **15**:469-71.

