

# Isoniazid Induced Acute Pancreatitis in a Young Girl

Ali Faisal Saleem, Saba Arbab and Farah Qamar Naz

## ABSTRACT

Isoniazid (INH) is the mainstay of management against *Mycobacterium tuberculosis*. INH-induced acute pancreatitis is an uncommon association and with dearth of literature on it. We are reporting a case of an 11 years old girl who developed acute pancreatitis after 2 weeks of antituberculous therapy. An INH free regimen was started. She was discharged and followed without complications.

**Key Words:** Isoniazid. Acute pancreatitis. Anti-tuberculous therapy.

## INTRODUCTION

Pakistan has high tuberculosis burden. There were more than two hundred and fifty thousand TB cases reported from Pakistan in 2010 and 10% of them were of childhood tuberculosis. Childhood TB is a reflection of TB control in a population, because it represents the infectious adult with pulmonary disease that transmit to the children.<sup>1</sup> Isoniazid and rifampicin are the backbone of TB treatment.

INH is the first line Antituberculous Therapy (ATT) and was introduced in 1952. It is bactericidal and acts by inhibiting synthetic pathways of mycolic acid and metabolized via liver by hepatic N-acetyltransferase.<sup>2</sup> INH has infrequent major adverse effects, including hepatitis, peripheral neuropathy, hypersensitivity reactions (fever, skin eruptions or hematologic alterations along with lupus-like syndrome that is reversible on discontinuation of INH.<sup>2,3</sup> The most notable adverse effect is hepatitis. The estimated rate of clinical hepatitis in patients given INH alone is approximately 0.6%.<sup>4</sup>

Acute pancreatitis is rarely caused by medications with an estimated incidence of 0.1 - 2%.<sup>5</sup> Isoniazid is a rare cause of acute pancreatitis,<sup>6,7</sup> and rarely reported in children. We are reporting here a case of young girl who developed acute pancreatitis within 2 weeks of her ATT.

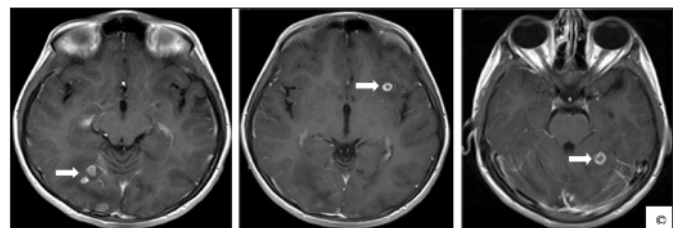
## CASE REPORT

An 11 years old girl, weighing 25 kilograms, resident of Karachi, presented in the emergency room with generalized tonic clonic seizures for one day. She had suffered from focal afebrile seizures for the last 4 - 5 days and had received treatment from nearby hospital.

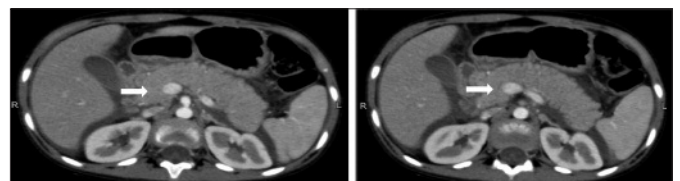
She had low grade undocumented fever for 3 weeks and history of weight loss along with poor appetite and anorexia prior to this afebrile seizure episodes. Her father had been treated for pulmonary tuberculosis 4 years back on the basis of radiological grounds only.

Her workup for seizures included normal electrolytes; Electroencephalogram (EEG) which showed right sided multifocal spikes and slow waves discharge; and MRI-brain showing bilateral ring enhancing lesions at both cerebral hemispheres and left cerebellar hemisphere (Figure 1). Her chest X-ray showed hilar lymphadenopathy. Montoux test was negative. Her ESR was normal. She was started on first line ATT regimen (isoniazid, rifampicin, pyrazinamide and ethambutol (mg/kg - H<sub>10</sub>R<sub>15</sub>Z<sub>30</sub>E<sub>15</sub>) along with prednisolone and mucosal protective agent. She was also started on levetiracetam after paediatric neurological opinion and discharged home after a week of admission. She remained well, seizure free and started gaining weight (800 grams in a week) in her first week follow-up in the clinic.

Within 2 weeks of discharge, she presented to the emergency room with severe central abdominal pain and vomiting without any fever. She denied any urinary



**Figure 1:** MRI brain showing multiple ring enhancing lesion in bilateral cerebral hemisphere and left cerebellar hemisphere © (arrow indicate tuberculomas).



**Figure 2:** CT abdomen: Arrows showed significantly swollen pancreas with peri-pancreatic free fluid.

Department of Paediatrics and Child Health, The Aga Khan University Hospital, Karachi.

Correspondence: Dr. Farah Naz Qamar, 107-B, Muhammad Ali Society, Karachi.

E-mail: farah.qamar@aku.edu

Received: May 07, 2012; Accepted: August 13, 2014.

complaints and had normal bowel movements. Remaining aspects of her history were unremarkable. She was vitally stable with no icterus and skin rashes. Her abdominal examination revealed epigastric tenderness without rebound and mild guarding. Rest of her systemic examination was unremarkable. She was worked up for acute abdomen. She had normal liver functions; however, serum amylase was high (2862 IU/L (normal 25 - 100), serum lipase was 1379 IU/L (normal 28 - 100). Her CT abdomen (Figure 2) showed swollen head, body and tail of pancreas with signs of acute pancreatitis. Her ATT and levetiracetam was stopped, considering drug induced pancreatitis. She was put on conservative management including nothing per oral and total parenteral nutrition. Her ATT was temporarily switched to intravenous rifampicin, levofloxacin, amikacin and streptomycin (intramuscular) for a week and she was allowed orally only for medications and her first line oral ATT was restarted (except INH) gradually. Within 7 days she was on RZE.

Her laboratory profile was followed 72-hourly that gradually normalized. Her diet was gradually improved to soft diet. Her review ultrasound showed resolving inflammation. After 2 weeks of admission, her enzyme level became normal and levetiracetam was restarted. Her serum amylase and lipase were followed twice a week and no abnormalities were detected. She was discharged home on RZES (rifampicin, pyrazinamide, ethambutol and streptomycin) for 2 months along with levetiracetam with completion of the regimen with RZE for 10 months. She was followed in the clinic and remained asymptomatic.

### DISCUSSION

INH-induced acute pancreatitis is a rare complication, that usually occur after within 3 - 4 weeks of therapy and reversed by withdrawal of the medicine; however the symptoms recurs with drug re-challenge as reported in the literature.<sup>3,8</sup> This patient developed symptoms within 2 weeks of therapy and her pancreatic enzymes returned to normal within 2 weeks post-withdrawal of isoniazid. INH and rifampicin both are associated with acute pancreatitis,<sup>9</sup> but it is extremely rare to have acute pancreatitis because of rifampicin. There are only few reported cases of isoniazid induced acute pancreatitis, but none in children. Identifying cases of isoniazid-induced acute pancreatitis is vital because the development of this condition might be erroneously recognized

either as an effect of the underlying illness or to some other medications.<sup>3</sup> Correct and early recognition with prompt drug withdrawal are necessary since drug induced acute pancreatitis is potentially reversible and mandates permanent avoidance of isoniazid.<sup>7,8</sup> With the presence of possible confounding effect of rifampicin, correct recognition of INH-induced acute pancreatitis becomes even more vital, since it is an essential part of first line regimen of ATT. The exact mechanism of acute pancreatitis remains unclear. A dose-dependent manner on the first encounter or a possibility of a hypersensitivity syndrome against INH after a re-challenge has been suggested.<sup>3,8,10</sup> Isoniazid toxicity can be prevented by using therapeutic range and screening of known risk factors (liver or renal disease). Importantly, INH induced hepatitis and pancreatitis can be completely recovered if the drug is withdrawn early.<sup>9</sup> A high index of suspicion and early withdrawal of isoniazid is the key to avoiding hazardous consequences.

### REFERENCES

1. Shingadia D. Tuberculosis in childhood. *Lancet Infect Dis* 2003; **3**:624-32.
2. Wallace RJ, Griffith DE. Antimycobacterial agents. In: Mandell GL, Bennett JE, Dolin R. Mandell, Douglas, Bennett's. Principles and practice of infectious diseases. 7th ed. Philadelphia: Churchill Livingstone; 2009.p. 533-47.
3. Rabassa AA, Trey G, Shukla U, Samo T, Anand BS. Isoniazid-induced acute pancreatitis. *Ann Intern Med* 1994; **121**: 433-4.
4. Mitchell JR, Zimmerman HJ, Ishak KG, Thorgeirsson UP, Timbrell JA, Snodgrass WR, *et al.* Isoniazid liver injury: clinical spectrum, pathology, and probable pathogenesis. *Ann Intern Med* 1976; **84**:181-92.
5. Balani AR, Grendell JH. Drug-induced pancreatitis : incidence, management and prevention. *Drug Saf* 2008; **31**:823-37.
6. Kaurich T. Drug-induced acute pancreatitis. *Proc (Bayl Univ Med Cent)* 2008; **21**:77-81.
7. Pandey AS, Surana A. Isoniazid-induced recurrent acute pancreatitis. *Trop Doct* 2011; **41**:249-50.
8. Chow KM, Szeto CC, Leung CB, Li PK. Recurrent acute pancreatitis after isoniazid. *Neth J Med* 2004; **62**:172-4.
9. Chan TY. Isoniazid and rifampicin rarely cause acute pancreatitis in patients with tuberculosis. *Int J Clin Pharmacol Ther* 1999; **37**:109.
10. Stephenson I, Wiselka MJ, Qualie MJ. Acute pancreatitis induced by isoniazid in the treatment of tuberculosis. *Am J Gastroenterol* 2001; **96**:2271-2.

