

# Spontaneous Fistulization of Hepatic Hydatid Cyst into the Duodenum: An Exceptional Complication

Sami Daldoul, Amir Moussi and Abdeljelil Zaouche

## ABSTRACT

Hydatid disease is a worldwide zoonosis and is localized in the liver in most cases. Its complications are numerous and include those related to the compression of adjacent viscera, infection of the cyst's contents or perforation of the cyst. Spontaneous rupture of the hepatic hydatid cyst into the duodenum is an extremely rare complication. The communication is, typically, not discovered until surgery. We present two cases of perforation of a liver cyst into the duodenum. One of them was diagnosed pre-operatively by a barium study. The surgical treatment of the lesion and its complications was complex but successful in both cases.

**Key words:** *Hydatid cyst. Liver. Duodenum. Fistula. Echinococcosis.*

## INTRODUCTION

Hydatid disease is an anthroponoses that is rife in an endemic mode in the great grazing regions of the world particularly the Mediterranean region, South America and Australia.<sup>1</sup> It is produced by the larval stage of the *Echinococcus granulosus*. It is characterized by its large clinical polymorphism and the gravity of its complications.

Duodenal fistulization is an extremely rare complication of this disease.<sup>1</sup> The diagnosis is hardly ever made in pre-operatively and poses a challenge in the choice of the surgical management.

We hereby, describe two cases of duodenal fistulization of hepatic hydatid cyst.

## CASE REPORT

**Case 1:** A 28 years old patient was admitted to the hospital because of right upper quadrant pain and vomiting of 30 days duration. She underwent surgery for hydatid cysts of the right hepatic lobe and recurrent hydatid cysts successively in 1992 and 1996. Physical examination revealed tenderness in the right hypochondrium and right lumbar fossa with lumbar contact. Laboratory studies revealed a white blood cell count of 11300/ $\mu$ l, with 18% eosinophils. Biochemistry revealed a creatinine level of 150  $\mu$ mol/l. Abdominal CT scan showed a multilocular hydatid cyst of the liver, developed in the posterior part of the lateral sector of

the right lobe compressing the right supra hepatic vein and extended into retroperitoneum where it stamps down the right kidney. A second hydatid cyst was found in the segments I and V of the liver compressing the duodenum with a distended stomach (Figure 1).

During her hospitalization, the patient developed an anaphylactic reaction with diarrhea raising the suspicion of rupture in the digestive tract. A barium swallow X-ray study was performed, showing the opacification of the hydatid cavity through a duodenal fistula near the pylorus (Figure 2).

The patient underwent a laparotomy, finding an enormous, single multilobular hydatid cyst. This cyst was developed in the posterior part of the lateral sector of the right lobe and was extended behind the hepatic pedicular. It was in close contact with the duodenum. The cyst was filled with a purulent fluid. Cystic exploration found a duodenal fistula affecting the posterior wall of the first duodenal knee. The peroperative cholangiogram showed a retrograde opacification of the cyst through the duodenal fistula (Figure 3). We performed a large resection of the prominent cystic dome with a cholecystectomy. Concerning the duodenal fistula, a duodenostomy was carried out associated with a gastrostomy and a jejunostomy. The drainage tubes were removed 6 weeks later and the patient was discharged.

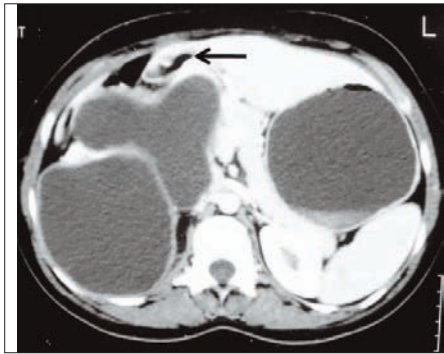
**Case 2:** A 63 years old woman presented to the emergency department for a right upper quadrant pain of 24 hours duration with fever and chills. Physical examination revealed the temperature as 38.6°C and an abdominal involuntary guarding in the right hypochondrium. Laboratory data showed a white blood cell count of 13700/ $\mu$ l, with 92% neutrophils, serum urea nitrogen level of 6.5 mmol/l, total bilirubin of 10 mg/dl and prothrombin time of 19.6 seconds. Ultrasonography

*Department of General Surgery, Charles-Nicole's Hospital, Faculty of Medicine, University of Tunis El Manar, Tunis, Tunisia.*

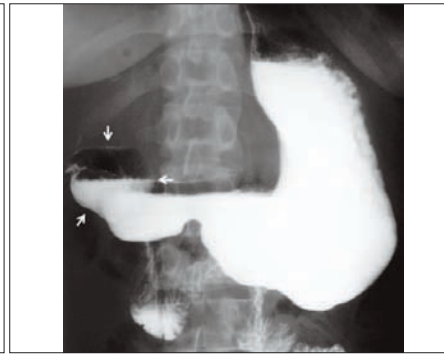
*Correspondence: Dr. Sami Daldoul, Department of General Surgery, Charles-Nicole's Hospital. Boulevard 9-avril-1938, 1006, Tunis, Tunisia.*

*E-mail: samidaldoul@yahoo.fr*

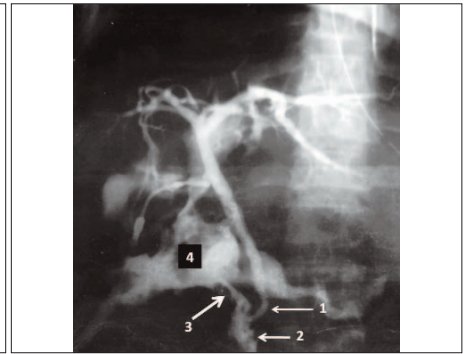
*Received: September 21, 2011; Accepted: August 11, 2012.*



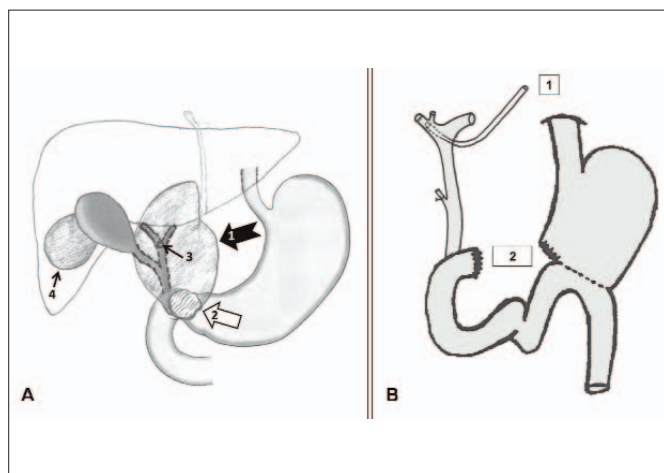
**Figure 1:** Abdominal CT scan: Hydatid cyst of the liver compressing the duodenum (arrow).



**Figure 2:** Barium swallow X-ray study: Opacification of the hydatid cavity through a duodenal fistula near the pylorus (arrows).



**Figure 3:** Peroperative cholangiogram: Retrograde opacification of the cyst through the duodenal fistula: Common bile duct (arrow 1), Duodenum (arrow 2), Duodenal fistula (arrow 3), Residual cavity of the hydatid cyst (4).



**Figure 4:** **A.** Reports of hydatid cysts: Hydatid cyst in the underside of the segment IV (arrow 1), A wide communication with the first duodenum (arrow 2), A large fistula with the superior biliary confluence (arrow 3), Hydatid cyst in the segment V of the liver (arrow 4). **B.** Surgical procedure: Biliary fistula transformed to a hepaticostomy through an external drainage (1), Duodenal diverticulization (2).

revealed two multivesicular hydatid cysts in the segments IV and VI of the liver. They measured 5 and 6 cm respectively.

Emergency laparotomy was carried out under the diagnosis of infected hydatid cyst. The patient was operated on through a bilateral subcostal laparotomy, finding two cysts of 8 and 5 cm in diameter. The smaller was situated in the segment V. It was treated by a resection of the dome. The second was located in the underside of the segment IV and was in a close contact with more than 5 cm from the pylorus to the first duodenum knee. Its content was infected. Exploration of the cystic cavity revealed a wide communication with the first duodenum affecting its anterior hemi-circumference offering no possibility of repair and a large fistula with the confluence of the hepatic biliary ducts (Figure 4A). The digestive defect was repaired by a duodenal diverticulization and the biliary fistula was transformed to a hepaticostomy through an external drainage (Figure 4B). The patient was discharged after 3 weeks.

## DISCUSSION

Hydatid cyst is due to implantation and development of an *Echinococcus granulosus* in the hepatic parenchyma. The natural history of this zoonosis is interspersed by many serious complications dominated by rupture and secondary infection.<sup>2-4</sup> The rupture of the hydatid cyst is probably the most common complication of liver hydatid disease, appearing in about 15% of all cases.<sup>2,3,5,6</sup> It frequently occurs into the biliary tree (communicating rupture) causing icterus and often a very serious acute cholangitis; or into the free peritoneal cavity with seeding daughter cysts in the peritoneum (direct rupture).<sup>2,3</sup> In these cases, rupture is associated with a high death rate.<sup>4</sup>

Spontaneous rupture of hydatid cyst into hollow viscus is an extremely rare complication and the most common site of perforation is into the stomach.<sup>3,5,7</sup> Only 0.29% of the operated hepatic hydatidosis were perforated into the gastrointestinal tract and only 0.15% presents duodenal fistulization.<sup>4</sup> A similar result was seen in Zauouche's multicentric study in which out of 2013 cases of hydatid cyst of the liver, only 3 cases of rupture into the digestive tract were found of which two of them were in the duodenum.<sup>1</sup> The communication between hydatid cyst and digestive tract occurs when the cyst is located on the inferior surface of the liver. In these cases, the stomach and the duodenum may be affected too.<sup>7</sup> This location was found in these two patients. Two other conditions are required.<sup>1,5,7</sup>

One is infection of the cyst content and swelling of the outer membranes giving rise to adhesion formation between the cyst and the surrounding organs. This was the case with these two patients where the contents of the cysts were infected.

The second mechanism is a continuous mechanical friction by a thick or calcified pericyst progressively eroding the hollow viscus wall.

Sometimes, the initial pathology is not an infection of the cyst but an alteration of the duodenum wall, for instance

a peptic ulcer.<sup>3</sup> This complication may be accompanied by various clinical findings. So, the passage of hydatid membranes in the stools (hydatidorrhea or hydatidenteria) and the presence of hydatid cyst as well as the membranes in the vomit (hydatidemesia) can be detected.<sup>1-3,5,8</sup> However, the clinical presentation can be resumed to non-specific signs as abdominal discomfort or pain, dyspepsia or fever.<sup>2,5</sup>

Typically, the communication is not discovered until surgery, although it may be found on radiological examination in some cases. CT scan can visualize a cyst with an air-fluid level or an orally administered contrast material inside the cavity which is in a close contact with the digestive tract.<sup>5,8</sup> Barium-enhanced CT or study with barium contrast performed with patient in the left or right lateral decubitus position may demonstrate the fistula between the cyst and the hallow viscus.<sup>8,9</sup> This examination enabled the diagnosis in Case 1 when it showed the opacification of the cyst from the duodenum.

Surgical management of fistulized hydatid cyst into the duodenum is required since cyst content was often infected and spontaneous debridement of the cavity was not complete.

Surgical procedure depends on the view of hallow viscus damage. It includes logout of cysto-digestive fistula, treatment of the parasite and repair of the duodenal sinus.

If the duodenal defect is small, duodenal gap would be sutured and associated to a gastric aspiration.<sup>1,3,5</sup> Otherwise, when duodenal wall dilapidation is very important, the defect will be transformed to a directed fistula associated to the derivation of the upper digestive tract (gastro-entero-anastomosis, pyloric exclusion from VAUGHAN).<sup>1</sup> Surgical reparation could be difficult and complex when the duodenal defect is associated with impacted calcified pericyst to the duodenal wall.

Concerning our two patients, the therapeutic management of the duodenal fistula was effectively influenced by the local inflammatory condition (Case 1) and the importance of the wall defect (Case 2). We opted for a duodenostomy by a direct fistulization through a Pezzer probe in Case 1 since the suture was random in this

inflammatory atmosphere and for a duodenal diverticulization in Case 2 as the duodenal defect was important and would not lend itself to reparation.

Fistulization of the hepatic hydatid cyst into the duodenum is an exceptional complication of the hydatid disease. The hydatidemesia and the hydatidorrhea made the diagnosis but these clinical presentations are rare. The barium-enhanced CT and the study with barium contrast can confirm the diagnosis and may demonstrate the fistula. But often, this communication is discovered at laparotomy. Surgical reparation could be difficult and may include complex procedures. The prognosis depends essentially on the severity of the duodenal wall damage.

## REFERENCES

1. Zaouche A, editor. Liver hydatid surgery: about 2013 case. Tunis: Tunisian Association for Surgery; 1994.
2. Lo Casto A, Salerno S, Grisanti M, Mastrandrea G. Hydatid cyst of the liver communicating with the left colon. *J Radiol* 1997; **70**:650-1.
3. Diez Valladares L, Sanchez-Pernaute A, Gonzalez O, Perez-Aguirre E, Talavera P, Gutierrez del Olmo A, *et al.* Hydatid liver cyst perforation into the digestive tract. *Hepatogastroenterology* 1998; **45**:2110-4.
4. Noguera M, Alvarez-Castells A, Castella E, Gifre L, Andreu J, Quiroga S. Spontaneous duodenal fistula due to hepatic hydatid cyst. *Abdom Imaging* 1993; **18**:234-6.
5. Nouira K, Hila H, Bedioui H, Baccar S, Ben Messaoud M, Ksantini R, *et al.* Rupture of hydatid cyst of the liver into the duodenum: a case report. *Tunis Med* 2007; **85**:979-81.
6. Zaouche A, Haouet K, Jouini M, El Hachaichi A, Dziri C. Management of liver hydatid cysts with a large bilio-cystic fistula: multicenter retrospective study; Tunisian Surgical Association. *World J Surg* 2001; **25**:28-39.
7. Hankins JR. Management of complicated hepatic hydatid cysts. *Ann Surg* 1963; **158**:1020-34.
8. Pedrosa I, Saíz A, Arrazola J, Ferreirós J, Pedrosa CS. Hydatid disease: radiologic and pathologic features and complications. *Radiographics* 2000; **20**:795-817.
9. Ruiz-Rabelo JF, Gomez-Alvarez M, Sanchez-Rodriguez J, Rufian Peña S. Complications of extra-hepatic echinococcosis: fistulization of an adrenal hydatid cyst into the intestine. *World J Gastroenterol* 2008; **14**:1467-9.

