

Anaesthetic Management of Abdominal Hysterectomy in Patient with Congenital Sinus Node Dysfunction

Dileep Kumar and Faisal Shamim

ABSTRACT

A 45 years old woman having dysfunctional uterine bleeding was scheduled for total abdominal hysterectomy with bilateral salpingo-oophorectomy under general anaesthesia. On pre-operative anaesthesia assessment, she was found to have junctional rhythm at rate of 44 beats/minute with bigeminies and pre-mature ventricular contractions on ECG. On further evaluation, she was diagnosed as having congenital sinus node dysfunction on the basis of 24 hours Holter monitoring. She was asymptomatic, no prior comorbidity and belonged to functional class one. General anaesthesia was successfully managed by vigilance, invasive monitoring, standby transcutaneous and transvenous pacemakers; use of cardiostable and vagolytic anaesthetic agents like Etomidate, Atracurium and Pethidine during the procedure and for postoperative pain management. Transcutaneous external pacing pads were placed just after induction of anaesthesia, their functional capability was confirmed and was ready for use if needed. The transcutaneous and transvenous pacemakers were on backup and both were not required. Patient was successfully managed and was discharged home on third postoperative day with uneventful hospital course. The elective pacemaker implantation was therefore not required.

Key words: General anaesthesia. Sino-atrial node. Arrhythmias. Sick sinus syndrome. Pacemaker.

INTRODUCTION

Sick sinus syndrome (SSS) is a rare disorder characterized by a dysfunctional sinus node and can present with abnormal heart rhythms, including sinus bradycardia, exit block, arrest, bradycardia-tachycardia syndrome, chronic atrial fibrillation with failure of sinus rhythm to return after cardioversion and asystole.¹ It is the major cause necessitating pacemaker implantation and accounts for approximately half of all patients requiring a pacemaker.²

Although SSS has been addressed previously as an incidental finding before induction and during the maintenance phase of anaesthesia and these cases were managed by elective and emergency pacemaker implantation.

Reports on anaesthetic management of a diagnosed case of congenital sinus node dysfunction (SND) are scarce. Management of anaesthesia in these patients poses a considerable challenge for anaesthesiologist. We report successful conduct of anaesthesia for abdominal hysterectomy in a patient diagnosed as a congenital SND during the pre-operative anaesthesia evaluation.

Department of Anaesthesia, The Aga Khan University Hospital, Karachi,

Correspondence: Dr. Dileep Kumar, Flat No. 503, 5th Floor, Safety Pride Apartment., Cant Station, Civil Lines, Karachi.
E-mail: dkhiloi@yahoo.com

Received February 08, 2011; accepted October 12, 2011.

CASE REPORT

A 45 years old, 56 kg female with dysfunctional uterine bleeding (hypermenorrhea) was scheduled for total abdominal hysterectomy with bilateral salpingo-oophorectomy. A routine pre-operative assessment was carried out in the anaesthesia clinic. She had no known comorbidities but was incidentally found to have heart rate of 44 beats/minute. Electrocardiography showed a junctional rhythm with bigeminy and premature ventricular contractions (PVCs).

She was referred to the cardiologist who diagnosed congenital SND following 24 hours Holter monitoring. Holter monitoring had shown a lowest heart rate of 30 beats/minute, highest rate of 101 beats/minute, sinus pause of 2.7 seconds, frequent bigeminy, trigeminy and PVCs. Echocardiography was unremarkable.

She was labelled as American Society of Anaesthesiologist Status IV. The case was discussed with a cardiologist and it was planned to go ahead with general anaesthesia with standby pacemaker and the cardiologist. There was a possibility of haemodynamic instability and arrhythmias due to regional anaesthesia so spinal or epidural anaesthesia was avoided. Operating room was prepared with cardiac medications and arrangement for both transcutaneous or transvenous pacemaker. The patient was pre-medicated with oral Midazolam 7.5 mg. After initiating monitoring with ECG lead II, non-invasive blood pressure, peripheral oxygen saturation (SpO₂) and insertion of peripheral venous line, an arterial catheter was placed in right Radial artery for invasive blood pressure monitoring and the external pacing pads were placed for pacing, if

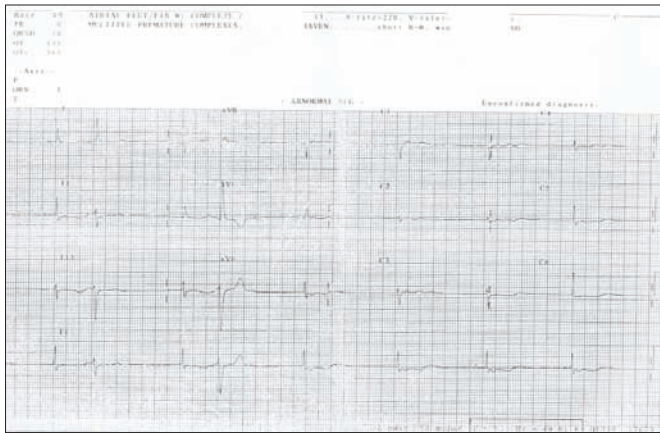


Figure 1: Normal ECG unconfirmed diagnosis.

needed. Her baseline heart rate in the pre-induction period in operating room was 56 beats/minute and she was in junctional rhythm and blood pressure was 130/80 mmHg.

General anaesthesia was induced with Etomidate 0.3 mg/kg, Pethidine 1 mg/kg and Atracurium 0.5 mg/kg. The patient developed transient bradycardia of 45 beats/minute on laryngoscope and endotracheal tube insertion which recovered spontaneously. After induction, transcutaneous pacing function was confirmed. Positive pressure ventilation was started with O₂/N₂O (40/60%) and Isoflurane adjusted to 1.2 MAC and Pethidine, Atracurium boluses were used as required for the maintenance of anaesthesia.

The procedure lasted 2 hours, there was one episode of severe bradycardia of 34 beats/minute with PVCs and frequent bigeminies following the peritoneal traction. This was responded to a single bolus of Glycopyrrolate 0.2 mg. Two more transient episodes of bradycardia occurred which were unrelated to surgical maneuvers and recovered spontaneously. Bradycardiac episodes were not associated with hypotension and after all these episodes; she was remained in sinus rhythm at heart rate of 50-60 beats/minute with stable blood pressure.

The emergence from anaesthesia was uneventful and both transcutaneous or transvenous pacemaking were not required. Atracurium was reversed with Neostigmine 2.5 mg and Glycopyrrolate 0.2 mg. Total blood loss was 300 mls.

She was transported to the recovery room with oxygen and cardiovascular monitoring. During the stay in recovery room, she remained stable haemodynamically except one episode of bradycardia 35 beats/minute, which recovered with a bolus of Atropine 0.5 mg.

Patient controlled analgesia for postoperative pain was started with Pethidine in recovery room at a setting of 10 mg/hour continuous infusion and 5 mg/bolus with 10 minutes of interval time. Total length of recovery stay was 90 minutes. Patient was transferred to special care

with cardiac monitor and remained there for 24 hours. She was discharged home on third postoperative day. She was pain free and remained haemodynamically stable during the postoperative period.

She was followed-up by the cardiologist. Permanent pacemaker implantation was not done because she remained asymptomatic.

DISCUSSION

The term SND was first used by Ferrer in 1968.³ SND is also known as SSS when accompanied with symptoms like dizziness or syncope. Its etiology is often idiopathic as a result of degenerative fibrosis of nodal tissue and patient with acquired heart disease (congenital heart disease, hypertensive heart disease, ischemic heart disease, cardiomyopathies and after surgical correction).¹ Certain disorders such as amyloidosis, connective tissue disease, Chagas disease, and haemochromatosis are examples of intrinsic causes.¹ The extrinsic etiologies are pharmacological agents such as Digitalis, calcium channel blockers, β -blockers, sympatholytic agents, and several anti-arrhythmic agents.¹

Sick sinus syndrome has multiple manifestations on electrocardiogram including sinus bradycardia, sinus arrest, sinoatrial block, and alternating patterns of bradycardia and tachycardia (bradycardia-tachycardia syndrome) and atrial fibrillation. Diagnosis of sick sinus syndrome may be difficult because of slow and erratic course of the syndrome. The condition often goes undetected in the early stages because only sinus bradycardia may be present at its origin. According to several reports, there are some examinations which can unveil SSS pre-operatively, such as routine pre-operative 24 hour Holter ECG, evaluating cardiovascular responses to beta stimulants or electrical atrial pacing.¹

A permanent pacemaker therapy is warranted if subjective symptoms are apparent, but according to the ACC/AHA (American College of Cardiology/American Heart Association) guidelines,⁴ asymptomatic sinus nodal dysfunction is not an indication for pacemaker implantation.

The patient was asymptomatic except bradycardia with frequent bigeminy and PVCs. Rhythm work-up was done and diagnosis of congenital SND on the basis of 24 hour Holter ECG was made. She was not on permanent pacemaker because the existence of subjective symptoms is the main factor in the need for pacemaker implantation.

A MEDLINE search from 1976 to present revealed no report of planned elective anaesthetic management of diagnosed SND with standby pacemaker. Although many reports of SSS becoming apparent during surgery have been published.⁵⁻⁷ Nakamura *et al.* had diagnosed

SSS before induction and proceeded after elective pacemaker implantation.⁸ Murakawa *et al.* reported SSS after induction of anaesthesia and managed with temporary pacemaker implantation.⁹

The present case was unique in view of planned anaesthetic management. This patient was managed through careful monitoring, avoidance of vagomimetic anaesthetic agents during the procedure and for postoperative pain management and placement of transcutaneous external pacing pads and its working confirmation. During the procedure, patient developed one episode of bradycardia which was triggered by peritoneal traction and was managed by Glycopyrrolate in spite of Atropine. Atropine can cause tachycardia-bradycardia syndrome but in the recovery room, patient received Atropine by recovery room resident due to one episode of bradycardia and recovered well without development of tachycardia-bradycardia syndrome.

Although keeping in mind the risk and benefit ratio of elective pacemaker implantation, our patient was asymptomatic, newly diagnosed and her heart rate responded to increased physical activity by Holter monitoring and the guideline of ACC/AHA has not mentioned/recommended the elective pacemaker implantation for surgical procedure and anaesthesia. However, the transcutaneous and transvenous pacemakers were on backup in this patient and both were not required. Our patient was successfully managed without use of elective transvenous pacemaker implantation and its complication of pneumothorax, wound hematoma, infection, arrhythmias and myocardial perforation.¹

Congenital SND is a rare disorder imposing challenging conditions for the anaesthesiologist. Thorough pathophysiological understanding of condition is mandatory. The patient diagnosed as congenital SND can be successfully managed by vigilance, invasive monitoring, standby transcutaneous and transvenous pacemakers and with use of cardiostable and vagolytic anaesthetic

agents like Etomidate, Atracurium and Pethidine during procedure and for postoperative pain management. Pacemaker implantation is indicated in case of tachycardia-bradycardia syndrome and if patient is clinically symptomatic. However, pacemaker implantation could be avoided in patient with asymptomatic SND and planned for elective surgical procedures requiring general anaesthesia.

REFERENCES

1. Adan V, Crown LA. Diagnosis and treatment of sick sinus syndrome. *Am Fam Physician* 2003; **67**:1725-32.
2. Bernstein AD, Parsonnet V. Survey of cardiac pacing and defibrillation in the United States in 1993. *Am J Cardiology* 1996; **78**:187-96.
3. Ferrer MI. The sick sinus syndrome in atrial disease. *JAMA* 1968; **206**:645-6.
4. Epstein AE, DiMarco JP, Ellenbogen KA, Mark Estes NA, Freedman RA, Gettes LS, *et al.* ACC/AHA/HRS 2008 Guidelines for device-based therapy of cardiac rhythm abnormalities: a report of the American College of Cardiology/American Heart Association Task Force on practice guidelines (writing committee to revise the ACC/AHA/NASPE 2002 guideline update for implantation of cardiac pacemakers and antiarrhythmia devices). *J Am Coll Cardiol* 2008; **51**:e1-e62.
5. Ishiyama T, Hanagata K, Yamaguchi T, Matsukawa T, Kashimoto S, Kumazawa T. Un-diagnosed sick sinus syndrome manifest during combined general and cervical epidural anaesthesia. *J Anesth* 2000; **14**:102-4.
6. Cohen LI. Asystole during spinal anaesthesia in a patient with sick sinus syndrome. *Anesthesiology* 1998; **68**:787-8.
7. Egan TD, Brock-Utne JG. Asystole after anaesthesia induction with a fentanyl, propofol, and succinylcholine sequence. *Anesth Analg* 1991; **73**:818-20.
8. Nakamura S, Nishiyama T, Hanaoka K. [General anaesthesia for a patient with asymptomatic sick sinus syndrome]. *Masui* 2005; **54**:912-3. Japanese.
9. Murakawa T, Ishihara H, Matsuki A. [Marked bradycardia during anaesthetic induction treated with temporary cardiac pacing in a patient with latent sick sinus syndrome]. *Masui* 2001; **50**:65-8. Japanese.

.....★.....