

Painless Aortic Dissection with Hypotension

Sir,

A 56 years woman with altered consciousness of 8 hours duration was admitted to our clinic. She was discovered in a sleepy state at work by her family and was transported to nearby hospital. On arrival, she remained drowsy, her vital signs were unstable (blood pressure = 90/68 mmHg; heart rate/radial pulse = 96/minute; and body temperature = 36.0°C). GCS score was not conducted. Neurological examination was not remarkable. Cardiovascular examination revealed diminished heart sounds. On repeated questioning, she denied any pain. Her background history included hypertension of 16 years duration. An electrocardiogram (ECG) showed sinus rhythm with a 2-mm ST segment depression and T-wave changes across the anterior and inferior leads. Serum levels of creatine kinase and troponin I were elevated, with increased D-dimer levels (> 1800 ug/L). Bedside transthoracic echocardiography showed widened aortic valve, left ventricular hypertrophy and a small pericardial effusion. She had no known history of diabetes mellitus, coronary artery disease, dyslipidemia, or connective tissue disease.

On the basis of her ECG findings and impaired myocardium, the medical team became concerned about non-ST-segment elevation myocardial infarction (NSTEMI) complicated by cardiogenic shock. A permissive antiplatelet therapy with tirofiban and clopidogrel sulfate was initiated. Catheterization through the right femoral artery was performed and revealed a normal coronary artery (Figure 1), leading to consider the diagnosis of dissection. Emergency computed tomographic angiography demonstrated an acute proximal aortic dissection (Stanford type A; DeBakey type I) arising from the aortic root involved the ascending aorta, and aortic arch. The left common carotid artery and left subclavian artery (Figure 2) were involved as well. The patient developed worsening congestive cardiac failure and eventually passed away 8 hours later.

This patient presenting with altered consciousness had no significant history of pain, which is unusual in standard dissection cases. Low blood pressure may be related to added pressure in the aortic arch baroreceptor, which was derived from hematoma generated by dissection. Hypotension and the involved left common carotid artery induced insufficient blood supply to the brain, leading to neurologic symptoms at the onset

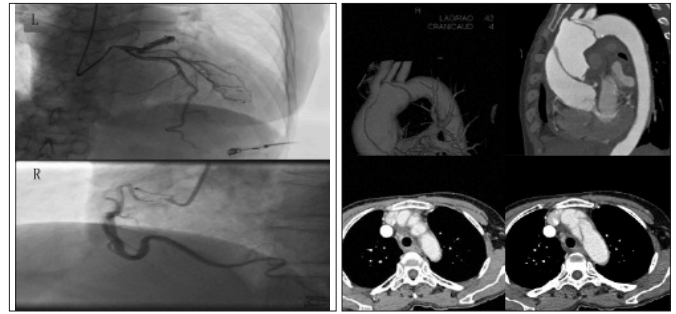


Figure 1: Coronary angiography revealed a normal right (R) and left (L) coronary artery.

Figure 2: Computed tomography showing aortic dissection of the ascending aorta.

of dissection. Slower dissection with less wall stretching may not result in pain.^{1,2} Others suggest that sparing of the adventitial layer, the site of aortic innervation, may obviate pain.¹

Attention should be paid to elevated D-dimer levels in the diagnosis of aortic dissection.³⁻⁵ The pathophysiology behind this finding can be explained by the activation of the extrinsic pathway of the coagulation cascade at the site of vessel wall injury by tissue factor. The link between elevated D-dimers and acute aortic dissection is an important clinical caveat for the practicing clinician as the therapeutic strategies in myocardial infarction and aortic dissection are vastly different.

REFERENCES

1. Wooley CF, Sparks EH, Boudoulas H, Aortic pain. *Prog Cardiovasc Dis* 1998; **40**:563-89.
2. Young J, Herd AM. Painless acute aortic dissection and rupture presenting as syncope. *J Emerg Med* 2002; **22**:171-4.
3. Perez A, Abbet P, Drescher MJ. D-dimers in the emergency department evaluation of aortic dissection. *Acad Emerg Med* 2004; **11**:397-400.
4. Ohlmann P, Faure A, Morel O, Petit H, Kabbaj H, Meyer N, Diagnostic and prognostic value of circulating D-dimers in patients with acute aortic dissection. *Crit Care Med* 2006; **34**: 1358-64.
5. Shao N. The role of D-dimers in the diagnosis of acute aortic dissection. *Mol Biol Rep* 2014; **41**:6397-403.

Zhenxuan Hao, Yang Liu and Hengliang Liu

Department of Cardiology, People's Hospital of Zhengzhou, Southern Medical University, Zhengzhou 450000, China.

Correspondence: Dr. Hengliang Liu, Department of Cardiology, People's Hospital of Zhengzhou, Southern Medical University, Zhengzhou 450000, China

E-mail: hzxrjm@163.com

Received: March 12, 2015; Accepted: June 19, 2015.

.....☆.....