

Ovarian Dermoid Causing Pilimiction

Kaniz Zehra Naqvi¹, Aziz Abdullah², Maria Jabeen¹, Farah Iqbal¹ and Muzzamil Edhi³

ABSTRACT

Ovarian dermoid cyst is one of the common problems seen in gynaecology, they make upto 10 - 25% of all ovarian neoplasms and are usually seen in younger age group. Mature cystic teratomas are usually an incidental finding during a clinical examinations, radiographic studies or during abdominal operations performed for other indications. Other presentations include abdominal symptoms from complications of the cyst such as torsion, rupture, infection and malignant transformation. Dermoid cyst in urinary bladder is a very rare condition. Here we are presenting a case report of a female who presented with lower abdominal pain and passage of hair in urine (pilimiction). Upon investigations it was found that patient had right sided dermoid which had penetrated the wall of bladder and expelled its contents in the bladder. This was a very rare presentation and no such case has been reported in Pakistani literature.

Key Words: Ovarian dermoid cyst. Pilimiction. Urinary bladder invasion.

INTRODUCTION

Dermoid cysts are benign tumours seen in about 10 - 20% of ovarian tumours and more commonly in females of younger age group.¹ They may remain asymptomatic and are discovered as incidental finding on ultrasound pelvis or can present as acute abdomen in case of torsion (16%), infection (1%) or rupture. It can rupture into the bladder, small bowel, rectum, sigmoid colon, vagina, anterior abdominal wall and peritoneal cavity.^{1,2}

Pathologically, teratomas are classified into three groups: mature (cystic/solid, benign), immature (malignant) and monodermal (*Struma ovarii*, carcinoid and neural tumours).³

We report a case of ovarian dermoid perforating in the urinary bladder and presenting with passage of hair while micturating.

CASE REPORT

A 25 years old nulliparous female married for 2 years belonging to low socioeconomic status presented in the outpatient clinic (OPD) with complaints of pain in lower abdomen for 4 months and repeated episodes of burning and frequent micturition.

After the first episode of urinary symptoms, she was treated for urinary tract infection with antibiotics and got relief. After couple of weeks, she again developed the same symptoms but this time she also noticed passage of hair in the urine in variable quantity, which were black in colour.

Department of Obstetrics and Gynaecology¹ / Urology² / Medicine³, Liaquat National Hospital and Medical College, Karachi.

*Correspondence: Dr. Kaniz Zehra Naqvi, B-60, South Street 26, Navy Housing Scheme, Zamzama, Clifton, Karachi.
E-mail: kanizzehranqvi@yahoo.com*

Received: April 29, 2014; Accepted: July 01, 2014.

On general physical examination, she was moderately built female. Her blood pressure was 120/70 mmHg and pulse was 85 beats/minute. On abdominal examination there was mild suprapubic tenderness more on the right side. On vaginal examination, the uterus was of normal size, anteverted and midposition. A hard mass of about 3 - 4 cm in size was felt in right fornix which was also tender but the left fornix was unremarkable. Her blood Urea, creatinine and electrolyte were within normal range; haemoglobin was 10.7 gm% and leucocyte count was 7,800/cumm. She was carrying with her two ultrasound reports done from two different places and both were showing an echogenic mass with central shadowing measuring 3 x 4 cm in the right adnexa suggestive of dermoid. Additionally an echogenic mass was seen in the right posterior wall of the bladder with central echogenic material about 3.2 x 3.4 cm, fine hair like structure also appearing from the periphery of the mass likely representing cystic teratoma (dermoid) (Figure 1A).

A CT scan of abdomen with contrast was performed which showed a well defined mixed soft tissue and fat density mass in right adnexa. It was seen infiltrating into the wall of urinary bladder and was protruding into its lumen. The intravesical component of this mass shows multiple foci of dense calcification. Findings was suggestive of right adnexal dermoid infiltrating into urinary bladder (Figure 1B).

She was admitted for cystoscopy and abdominal laparotomy and a consult was generated for the urologist. He also examined the patient and reviewed the ultrasound and CT scan and was of the same opinion that it was a dermoid cyst which has infiltrated in the bladder.

On cystoscopy, the walls of the bladder were seen covered with whitish plaques and a mass of about 3 x 2 cm with tuft of hair attached to it were seen protruding through the bladder wall on right side close to the dome.

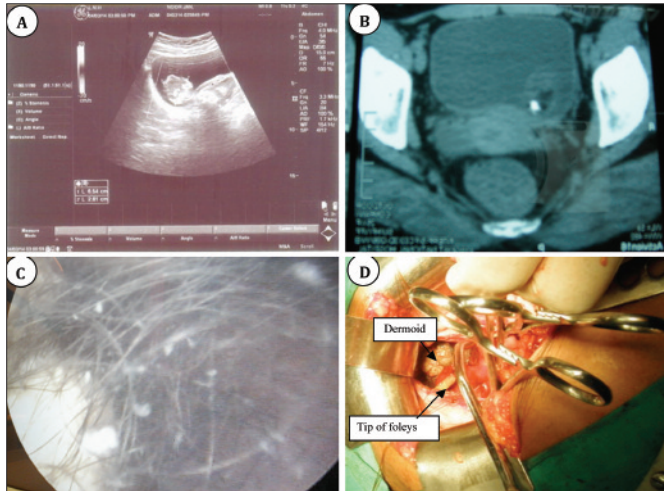


Figure 1 (A-D): (A) Ultrasound showing right adnexal mass extending in to the bladder. (B) CT Scan showing calcified mass in the bladder. (C) Cystoscopic picture of dermoid with hair protruding from it. (D) Intra-operative findings of open bladder with dermoid cyst.

The diagnosis of dermoid cyst of ovary with protrusion in bladder was confirmed (Figure 1C).

Bilateral ureteric stenting was performed and in the same sitting laparotomy was done. Uterus, left ovary were normal but a mass arising from right ovary was seen penetrating the broad ligament and entering the right wall of bladder. Urologist opened the bladder at the site where the cyst was entering the bladder and the whole of the dermoid cyst along with the right fallopian tube was removed (Figure 1D).

The bladder was closed with 3/0 vicryl and then abdomen closed. Foley's catheter was retained for two weeks. Postoperative recovery was uneventful and patient was discharged home on the third postoperative day. On the 10th postoperative day, the stitches were removed and on 14th day the Foley's catheter was also removed. Her histopathology report received after 3 weeks revealed a mature teratoma.

DISCUSSION

Cystic ovarian teratomas, especially the mature dermoid cysts constitute about 10 - 13% of all ovarian tumours and the most common benign germ cell tumour.¹ They are usually seen in the reproductive age group.⁴ Majority of these teratomas are symptom-free in their early stages and are incidental discovery on ultrasound. They produce symptoms only if they have grown very large and are influencing the function of the organs. They at times also present as acute abdomen due to torsion, infection, malignant necrosis.⁵ The chances of invasion into adjacent viscera are < 1%,⁶ and spontaneous rupture into adjacent viscera is least common.⁷ However, when such a communication occurs bladder is the commonest site.⁸

Patients with spontaneous rupture of dermoid cyst in bladder may present with complaints of passage of hair in urine (pilimiction), pyuria, repeated urinary tract infection, passage of other material from dermoid cyst

and at times repeated episodes of urinary retention due to blockage of urethral meatus by hair.⁹ In this case, the patient presented with passage of hair in urine for the last 2 months. This is a pathognomonic sign.⁹

Why this communication between dermoid cyst and adjacent viscera develops is still a conjecture. One group of scientist reported a case where they suspected a small leak causing dense adhesions resulting in formation of fistula between the cyst and the bowel,¹⁰ torsion, trauma, infection, chronic pressure in labour and malignant transformation can cause leakage and fistula formation. It seems that chronic leakage is the common factor in non-malignant fistula formation with adjacent viscera.⁸ In this case, there was no torsion or any infection which could be held responsible for fistula formation.

In all the literature which we looked into, we found that whenever there was bladder involvement, diagnosis was made on cystoscopy or laparotomy but in this case the sonologist and the radiologist gave us a confirmed diagnosis which proved to be true on cystoscopy. CT scan is diagnostic as was in this case as it explicitly demonstrated the calcification in the portion of the mass in bladder.⁶

Surgical resection of the mass with bladder repair is the definitive procedure. Proper diagnosis and planning of the treatment can help in adopting a rational approach for the benefit of the patient.

REFERENCES

1. Koonings PP, Campbell K, Mishell DR Jr, Grimes DA. Relative frequency of primary ovarian neoplasm: a 10 years review. *Obstet Gynecol* 1989; **74**:921-6.
2. Sardesai S, Raghoji V, Dabade R, Sheikh H. Benign cystic teratoma of ovary perforating into urinary bladder: a rare case. *J Obstet Gynaecol India* 2012; **62**:S54-S55.
3. Choi DJ, Wallace EC, Fraire AE, Baiyee D. Best cases from AFIP: intra renal teratoma. *Radiographics* 2005; **25**:481-5.
4. Stella F, Davoli F. Giant mediastinal teratoma with increased exocrine pancreatic activity presenting in a young woman: a case report. *J Med Case Reports* 2004; **238**:2.
5. Hibbard L. Adnexal torsion. *Am J Obstet Gynecol* 1985; **152**: 456-61.
6. Park SB, Kim JB, Kim KR, Cho KS. Imaging findings of complications and unusual manifestation of ovarian teratomas. *Radiographics* 2008; **28**:969-83.
7. Godra R, Karwasra RK, Garg P, Sharma N. Pilimiction: a diagnostic symptom of ovarian dermoid cyst. *Internet J Gynecol Obstet* 2006; **6**:658-9.
8. Okada S, Ohaki Y, Inoue K, Nakajo H, Kawamata H, Kumazaki T. A case of dermoid cyst of the ovary with malignant transformation complicated with small intestinal fistula formation. *Radiat Med* 2005; **23**:443-6.
9. Poopola AA, Adewole A, Ibikunle DE, Agboola JA, Buhari MO. Recurrent urinary retention in a woman from perforation of ovarian teratoma into urinary bladder: a case report. *Androl Gynecol. Corr Res* 2013; **1**:4.
10. Shiels WE, Duono F, Hernandez E. Ovarian dermoid cyst complicated by an entero-ovarian fistula. *Radiology* 1986; **160**:443-4.

