

# Modified Single Stapler Technique in Anterior Resection for Rectal Cancer

Soner Akbaba<sup>1</sup>, Pamir Eren Ersoy<sup>1</sup>, Riza Haldun Gundogdu<sup>1</sup>, Murat Ulas<sup>2</sup> and Ebru Menekse<sup>3</sup>

## ABSTRACT

Technical difficulties during colorectal surgery increase the complication rates. We introduce a modified single stapler technique for patients in whom technical problems are encountered while performing double stapler technique. Before pelvic dissection, descending colon is divided at minimum 10 cm proximal to the tumoral segment. Tumor specific mesorectal excision is performed and two purse string sutures are placed at the distal margin with an interval of 1 - 2 cm. After introducing a circular stapler via the anus, the distal purse string suture is tied around the central shaft of the stapler and the proximal purse string suture around the colonic lumen. After the resection is completed between the two sutures, the anvil shaft is connected to the central shaft and the stapler is closed and fired. None of the patients had an anastomotic leak. This technique may be a safe alternative particularly in patients with narrow pelvis and distal tumors.

**Key Words:** Anterior resection. Modified technique. Rectal cancer. Stapler anastomosis.

## INTRODUCTION

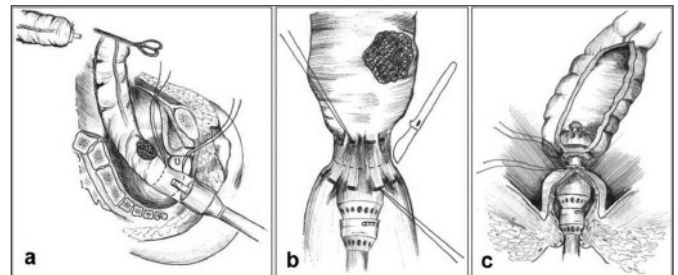
Good surgical technique is integral to optimizing oncologic outcome and minimizing morbidity in rectal cancer surgery.<sup>1</sup> The introduction of surgical staplers has altered the technical ease of constructing anastomoses, and this has contributed to their widespread clinical use.<sup>2</sup> However, rectal exposure and anastomosis are still difficult processes, particularly in patients with narrow pelvis and/or distal rectal tumors. The purse string suture to the rectal stump after resection may be sometimes frustrating. Recently, the Double Stapler Technique (DST) has been commonly used as it does not require distal purse string suture.<sup>3,4</sup> However, the insertion of linear stapler is difficult to manipulate in the narrow pelvis and protrusions in the lateral corners called the “dog-ears” of the anastomosis line have greater risk of leakage.<sup>5,6</sup>

In this report, the authors are describing the early results of 11 patients who underwent modified single stapler technique because of technical difficulties during DST.

## TECHNIQUE

All cases were operated electively except for 2 patients with obstruction. None of the patients received neoadjuvant

radiotherapy or chemotherapy. Pre-operative bowel preparation was not performed. However, antibiotic prophylaxis (metranidazole and cefazoline) is routinely used. The patients were put in Lloyd-Davies position. After the midline incision, splenic flexura and descending colon were mobilized. Inferior mesenteric artery was ligated distally to the left colic artery and inferior mesenteric vein was ligated at the inferior border of the pancreas. Two intestinal clamps were placed to the proximal colon with a minimum 10 cm distance from the tumor and the colon was transected. EEA stapler anvil was placed above the ligated purse string suture at the distal end of the descending colon. Decompression was performed before introducing the anvil in patients with obstruction. Tumor specific mesorectal excision was performed in all cases. Distal resection margin was performed at least 2 cm away from the tumor. Below this margin, two purse string sutures with an interval of 1 - 2 cm were applied to the rectal cuff using 2/0 polypropylene (Figure 1a). After introducing a circular stapler via the anus, we tied the distal purse string suture around the central shaft of the stapler. The proximal purse string suture was tied tightly in order to



**Figure 1:** (a) Two purse string sutures were placed at the distal margin with an interval of 1-2 cm; (b) After introducing a circular stapler, the distal suture is tied around the central shaft of the stapler and the proximal suture around the colonic lumen; (c) After the resection was completed between the two sutures, the anvil shaft was connected to the central shaft.

<sup>1</sup> Department of General Surgery, Ataturk Training and Research Hospital, Ankara, Turkey.

<sup>2</sup> Department of Gastroenterology Surgery, Yuksek Ihtisas Training and Research Hospital, Ankara, Turkey.

<sup>3</sup> Department of General Surgery, Ankara Numune Training and Research Hospital, Ankara, Turkey.

Correspondence: Dr. Soner Akbaba, Cetin Emec Bulvari, Metis-Cevreyolu Sitesi, C-Blok, No. 12, Ankara, Turkey.

E-mail: sonerakbaba@yahoo.com

Received: May 24, 2014; Accepted: October 30, 2014.

**Table I:** Patients' age, gender, type of operation, stage and complications.

Case No.	Gender	Age (year)	Indication	Comorbidities	Location	Stage (TNM)	Operation method	Complication discharge day
1	Female	71	Elective	CAD, HT	Rectum-mid	Stage-1 (T2No Mo)	LAR	Fat necrosis 5-day
2*	Female	68	Urgent-ileus	HT	Recto-sigmoid	Stage-2 (T3NoMo)	AR	Subileus 14-day
3	Male	49	Elective	None	Rectum-upper	Stage-3 (T3N2Mo)	AR	None 6-day
4	Male	45	Elective	None	Rectum-upper	Stage-2 (T3NoMo)	AR	None 7-day
5	Male	65	Elective	None	Rectum-low	Stage-3 (T3N1Mo)	LAR	None 7-day
6	Male	70	Elective	Hypothyroidism	Rectum-low	Stage-3 (T3N1Mo)	LAR	None 7-day
7*	Female	65	Urgent-ileus	CAD	Rectum-mid	Stage-3 (T3N1Mo)	LAR	None 7-day
8	Female	78	Elective	CAD	Rectum-low	Stage-1 (T2No Mo)	LAR	CAD 18-day
9	Female	55	Elective	HT	Rectum-low	Stage-1 (T2No Mo)	LAR	Fat necrosis 26-day
10	Male	69	Elective	DM, Venous insufficiency	Rectum-low	Stage-1 (T2No Mo)	LAR	Fat necrosis 14-day
11	Male	71	Elective	Hypothyroidism	Rectum-mid	Stage-3 (T4N2M0)	LAR	None 7-day

AR = Anterior Resection; CAD = Coronary Artery Disease; DM = Diabetes Mellitus; HT = Hypertension; LAR = Low Anterior Resection.

\* The descending colon was decompressed during the operation.

prevent contamination. Resection was completed by transecting the rectum over the distal purse string suture around the central shaft (Figure 1b). The anvil reconnected with the stapler, and then the instrument was closed and fired (Figure 1c). After removal of the stapler, the doughnuts were inspected for completeness. All anastomoses were checked with air leakage test. No diverting ostomy was performed and there was no need for blood transfusion in any of the patients. The demographics of the patients are given in Table I.

## DISCUSSION

The Anastomotic Leak (AL) is the primary cause of postoperative morbidity and mortality in colorectal surgery.<sup>1,6-11</sup> Despite evolutions in stapling techniques and operation modalities, incidence of anastomotic leakage after colorectal surgery has not decreased over the last decade.<sup>9,10</sup> Leakage can be the result of single or combined technical, local, and systemic factors.<sup>11,12</sup> But many studies showed that the surgical technique is a key factor in the development of anastomotic leak.<sup>1,7,11,12</sup> Leakage rates have also been used as an indicator of surgical quality.<sup>11</sup>

Creating a safe and healthy bowel anastomosis is a critical step of successful intestinal surgery. Colorectal anastomoses can be performed using hand-sewn technique or with surgical stapler. Stapler techniques are more often preferred because of their technical advantages.<sup>6,8,13</sup> Many different stapler techniques for colorectal anastomosis have been described in the

literature. Nevertheless, the dissection and anastomosis are difficult processes in the deep and narrow pelvis.<sup>12</sup>

The primary technical reason for leakage in single stapler anastomosis is the inefficacy of distal purse string suture.<sup>3,6</sup> It is technically hard to perform the purse string suture to the rectal stump after resection.<sup>4,12</sup> Besides, the contamination risk also increases when the lumen is exposed.<sup>6,13</sup> The submucosal layer is the most important layer of luminal anastomosis and the anastomosis will probably lead to a catastrophe unless this layer is properly included. Mucosal tears in the anastomosis line caused by the anvil or traction will also cause leakage.<sup>3</sup>

The double stapler technique provides shorter operation time, less bleeding and contamination and also performing lower anastomosis.<sup>5,12</sup> However, in obese patients with large tumors and in patients with narrow pelvis, the insertion of the linear stapler is usually difficult. Besides, it causes the so-called "dog-ear" deformity in lateral corners, which increases the risk of leakage by potentially ischemic areas on the anastomosis line.<sup>3,5,6,11,12</sup> On the other hand, the complication and local recurrence rates are similar to the single stapler technique.<sup>5</sup>

The authors preferred to use the double stapler technique in the colorectal anastomosis and we occasionally experienced technical problems. The aim of this study was to describe an alternative technique for those specific cases. By means of this modified technique, pelvic dissection and distal purse string

sutures after division of the proximal resection margin of tumoral segment are performed more easily. Thanks to the luminal closure the risk of contamination is reduced. "Dog-ear" deformity does not occur. The stapler can be more easily applied through the anus before the distal resection, and damage to the mucosa, rectal wall and sphincters is, therefore, reduced. The cost of the procedure is less since only one stapler is used.

Except for one patient with obstruction, all the patients received oral intake in the early postoperative period. Anastomotic leak was not observed in any of the patients. Three patients had fat necrosis in the abdominal incision. One patient had sub-ileus and one patient was monitored in the intensive care unit due to coronary ischemia. All patients were discharged within 1 to 4 weeks.

### CONCLUSION

This technique offers certain advantages that allow the anastomosis to be performed in a better and safer manner in patients with narrow pelvis and distal rectal tumors. Although this modified technique seems to be more feasible, it should be performed on more patients and long-term results should be monitored.

### REFERENCES

1. Abbas MA, Chang GJ, Read TE, Rothenberger DA, Garcia-Aguilar J, Peters W. Optimizing rectal cancer management: analysis of current evidence. *Dis Colon Rectum* 2014; **57**: 252-9.
2. Jones DW, Garrett KA. Anastomotic technique-Does it make a difference? *Sem Colon Rectal Surg* 2014; **25**:79-84.
3. Roumen RM, Rahusen FT, Wijnen MH, Croiset van Uchalen FA. "Dog-ear" formation after double-stapled low anterior resection as a risk factor for anastomotic disruption. *Dis Colon Rectum* 2000; **43**:522-5.
4. Radovanovic Z, Petrovic T, Radovanovic D, Breberina M, Golubovic A, Lukic D. Single versus double stapling anastomotic technique in rectal cancer surgery. *Surg Today* 2014; **44**:1026-31.
5. Sato H, Maeda K, Hanai T, Matsumoto M, Aoyama H, Matsuoka H. Modified double-stapling technique in low anterior resection for lower rectal carcinoma. *Surg Today* 2006; **36**:30-6.
6. Brisinda G, Vanella S, Cadeddu F, Civello IM, Brandara F, Nigro C, *et al.* End-to-end versus end-to-side stapled anastomoses after anterior resection for rectal cancer. *J Surg Oncol* 2009; **99**:75-9.
7. B-Slieker JC, Daams F, Mulder IM, Jeekel J, Lange JF. Systematic review of technique of colorectal anastomosis. *JAMA Surg* 2013; **148**:190-201.
8. Daams F, Luyer M, Lange JF. Colorectal anastomotic leakage: aspects of prevention, detection and treatment. *World J Gastroenterol* 2013; **19**:2293-7.
9. Daams F, Wu Z, Lahaye MJ, Jeekel J, Lange JF. Prediction and diagnosis of colorectal anastomotic leakage: a systemic review of literature. *World J Gastrointest Surg* 2014; **6**:14-26.
10. Sultan R, Chawla T, Zaidi M. Factors affecting anastomotic leak after colorectal anastomosis in patients without protective stoma in tertiary care hospital. *J Pak Med Assoc* 2014; **64**:166-70.
11. Baek SJ, Kim J, Kwak J, Kim SH. Can trans-anal reinforcing sutures after double stapling in lower anterior resection reduce the need for a temporary diverting ostomy? *World J Gastroenterol* 2013; **19**:5309-13.
12. Marecik SJ, Chaudhry V, Pearl R, Park JJ, Prasad LM. Single-stapled double-pursestring anastomosis after anterior resection of the rectum. *Am J Surg* 2007; **193**:395-9.
13. Taflampas P, Christodoulakis M, Tsiftsis DD. Anastomotic leakage after low anterior resection for rectal cancer: facts, obscurity and fiction. *Surg Today* 2009; **39**:183-8.

