

Multiple Pulmonary Artery Aneurysms: A Rare Cause of Massive Hemoptysis as Presentation of Behcet's Disease

Salem Mohammad Al Amri, Ahmad Hassan Banjar and Ahsan Iqbal Cheema

ABSTRACT

We report a case of an acute episode of massive hemoptysis in a diagnosed patient of Behcet's disease, managed conservatively, using angio-guided vascular plug and coils for occluding the multiple bilateral pulmonary artery aneurysms with thoracic surgery backup. The episode of massive hemoptysis was caused by ruptured Pulmonary Artery Aneurysms (PAA).

Key Words: *Massive hemoptysis. Pulmonary artery embolization. Behcet's disease. Pulmonary Artery Aneurysms (PAA). Genital ulcer.*

INTRODUCTION

Behcet's disease is a rare immune-mediated small-vessel systemic vasculitis that often presents with mucous membrane ulceration and ocular problems.

Pulmonary artery aneurysm in Behcet's disease seriously compromises the management since its fatal rupture is still the major cause of death in this disease. Pulmonary artery aneurysm requires urgent management and several treatments have been proposed, including steroids, immunosuppressive agents, embolization and surgery.^{1,2}

Arterial embolization is a useful therapy to control both acute and chronic hemoptysis and remains the primary and most effective method in controlling massive hemoptysis.³ It is done using gel-foam particle, polyvinyl alcohol and minicoils.⁴ The minicoils allow super-selective embolization but for reasons of cost, should be reserved to such vascular regions where the risk of misplacing must be kept at a minimum.⁵

Arterial embolization may help to avoid surgery in patients who are not good surgical candidates. Should hemoptysis recur in these patients, repeat embolization can be performed safely.⁵ Bilateral pulmonary artery branch embolization is not commonly performed, however, it may be required in cases with recurrent bleeding which is not uncommon, especially if there is progression of the underlying disease process.⁶

This report describes multiple pulmonary artery aneurysms.

CASE REPORT

A 28 years male was referred with complaints of massive hemoptysis off and on for the last 4 years. The workup for pulmonary tuberculosis was negative. His past medical history was unremarkable. Fiberoptic bronchoscopy was done which localized the blood coming from the right lower lobe. CT angiography confirmed the presence of multiple pulmonary artery aneurysms on the right side (Figure 1). Echocardiography revealed raised pulmonary artery pressure (65 mmHg). Hemoptysis persisted and patient was offered surgical management but patient requested for alternative management. The interventional radiologist was then consulted.

All the necessary preparations were done and thoracic surgery team remained on standby. Angiography-guided embolization of the right lower and middle lobe branch (interlobar) artery was done with vascular plug 2 (20 mm) along with fibered coil (3 mm x 40 mm) size (Figure 2); embolization was also done for the other small branches aneurysms of the interlobar arteries. Completion angiogram showed complete occlusion of interlobar artery with non-filling of the aneurysms. The recovery was uneventful and symptoms subsided.

The patient was discharged home on the third post-procedure day. After 2 months, he again presented with mild hemoptysis. Repeat angiogram revealed aneurysm at the same previous location in pulmonary artery for which he again underwent embolization by Angio coil. The patient tolerated the procedure well.

After 6 months, he presented to the emergency room with massive hemoptysis. He was hypotensive and tachycardiac but maintaining oxygen saturation at room air. Coagulation profile and other laboratory parameters were all within normal limits.

Prompt resuscitation was done; he was electively intubated and mechanically ventilated for lung separation.

Department of Thoracic Surgery, Al-Noor Specialist Hospital, Holy Makkah, Saudi Arabia.

Correspondence: Dr. Salem Al Amari, P. O. Box 6251, Makkah, 21955, Saudi Arabia.

E-mail: smalsharif@yahoo.com

Received: March 28, 2013; Accepted: March 05, 2014.

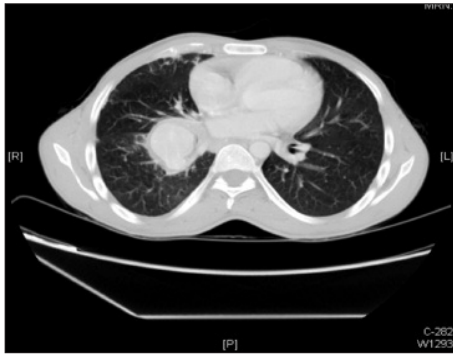


Figure 1: CT Chest showing large aneurysm in inferior branch of the right pulmonary artery. It has relatively thick irregular wall and measures about 4.0 x 3.5 cm.

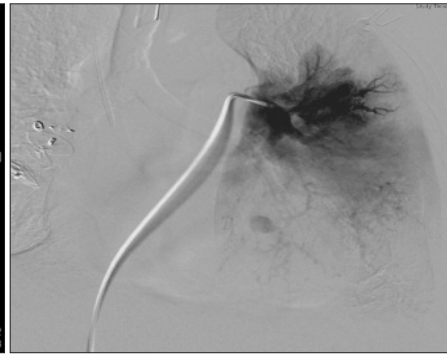


Figure 2: Pulmonary angiogram: right vascular plug and coiling of the left lower branch.

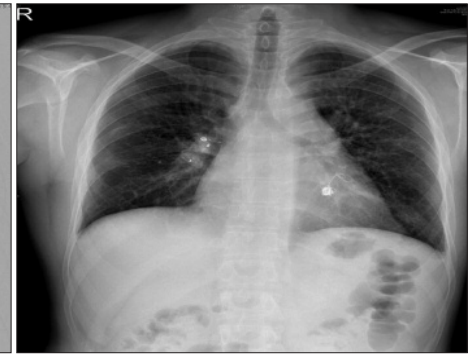

Figure 3: Chest Roentgenogram showing post-bilateral vascular plug and coiling, (vascular plug 2 (20 mm) right inferior branch of pulmonary artery with fibered coil in right upper and left lower lobe branches).

Fiberoptic bronchoscopy showed blood within left main bronchus. Echocardiography showed Pulmonary Arterial Pressure (PAP) of 70 mmHg.

CT angiographs of chest revealed old coil investing right middle lobar branch of pulmonary artery with minimal dilatation. Left lower lobe pulmonary artery aneurysm was a new finding. An occlusive coil embolization was done for the aneurysm of the left lower lobe branch of the left pulmonary artery (Figure 3). Repeat fiberoptic bronchoscopy showed no active bleeding.

The patient was successfully extubated with the total ICU stay of 6 days. Steroids were prescribed for management of Behcet's disease as the diagnosis was suggested due to multiple bilateral pulmonary artery aneurysms and genital ulcer by rheumatology.

He was discharged from the hospital one week after the patient remained asymptomatic and is being followed-up as outpatient for more than a year by now.

DISCUSSION

Bilateral Pulmonary Artery Aneurysms (PAA) are uncommon and the exact incidence is not known. It is difficult to diagnose, since the clinical manifestations is not specific and may be an incidental finding on a chest radiograph. The treatment, apart from the initial management of the presenting complaints, is controversial, as the natural history of the disease is not completely understood.⁷

Massive hemoptysis is defined as expectoration of more than 600 ml of blood within a 24-hour period or 150 ml in one hour. This is a life threatening medical emergency with a mortality of 50 - 80%, if untreated. Only 5 - 10% origin of this hemoptysis is from pulmonary arteries. So a prompt and early diagnosis and management is essential. Pulmonary artery aneurysm is a relatively uncommon cause for massive hemoptysis which is successfully treated by endovascular plug and coiling as in this case.⁸

Behcet's disease is a multisystem and chronic inflammatory disorder of unknown cause that is

characterized by recurrent oral and genital ulcerations, ocular manifestations, and additional clinical manifestations in multiple organ systems.

There is a high recurrence rate of complications related to pulmonary artery aneurysms due to inadequacy of medical therapy and the disadvantages of surgical treatment, therefore, these patients are potential candidates for endovascular management.^{9,10}

Behcet's disease involving the chest can manifest as a wide spectrum of abnormalities. Although conventional chest radiography is commonly used for initial assessment, computed tomography can demonstrate the entire spectrum of thoracic manifestations of Behcet's disease, including abnormalities of the vessel lumen and wall, perivascular tissues, lung parenchyma, pleura, and mediastinal structures. Aneurysms of the pulmonary arteries, with or without thrombosis, are a typical manifestation of Behcet's disease. It was unique for this case to have multiple bilateral pulmonary artery aneurysms managed successfully with repeated angiography guided coils and plugs.

The authors recommend that there should be a multidisciplinary approach to achieve optimal patient management in such cases. In tertiary care centers, thoracic surgical backup and trained interventional radiologists can provide maximum benefit to the patients.

REFERENCES

1. Cantu JA, Safdar Z. Hemoptysis requiring bronchial artery embolization in pulmonary arterial hypertension: *South Med J* 2010; **103**:887-91.
2. Swanson KL, Johnson CM, Prakash UB, McKusick MA, Andrews JC, Stanson AW. Bronchial artery embolization: experience with 54 patients: *Chest* 2002; **121**:789-95.
3. Chun JY, Morgan R, Belli AM. Radiological management of hemoptysis: a comprehensive review of diagnostic imaging and bronchial arterial embolization. *Cardiovasc Intervent Radiol* 2010; **33**:240-50.

4. Hahn S, Kim YJ, Kwon W, Cha SW, Lee WY. Comparison of the effectiveness of embolic agents for bronchial artery embolization: gel foam versus polyvinyl alcohol. *Korean J Radiol* 2010; **11**:542-6.
5. Kalva SP. Bronchial artery embolization. *Tech Vasc Interv Radiol* 2009; **12**:130-8.
6. Rilinger A, Görlich J, Vogel J, Merkle E, Krämer S, Sokiranski R, et al. Mechanically detachable minicoils attached to a wire for superselective embolization. *Rofo* 1997; **167**:160-4.
7. Peter Corr. Pulmonary artery aneurysm as a cause of massive hemoptysis: diagnosis and management. *Case Rep Radiol* 2011; **2011**:141563.
8. Cantasdemir M, Kantarci F, Mihmanli I. Emergency endovascular management of pulmonary artery aneurysms in Behcet's disease: report of two cases and review of the literature. *Cardio-vasc Intervent Radiol* 2002; **25**: 533-7.
9. Hiller N, Lieberman S, Chajek-Shaul T, Bar-Ziv J, Shaham D. Thoracic manifestations of Behcet's disease at CT. *Radiographics* 2004; **24**:801-8.
10. Lacombe P, Qanadli SD, Jondeau G, Barré O, Mesurole B, Mouas H, et al. Treatment of hemoptysis in Behcet's syndrome with pulmonary and bronchial embolization. *J Vasc Interv Radiol* 1997; **8**:1043-7.

