CASE REPORT

# Regional Anaesthesia in Thyroid Surgery

Navaid Akhtar[1] and S. Akbar Abbas[2]

## Abstract

Thyroidectomy is usually performed under general anaesthesia with endotracheal intubation. Bilateral cervical plexus block has been occasionally used as sole anaesthesia technique for this operation in certain parts of world. Indications for regional anaesthesia elsewhere in the world are patient's preference and associated marked cardio-respiratory disease. This is the first report of thyroidectomy done solely under bilateral cervical plexus block in Pakistan. The patient had thyroid cancer and was medically compromised due to cardiac failure with ejection fraction of 25%. Bilateral cervical plexus block was performed to avoid the high risk with general anaesthesia. Total thyroidectomy was done while patient remained pain-free during the procedure and top-up local anaesthetic infiltration was not required. Patient remained stable without any morbidity. Positive experience from this case indicates that regional anaesthesia with monitored anaesthesia care is safer than general anaesthesia in high risk patients and could be offered to selective thyroidectomy candidates.

**Key Words:** *Regional anaesthesia. Thyroid surgery. Cervical plexus block. Cardiac disease.*

## INTRODUCTION

General anaesthesia (GA) is commonly used for thyroid surgery. Bilateral cervical plexus block (BCPB) is adequate to produce anaesthesia for procedures on anterolateral aspect of neck. The disadvantages of GA are possible prolonged post-anaesthesia recovery as well as the adverse effects of endotracheal intubation and the anaesthetic agents. GA also has the potential to result in subsequent nausea and vomiting afterward. The advantages of local anaesthesia (LA) with monitored anaesthesia care (MAC) are faster post-anaesthesia recovery, no throat or vocal cord irritation and potential avoidance of the adverse effects of GA.

An effective cervical plexus block produces anaesthesia over the neck, occipital, shoulder and upper pectoral region. The cervical plexus is formed from C1 through C4 nerve roots. Here are five main components of the cervical plexus.[1] The superficial cutaneous branches are the lesser occipital, greater auricular, transverse cervical, and supraclavicular. Deep branches are phrenic nerve and direct muscular branches. Infiltration of these roots can produce adequate anaesthesia on the anterolateral aspect of the neck.

The report describes the use of this technique in an elderly male operated for thyroid carcinoma.

## CASE REPORT

A 72-year-old male, weighing 68 kg with American Society of Anaesthesiologist (ASA) status IV was referred to the otolaryngology department from a tertiary care cancer centre for the treatment of metastatic follicular cell carcinoma of thyroid gland (Figure 1). Patient had underwent laminectomy 3 months ago for paralysis secondary to vertebral metastasis. He had severe ischaemic heart disease with the history of myocardial infarction. He underwent cardiac bypass surgery 5 months ago for the symptoms of severe coronary ischaemia secondary to occlusion of left anterior descending coronary artery. His cardiac function was severely compromised with an ejection fraction of 25%. Cardiac echography showed severe global hypokinesia and pulmonary hypertension. Patient had been evaluated at two tertiary care hospitals and was declared high risk for GA.

After discussion with the surgeon, operation was planned under BCPB to eliminate the risks with GA. An 18-gauge peripheral IV cannula was sited. Noninvasive blood pressure, five-lead electrocardiography (leads II and V5) and pulse oximetry were employed before placement of the block and were continued until discharge from the post-anaesthesia care unit (PACU).

Placement of BCPB was performed by senior consultant anaesthesiologist who was experienced in the regional anaesthesia and pain management. Superficial approach to BCPB was used on this patient (Figure 2 and 3).[2-4] The final volume of local anaesthetic, therefore, depended somewhat on the patient's body weight and the dose used. Patient was sedated during the surgery by midazolam 2 mg (i/v) and propofol 0-5 ml/hour infusion. Patient underwent total thyroidectomy with excision of tumour in 2½ hours with minimal blood loss.

Patient remained comfortable during the whole operation. No top-up infiltrations of local anaesthetics were required. His visual analogue score (VAS) was 0/10 intraoperatively and 1/10 in PACU. Patient remained haemodynamically stable throughout with a mean

*Department of Anaesthesiology and Pain Management[1] / ENT[2], Patel Hospital, Karachi.*

*Correspondence: Dr. Navaid Akhtar, Department of Anaesthesiology and Pain Management, Patel Hospital, Block-4, Gulshan-e-Iqbal, Karachi-75300.*
*E-mail: navakhtar@yahoo.com*

*Received: October 10, 2012; Accepted: July 05, 2013.*

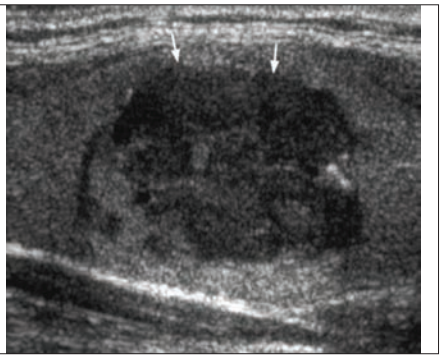

**Figure 1:** Longitudinal grey scale sonogram shows an ill-defined heterogeneous thyroid nodule (arrows). The hypoechoic nature of the follicular lesion raises the suspicion of follicular carcinoma.

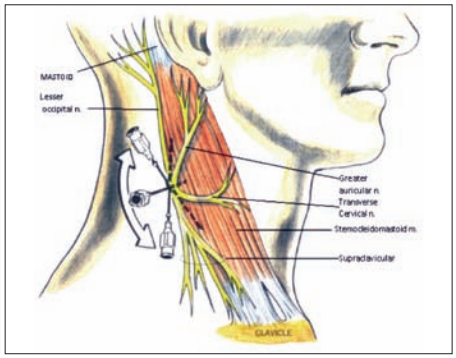


**Figure 2:** Needle directions for superficial cervical plexus block also showing branches of plexus (lesser occipital, greater auricular, transverse cervical and supraclavicular nerves).


**Figure 3:** Surface markings from C2 to C6 for deep cervical plexus block and injection of local anaesthetic at C3 level.

systolic blood pressure of 115 mmHg and heart rate of 78/minute. Modified Wilson sedation score was 1 – 2 during operation. The total volume of 0.375% bupivacaine used for the block was 30 ml. The main outcome measure for the efficacy of block was the amount of supplemental lignocaine infiltration used intra-operatively which was none in this case. Patient was pain-free during and after the operation and went home very satisfied with the management and the type of anaesthetic given to him.

## DISCUSSION

In the early days thyroid surgery was performed under LA techniques. Surgeons started performing thyroidectomies exclusively under GA when volatile anaesthetics became safer. However, a recent description of thyroidectomy under regional anaesthesia claims similar results to thyroidectomy under GA.[5] Regional anaesthesia (RA) can be used as the sole technique for surgical procedures in the neck such as thyroid surgery and carotid endarterectomy.[6]

RA avoids the risks associated with GA (e.g. problems related to endotracheal intubation and untoward effects of anaesthetic agents). RA also allows intraoperative voice monitoring and provides excellent postoperative analgesia. RA technique may be suited for high risk patients whose cardiac status are compromised or those with obstructive symptoms secondary to large goiters to avoid the risks of difficult intubation under GA.[7]

However, RA techniques do have some disadvantages, including risk of having local anaesthetic toxicity, spinal or epidural injections, neuropraxis, hematoma formation etc.[8] Surgical operation around neck in an awake patient can cause anxiety, amounting to fear and feeling of panic. To alleviate patient's anxiety, pre-operative psychotherapy and reassurance is paramount. Careful patient selection is important to exclude those who are temperamentally unsuitable. The role of adequate sedation to relieve fear and anxiety and minimize the discomfort caused by prolonged immobility on operating table cannot be overemphasized.

In thyroidectomy, deep plane of anaesthesia is not necessary and significant muscle relaxation is not required. When the need for laryngoscopy and endotracheal intubation is removed, the two greatest stimuli in thyroidectomy are skin incision and manipulation of the gland around the larynx and trachea.[9] Thyroidectomy can be performed under either GA or RA with MAC, expecting similar operative and clinical results. This case indicates that regional anaesthesia is an appropriate alternative to GA in selected patients undergoing thyroid and parathyroid surgery and did not compromise respiratory function. In addition, LA with MAC can reduce the postoperative time spent in an outpatient surgery setting with potential health care cost savings.[10]

The SCPB takes care of the pain usually caused by skin incision and the tissue dissection. SCPB is easier and safer than the combined superficial and deep cervical plexus block, DiNorcia *et al*. also concluded in their study.[3]

The overall quality of operating condition in this patient as assessed by the surgeon was satisfactory. The positive experience from this case of total thyroidectomy done under BCPB goes along with the similar experience of previous studies by Suh *et al*.[6] and Lee *et al*.[7] It indicates that RA with MAC could be offered to selective thyroidectomy candidates, such as those treated in this report. Considering the safe outcome of this case and other studies of RA with MAC for thyroidectomies, it is suggested that RA is safer than GA in selective patient population and can provide equal clinical outcomes and patient satisfaction. Studies with larger number of patients are required to confirm the apparent efficacy of the cervical plexus block and its limitations for neck surgery.

## REFERENCES

1. Cornish PB. Applied anatomy of cervical plexus blockade. *Anaesthesiology* 1999; **90**:1790-1.
2. Materazzi G, Dionigi G, Berti P, Rago R, Frustaci G, Docimo G, *et al*. One-day thyroid surgery: retrospective analysis of safety

and patient satisfaction on a consecutive series of 1,571 cases over a three-year period. *Eur Surg Res* 2007; **39**:182-8.

3. DiNorcia J, Allendorf J. Thyroid surgery performed under local anaesthesia and same day surgery. In: Mechanick JI, editor. Emergent biotechnological to clinical practice guidelines. New Delhi: *CRC Press;* 2011.p. 249-69.
4. Mirnezami R, Sahai A, Symes A, Jeddy T. Day-case and short-stay surgery: the future for thyroidectomy? *Int J Clin Pract* 2007; **61**:1216-22.
5. Samuel K. Snyde. Local anaesthesia with monitored anaesthesia care vs. general anaesthesia in thyroidectomy: a randomized study. *Arch Surg* 2006; **141**:167-73.
6. Suh YJ, Kim YS, In JH. Comparison of analgesic efficacy between bilateral superficial and combined (superficial and deep) cervical plexus block administered before thyroid surgery. *Eur J Anaesthesiol* 2009; **26**:1043.
7. Lee JH, Yoo JH, Cho SH, Kim SH, Chae WS, Lee DG, *et al.* Thyroid surgery under monitored anaesthesia care (MAC). *Korean J Anaesthesiol* 2009; **56**:284.
8. Carling A, Simmonds M. Complications from regional anaesthesia for carotid endarterectomy. *Br J Anaesth* 2000; **84**:797-800.
9. Hopkins B, Steward D. Outpatient thyroid surgery and the advances making it possible. *Curr Opin Otolaryngol Head Neck Surg* 2009; **17**:95-9.
10. Inabnet WB, Shifrin A, Ahmed L, Sinha P. Thyroid safety of same day discharge in patients undergoing sutureless thyroidectomy. A comparison of local and general anaesthesia. *Thyroid* 2008; **18**:57-61.