

# Spindle Cell Tumour Presenting as an Abdominal Mass

Shahida Parveen Afridi, Mushaf Rasool and Shafiq-ur-Rahman

## ABSTRACT

Hyalinizing spindle cell tumour with giant rosettes (HSTGR) is a rare and recently described tumour that arises most commonly from the peripheral and deep soft tissues. It can present as a large abdominal mass. We report the case of a 60 year old man who presented with abdominal distention. CT scan showed a mass occupying the whole of the abdomen and pelvis. Exploration of abdomen revealed a jelly like mass about 20 x 20 cm in size. Mass was excised completely and confirmed as spindle cell tumour between grade I-II on histopathology.

**Key words:** Hyalinizing spindle cell tumour. Low-grade fibromyxoid sarcoma. Spindle cell tumour. Gastrointestinal stromal cell tumour (GIST). Fibrosarcoma. Abdominal mass.

## INTRODUCTION

Spindle cell tumours are low grade fibromyxoid soft tissue sarcoma (LGFMS). The name is descriptive of its microscopic appearance with features of both mesenchymal and neuroendocrine differentiation. Cytogenetic studies of spindle cell tumour show two cell lines containing balanced translocation between chromosomes 7 and 16.<sup>1</sup> A small subset of both LGFMS and hyalinizing spindle tumour (HSCT) displays areas of increased cellularity and atypia which qualify as intermediate to high grade sarcoma.<sup>2</sup> Spindle cell carcinomas are rare presentation in the esophagus as well.<sup>3</sup> These tumours rarely metastasized, but pulmonary and lymph nodes metastases are reported in the literature.<sup>4,5</sup>

To the best of our knowledge, this case has not been reported earlier from Pakistan. This case is the description of LGFMS presented as a huge enlargement of abdomen.

## CASE REPORT

A case of 60-year-old male, labourer by occupation, presented through the outpatient department with 4 months history of abdominal swelling and distention, weight loss and intermittent constipation. His vitals were within normal limits. On examination, abdomen was distended with everted umbilicus, dilated veins on right lower quadrant of abdomen with a hard non-tender mass almost occupying the whole of the abdomen reaching up to the pelvis with smooth surface. Left inguinal hernia was also present.

*Department of General Surgery, Dow University of Health Sciences/Civil Hospital, Karachi.*

**Correspondence:** Dr. Shahida Parveen Afridi, Flat No. 3, 2nd Floor, 10-C, 19th Commercial Street Phase II, DHA, Karachi.  
E-mail: drshahishakeel@yahoo.com

Received October 30, 2009; accepted May 08, 2010.

Ultrasound diagnosis was a retroperitoneal mass. CT scan showed a heterogeneous mass occupying the whole of abdomen and pelvis 23 x 18 cm in size. Posteriorly the mass was abutting the aorta, inferior vena cava, psoas muscle, ureter and inferiorly abutting the urinary bladder (Figure 1). The mass was reported most likely to be a neoplastic lesion. Mid line exploratory laparotomy showed a jelly like mass in the abdominal cavity and pelvis reaching up to the spermatic cord. This mass was approximately 20 x 20 cm in size smooth in surface and rounded in shape (Figure 2). Mass was separated from the surrounding structure and excised completely. Left side inguinal hernia repaired and orchidectomy was done through a separate left inguinal incision. Weight of the mass was 18 kg, measured after the operation. Postoperative follow-up in the ward was uneventful except draining about 500-600 ml blood stained fluid daily through the drain up to 10 days.

Histopathology confirmed the diagnosis of spindle cell tumour grade I-II. Patient presented again with recurrence after 4 months with the history of similar complain. CT scan confirmed a huge abdominal mass compressing the surrounding structures. This was reported as recurrence and patient was referred to oncology for further treatment.

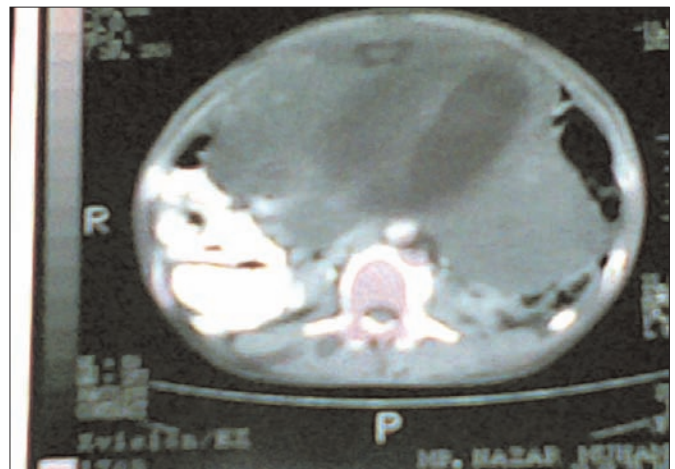
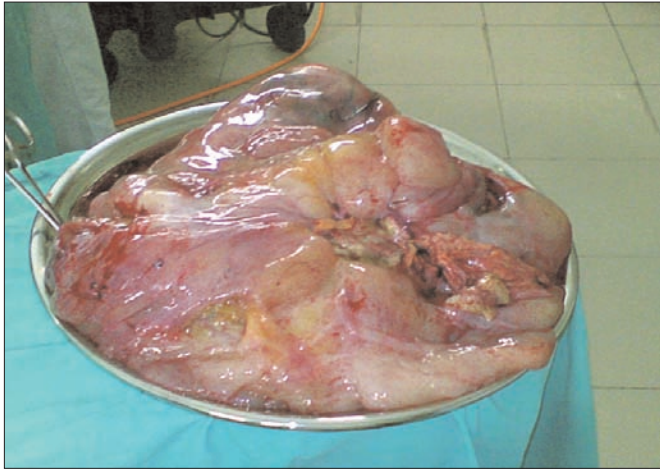

Figure 1: CT scan showing a heterogeneous mass.



**Figure 2:** Tumour after the resection.

### DISCUSSION

Spindle cell sarcoma is a rare cause of large abdominal mass.<sup>6</sup> Cytological diagnosis of spindle cell tumour is difficult and has a high potential for false positive and false negative diagnosis compared to other soft tissue tumours as seen in this case, where cytological diagnosis was inconclusive.<sup>7</sup> Spindle cell tumors are usually diagnosed on histopathology based on the presence of two architectural components first giant rosettes composed of hyalinized acellular islands surrounded by round to oval plump cells in a palisading like pattern, second spindle cells, and hyper cellular areas with plump elongated cells with highly vascular background. Occasionally ghost cells in the centre and multinucleated giant cell may present, grading is suggested in soft tissue sarcoma in order to improve the management, prognosis and to prevent the recurrence, based on nuclear atypia, nuclear overlap, mitotic figures, and necrosis these tumours are grouped into grades.<sup>8,9</sup> Treatment of spindle cell tumour is its complete excision.<sup>10</sup>

To conclude spindle cell tumours are low-grade fibromyxoid sarcoma LGFMS with giant rosettes. It may present as a huge enlargement of abdomen. Cytological diagnosis is difficult. Wide excision of the tumour is the best treatment option, but high grade tumour may present with recurrence.

### REFERENCES

1. Reid R, de Silva MV, Paterson L, Ryan E, Fisher C. Low grade fibromyxoid sarcoma and hyalinizing spindle cell tumour with giant rosettes share a common t(7;16)(q34;p11) translocation. *Am J Surg Pathol* 2003; **27**:1229-36.
2. Yang S, Liu C, Chai C, Chien S, Wang C. Hyalinizing spindle cell tumour with giant rosettes: a case report. *Kaohsiung J Med Sci* 2009; **25**:583-6.
3. Yakoob J, Abbas Z, Jaffery W, Azad SN. Esophageal polypoidal mass: presentation of an uncommon pleomorphic carcinoma. *J Pak Med Assoc* 2009; **59**:756-9.
4. O Sulvian MJ, Sirgi KE, Dehner LP. Low grade fibrosarcoma (Hyalinizing spindle cell tumour with giant rosettes) with pulmonary metastases at presentation: case report and review of the literature. *Intern J Surg Pathol* 2002; **10**:211-6.
5. Loya A, Prayaga AK, Arora A, Sundaram C, Rao SI, Uppin SG, et al. Lymph node metastasis of soft tissue tumours: a cytomorphologic study. *Acta Cytol* 2007; **51**:153-60.
6. Bills V, Iqbal R, Haqqani M, Clague JE. Spindle cell sarcoma: a rare cause of a large abdominal mass. *Age Ageing* 2005; **34**:88-9.
7. Prayaga A. Cytology of soft tissue tumours: Malignant spindle cell tumours. *J Cytol* 2008; **25**:87-8.
8. Mathur S, Kapila K, Verma K. Accuracy of cytologic grading of spindle cell sarcomas. *Diagn Cytopathol* 2003; **29**:79-83.
9. Jones C, Liu K, Hirschowitz S, Klipfel N, Layfield LJ. Concordance of histopathologic and cytologic grading in musculoskeletal sarcomas; Can grade obtained from analysis of fine needle aspirates serve as the basis for the therapeutic decisions? *Cancer* 2002; **96**:83-91.
10. Fras AP, Grazio SAF. Hyalinizing spindle cell tumour with giant rosettes of the broad ligament. *Gynecologic Oncol* 2001; **83**:405-8.

.....★.....