

# Giant Aneurysm of the Extracranial Internal Carotid Artery

Ahmad Hussain Mishwani<sup>1</sup>, Abdul Haleem<sup>1</sup> and Khalid Amjad Kiani<sup>2</sup>

## ABSTRACT

Aneurysm of the extracranial internal artery is a rare condition with incidence of 0.8-1% of all aneurysms. It can give rise to serious complications like; haemorrhage due to rupture, stroke and thromboembolism. Its treatment is technically challenging. One such case of giant aneurysm of extracranial internal carotid artery was found in a 70 years old lady. The aneurysm was treated by proximal and distal ligation of the internal carotid artery and excision of the aneurysm with excellent postoperative recovery and early follow-up.

**Key words:** Aneurysm. Internal carotid artery. Transient ischemic attack.

## INTRODUCTION

Aneurysm of the extracranial internal carotid artery is a rare disorder with very high mortality (70%) if untreated.<sup>1,2</sup> It usually presents as a pulsatile mass in neck or oropharynx. It can be partially or completely thrombosed thereby causing embolisation and ischaemic events. Compression of nerves and ruptures are other complications. The common causes are atherosclerosis, trauma and infections. Surgery is recommended for all symptomatic aneurysms.

A case of extracranial interval carotid artery aneurysm is hereby reported.

## CASE REPORT

A 70-year-old thin, frail lady was admitted in the vascular unit with history of a slowly growing, pulsatile swelling on the left side of the neck just below the mandible extending behind the angle of the jaw. The swelling was small and painless one year ago, but over the past 3 months it had become painful and rapidly increased in size. She also complained of dysphagia, hoarseness of voice, cough, aggravated by drinking; giddiness and occasional spells of brief (2-3 minutes) loss of consciousness. There was no known history of hypertension, Diabetes mellitus, trauma or local infection in the vicinity of the swelling reported.

On examination, her blood pressure was 190/110 mmHg. There was a 5x3 cm size pulsatile swelling just below and behind the mandible on the left side of neck. The upper margin of the swelling was covered by mandible. Doppler ultrasound was suggestive of aneurysm of the internal carotid artery. CT scan suggested it to be an

aneurysm of the occipital branch of external carotid artery with obliteration of the internal carotid distal to the aneurysm. Conventional angiography showed an aneurysm above the bifurcation of common carotid artery (Figure 1 a-c). In view of the above, a CT angiography was requested which confirmed the diagnosis of a saccular aneurysm of the kinked internal carotid artery.

Patient was prepared for elective surgery under general anaesthesia. Incision was made through skin and platysma. Proximal and distal control was achieved after dividing posterior belly of digastric muscle, and retro-mandibular vein. All relevant nerves were preserved. One percent lignocain was infiltrated around the carotid sinus. Balloon tip carotid shunt was kept ready. During this procedure the patient became unstable and collapsed twice. So the idea of inter-position venous grafting or reanastomosis of the carotid artery was abandoned. Proximal and distal ends of the internal carotid artery were ligated and aneurysm excised (Figure 1 d-e). Although, Endovascular stenting was a better option (procedure of choice) for this patient, it was not possible due to absence of facilities and financial reasons. Haemostasis was secured and wound closed after putting a vacuum drain under the skin flaps. Post-operative recovery was uneventful and the patient was relieved from all symptoms.

## DISCUSSION

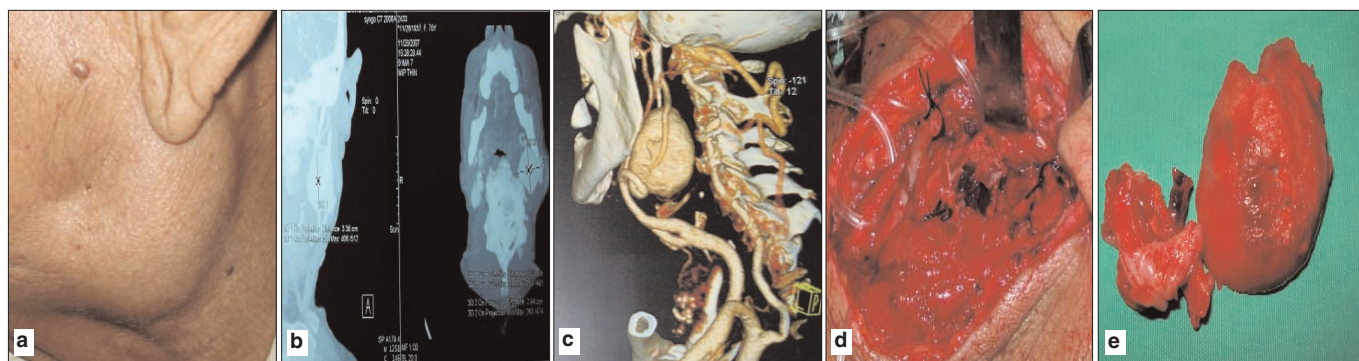
Extracranial internal carotid artery aneurysms are extremely rare. Reported incidence is about 0.8-1% of all arterial aneurysms and about 4% of all peripheral arterial aneurysms.<sup>1</sup> In most of the cases, cause is unknown. In others, the cause may be atherosclerosis, trauma (blunt or penetrating), arterial dysplasia, dissection, surgery or infection by *Mycobacterium* or other organisms.<sup>2,3</sup>

Clinical features of the extracranial internal carotid artery aneurysms depend upon its site, size, and cause. These may be asymptomatic or present as pulsatile

*Surgical Unit-II/Department of Medicine<sup>2</sup>, Combined Military Hospital/Army Medical College, Rawalpindi.*

**Correspondence:** Brig. Dr. Ahmad Hussain Mishwani, House No. 67/B, Tufail Road Lal Kurti, Rawalpindi Cantt.  
E-mail: ahmishwani@yahoo.com

Received May 17, 2008; accepted January 27, 2010.



**Figure 1:** Exteracranial aneurysm of internal carotid artery (a) Aneurysm (b) CT scan neck showing aneurysm (c) CT angiography 3D reconstruction (d) Empty bed after removal of aneurysm (e) Aneurysm.

swelling in submandibular area (30%) having a systolic bruit or rarely in tonsillar fossa or pharynx. There may be pain in the swelling, in neck, ear or headache due to dissection or compression of the facial and trigeminal nerve or their branches,<sup>2</sup> dysphasia (due to bulk or pharyngeal nerve compression), Horner syndrome or hoarseness of voice. About 40% patients may present with transient ischaemic attacks or stroke due to embolisation of fragments of thrombus from the aneurysm or compression of internal carotid artery by the aneurysm. Haemorrhage due to rupture of aneurysm is rare, but may occur especially in mycotic aneurysm and lead to death.<sup>2</sup>

Differential diagnosis of carotid aneurysm include carotid body tumour, kinked or coiled carotid artery and certain other neck swellings, e.g. carotid body tumour, cystic hygroma, branchial cyst and enlarged cervical lymph nodes.<sup>2</sup> These lesions can be diagnosed by Doppler ultrasound, digital subtraction angiography (DSA), CT scan, MRI and MR or CT angiography.<sup>2,4</sup>

The treatment of extracranial carotid aneurysm depends on its size, site, aetiology and overall condition of the patient. The mortality and morbidity rate with conservative treatment is very high. Surgical treatment prevents permanent neurological deficits with mortality rates less than 2%.<sup>1</sup> The treatment of choice is resection of the aneurysm with re-anastomosis of the internal carotid artery,<sup>2</sup> but unfortunately it is not always possible. Endovascular stenting is becoming the first option in modern centres. Ligation of proximal carotid artery is the oldest treatment, performed by Astley

Cooper in 1805, it is still performed where distal control is impossible or in emergency situations and in infection. The other surgical options include wrapping of aneurysm, endoaneurysmorrhaphy, resection and saphenous vein interposition, internal carotid re-implantation to the side of the common carotid artery, and a long patch angioplasty. Recently, endovascular, endoluminal techniques and devices, e.g. detachable silicone balloons, platinum coils and various stents are being used alone or combined with surgical procedures (for complex aneurysms) but long-term follow-up is not available.<sup>5,6</sup>

### REFERENCES

1. El-Sabroun R, Cooley DA. Extracranial carotid artery aneurysms: Texas Heart Institute experience. *J Vasc Surg* 2000; **31**:702-12. Comment in: p. 823-5.
2. Goldstone J. Aneurysms of the extracranial carotid artery. In: Rutherford RB, editor. *Vascular surgery*. 6th ed. Philadelphia: Saunders, W. B. Company; 2005.p. 2052-64.
3. Stephen E, Sridhar R, Pradhan NR, Thomas SV, Narayan RL, Agarwal S. Tuberculous aneurysm of extracranial carotid artery. *Eur J Vasc Endovasc Surg* 2008; **35**:9-10. Epub 2007 Nov 1.
4. Beena NV, Kishore MS, Mahale A, Poornima V. Pseudoaneurysm of internal carotid artery. *Indian J Pediatr* 2007; **74**:307-9.
5. Zhou W, Lin PH, Bush RL, Peden E, Guerrero MA, Terramani T, et al. Carotid artery aneurysm: evolution of management over two decades. *J Vasc Surg* 2006; **43**:493-6; discussion 497.
6. Ponce FA, Albuquerque FC, McDougall CG, Han PP, Zabramski JM, Spetzler RF. Combined endovascular and microsurgical management of giant and complex unruptured aneurysms *Neurosurg Focus* 2004; **17**:E11.

.....★.....