

Long-Term Survivor of Brain Metastases from Malignant Melanoma

Humera Mahmood, Mohammad Faheem, Asghar Hussain Asghar and Javaid Irfan

ABSTRACT

Malignant melanoma is notorious for distant metastases. Median survival for stage IV melanoma is 6-10 months and 5 year survival is less than 5%. Median survival for melanoma with brain metastases is even lower i.e. 2 to 9 months. Here a case is reported who was treated for melanoma of sole of left foot with ipsilateral inguinal adenopathy and brain metastases in 2001 and is still surviving disease-free after a lapse of 8 years.

Key words: *Malignant melanoma. Brain metastases. Radiotherapy. Whole brain radiation therapy.*

INTRODUCTION

Melanoma is the third most common cancer causing brain metastases after cancers of breast and lung. This reflects the relative propensity of melanoma to metastasize to central nervous system. Brain metastases are responsible for 20-54% of deaths in patients with melanoma and this figure rises to 95% in patients with documented brain metastases.

Although all the patients with melanoma are at risk for metastases to brain there are certain characteristics which are associated with increased risk of systemic disease including subsequent development of brain metastases. These factors include male gender, melanomas of mucosal surfaces or skin of trunk, head and neck, wide thick deeply invasive or ulcerated primary lesion, acral lentiginous or nodular lesions, involvement of 3 or more regional lymph nodes either at diagnosis or at relapse and visceral metastases at the time of diagnosis.¹ In Pakistan cutaneous malignant melanoma has been found to be more common in males (71.4%) as compared to females.² Melanoma patients with brain metastases have poor prognosis. In two series totaling almost 1400 patients, the median survival was 4 months and one year survival rates were 9% and 19% respectively.³ Radiotherapy after resection of solitary brain metastases has shown more durable response with improvement in both median survival and time to recurrence as compared to either modality used alone.

Here we present a case of malignant melanoma with solitary metastatic deposit in brain who is leading a

normal disease-free life 8 years after the brain metastases were managed with whole brain radiotherapy (WBRT) alone. Recent CT brain shows him to be disease-free. To the best of our knowledge this is the longest survival reported of any patient with brain metastases from malignant melanoma who was treated with WBRT alone in Pakistan.

CASE REPORT

A 53-year-old gentleman, known diabetic and cigarette smoker, presented in the Outpatient Department of Nuclear Medicine, Oncology and Radiotherapy Institute, Islamabad in May 2001 with complaints of pigmented lesion on sole of left foot for 5 months and swelling in left inguinal region for 3 months. There was no other complaint. His systemic examination was unremarkable. Locoregional examination revealed a spherical, black-coloured, non-tender lesion in the middle of sole of left foot about 1.5 x 1.5 cm² in size not fixed to underlying structures. Also a hard but mobile nodal mass was palpable in left inguinal region 7 x 3 cm² in size.

Trucut biopsy of the primary lesion on sole of foot and inguinal nodes showed malignant melanoma with involvement of inguinal nodes. Systemic work up including CT scan of chest and abdomen and bone scan was negative for metastases. The patient was referred for surgery. He underwent complete excision of the left foot lesion with primary skin grafting and block dissection of left inguinal nodes in May 2001. Histopathology revealed malignant melanoma of foot 5 mm thick and all the margins of resection were negative. The specimen of inguinal nodes showed that 5 out of the 10 removed nodes were involved with metastatic deposits of melanoma. Hence the disease was staged as pT4aN3M0 i.e. stage IIIc according to UICC TNM classification of malignant tumours (edition 2002). The patient was started adjuvant systemic treatment i.e. Interferon alpha in a dose of 4.5 MU subcutaneously on alternate days which he received from

Department of Oncology, Nuclear Medicine, Oncology and Radiotherapy Institute (NORI), Islamabad.

Correspondence: *Dr. Humera Mahmood, House No. 41, Street No. 82, G-8/1, Islamabad.*

E-mail: hmrmahmood692005@yahoo.com

Received September 08, 2009; accepted June 16, 2010.

12th June 2001 to 21st June 2001. Interferon had to be discontinued as the patient could not afford it further. After complete wound healing adjuvant radiotherapy was started in July 2001. Radiotherapy was given with 7.5 MeV electron beam to the primary site and 12 MeV electron beam to left inguinal region up to a total dose of 60 Gy in 30 fractions. Radiotherapy completed in August 2001. No significant late radiation toxic effects have developed until now except for fibrosis in radiation fields which has not affected patient's quality of life.

On 28th December 2001 the patient presented with left sided hemiparesis, vomiting and headache. CT scan of brain (Figure 1) showed space occupying lesion with edema in right parietal lobe. Extracranial metastases were ruled out with systemic work up. The patient refused surgical excision of brain lesion and was therefore, treated with WBRT alone; 30 Gy in 10 fractions by lateral opposed fields with 6 MV photons from December 2001 to January 2002 along with high dose steroids. The possibility of second primary was ruled out with the radiological appearance and the history of melanoma which has very high propensity of

metastasizing to brain. With cranial radiotherapy the patient became asymptomatic within 4 weeks. In February 2002, the patient was started single agent chemotherapy Dacarbazine 250 mg/m² 3 weekly for 5 days. He received 4 cycles of chemotherapy completed in May 2002. Since then the patient is on regular follow-up and until now there is no evidence of local or distant recurrence. Recent CT scan brain (Figure 2) done in June 2009 showed only gliosis in the area which was previously occupied with space occupying lesion.

DISCUSSION

Brain metastases manifest clinically in 10-40% of melanoma patients and are detected in up to 75% in autopsy series. Whole brain radiotherapy is effective in palliating symptoms of brain metastases with 60-70% of patients showing improvement by 1-2 months. However, response duration is usually short and neurologic progression is the usual cause of death.⁴ Fife *et al.* reported outcome for 646 melanoma patients treated for brain metastases at Sydney melanoma unit between 1985 to 2000. Median survival was 8.9 months for surgery and postoperative radiotherapy, 8.7 months for surgery alone, 3.4 months for radiotherapy alone and 2.1 months for supportive care.⁵ Recommended treatment for solitary brain metastasis is surgical excision followed by whole brain radiotherapy (WBRT) or WBRT followed by stereotactic radiosurgery.⁴ The case reported here although had solitary lesion in brain yet he refused surgery and received WBRT alone. Even then, there was an excellent response and recent brain CT scan shows no evidence of active disease.

Different studies have used different radiotherapy protocols for brain metastases of melanoma. A variety of dosage schedules of WBRT either alone or in combination with stereotactic radiotherapy or surgery have been used. A variety of cytotoxic drugs including Temozolamide has been tested for the treatment of brain metastases of melanoma.^{6,7} Most of the studies have shown better results of combination of WBRT with either stereotactic radiosurgery or surgical excision as compared to WBRT alone.⁸

The patient reported here underwent only WBRT and still had complete response. If the patient is not willing for surgery or is medically inoperable and stereotactic radiosurgery is not available (presently only in one centre of Pakistan) WBRT is a suitable treatment option with hopeful results. Until now the longest reported survival of any patient with brain metastases from melanoma is 16 years from Queen Elizabeth Hospital, Birmingham, UK and the patient was treated with a combination of surgical excision, stereotactic radiotherapy and chemotherapy.⁹ Three-year survival has been reported in a few patients treated with WBRT and stereotactic surgery by Kondzidka *et al.*¹⁰ The case presented here is the first one to be reported in Pakistan

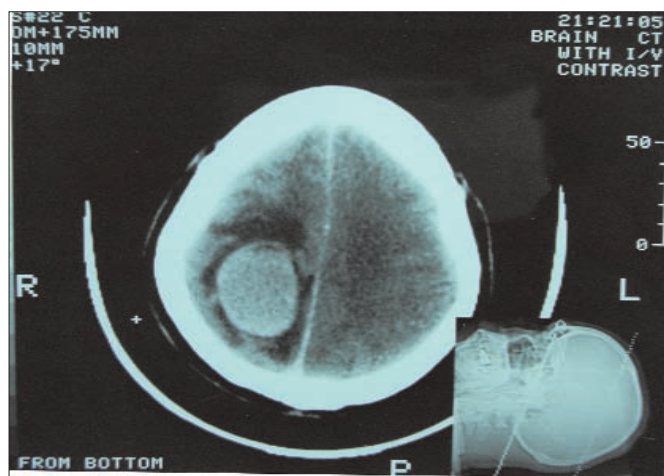


Figure 1: CT scan done on 27th December 2001 showing SOL in right parieto-temporal region of brain.

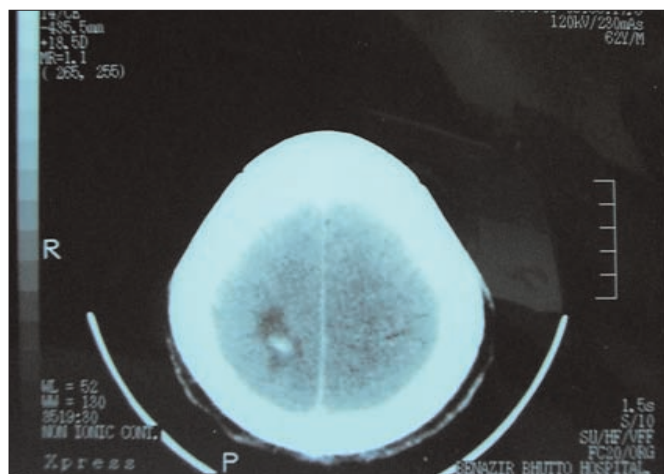


Figure 2: Showing CT scan done on 29th June 2009 showing area of reactive gliosis in the area previously occupied by SOL.

with brain metastases of melanoma treated with WBRT alone and is still surviving disease-free after a lapse of 8 years. Extensive literature search did not find any case of brain metastases of melanoma surviving so long after WBRT alone not only in Pakistan but worldwide as well. This case also suggests that patients with brain metastases of melanoma should not be left to die but should be treated and WBRT alone is a recommended therapy if other modalities of treatment are not possible or available.

REFERENCES

1. Ballo MT, Ross MI, Cormier JN, Myers JN, Lee JE, Gershenwald JE. Combined-modality therapy for patients with regional nodal metastases from melanoma. *Int J Radiat Oncol Biol Phys* 2006; **64**:106-13. Epub 2005 Sep 22.
2. Ahmad A, Alam MB, Khan W, Badar A, Shah SH. Frequency and characteristics of skin cancers diagnosed at Ayub Medical College Abbottabad, Pakistan from 1995-2003. *J Ayub Med Coll Abbottabad* 2007; **19**:3-6.
3. Ewend MG, Carey LA, Brem H. Treatment of melanoma metastases in the brain. *Semin Surg Oncol* 1996; **12**:429.
4. Solan MJ, Brady LW. Skin cancer. In: Halperin EC, Perez CA, Brady LW, editors. Principles and practice of radiation oncology. Philadelphia: Lippincott Williams & Wilkins; 2008. p. 690-701.
5. Fife KM, Colman MH, Stevens GN, Firth IC, Moon D, Shannon KF, et al. Determinants of outcome in melanoma patients with cerebral metastases. *J Clin Oncol* 2004; **22**:1293-300.
6. Chiarion SV, Murr R, Pigozzzo J, Sarti S, Tomassi O, Romanini A. Brain metastases from malignant melanoma. *Forum (Genova)* 2003; **13**:170-82.
7. Meier S, Baumert BG, Maier T, Wellis G, Burg G, Seifert B, et al. Survival and prognostic factors in patients with brain metastases from malignant melanoma. *Onkologie* 2004; **27**:145-9.
8. Yasuko S, Hideki S, Atsuko A. A case of malignant melanoma with brain metastases successfully treated by whole brain radiation and gamma knife. *Skin Cancer* 2006; **20**:273-7.
9. Hamid NA, Chandra A, Meyer CH. Multiple brain metastases from malignant melanoma with long-term survival. *Br J Neurosurg* 2004; **18**:552-5.
10. Kondziolka D, Lunsford LD, Flickinger JC. Controversies in the management of multiple brain metastases: the roles of radiosurgery and radiation therapy. *Forum (Genova)* 2001; **11**:47-58.

