

Primary Adrenal Lipoma

Safdar Shah and Suhaib Umer Bhatti

ABSTRACT

A case report of primary adrenal lipoma is being presented. A 35-year-old male, initially presented with pain in right loin and was admitted to Urology Unit of Prince Abdullah Bin Abdul Aziz Hospital, Bisha, KSA, for frank hematuria. The tumour was suspected on IVU and ultrasound abdomen and confirmed on CT-scan of abdomen. Right adrenalectomy was successfully performed and histopathology confirmed the diagnosis of adrenal lipoma.

Key words: Adrenal lipoma. Adrenalectomy. Ultrasound abdomen.

INTRODUCTION

Adrenal lipoma is a very rare benign tumour. Uptill now very few cases have been reported in literature.¹ Adrenal lipoma or lipomatous tumours are more common in men than women.² The most common adrenal lipomatous tumours are myelolipoma, adrenal lipoma, adrenal teratoma, adrenal angioliipoma and adrenal liposarcoma.² Giant adrenal lipoma upto the size of 8x4.5 cm has been recorded.¹ Adrenal lipoma is found incidentally either during autopsy or in patients undergoing imaging studies for some other disease.³

Most of the adrenal lipomatous tumours are asymptomatic and non-functioning, but can produce symptoms due to compression on surrounding structures. Usually found in adrenal gland but can occur elsewhere.⁴ They are usually found on one side but bilateral myelolipoma have also been described.⁴ Being a benign condition, they are usually asymptomatic.

CASE REPORT

A 35-year-old male was admitted in Urology Unit of Surgical Department of Prince Abdullah Bin Abdul Aziz Hospital, Bisha, KSA, in 1998 with the complaint of intermittent frank hematuria, right loin pain radiating to flank area for the last one month. He also noticed burning micturation, off and on attack of right ureteric colic and nausea. There was no history of weight loss, fever, generalized weakness, uncontrolled hypertension, gynecomastia or myalgia. On physical examination, his vital signs were normal, abdominal examination revealed tenderness in right flank and loin

area. Both kidneys were not palpable. Bowel sounds and digital rectal examination were normal.

On investigation CBC, renal profiles, LFT and bleeding profiles were within normal limits. Abdominal ultrasound revealed a rounded hyper-echoic mass encroaching on the upper part of the right kidney. IVU showed soft tissue shadow and flattening and compression effects on upper calyces in the right kidney. CT abdomen reported a large soft lobulated mass in the right adrenal gland encroaching on the upper part of the right kidney (Figure 1 and 2). After pre-operative preparation, exploration of the mass was done through 12th rib cutting incision.

Peroperatively adrenal mass measuring 5x4x3 cm was found occupying the whole of right adrenal gland and completely separable from the upper pole of right kidney. Right total adrenalectomy was done.

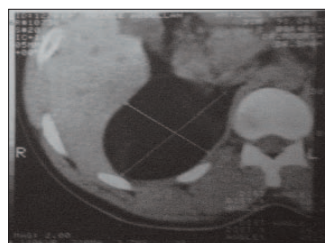


Figure 1: CT-scan showing the amplified picture of a adrenal lipoma.

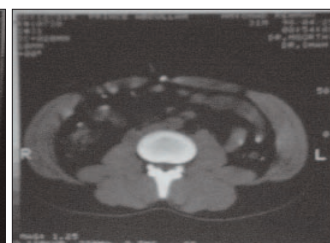


Figure 2: CT-scan of abdomen showing soft tissue mass overlying the right kidney.




Figure 3: Showing the histopathology slide (H&E x160) of adrenal lipoma with adrenal tissue, lot of fatty tissue and a few blood vessels within the fat cells.

¹ Department of Urology, Sheikh Zayed Medical College, Rahim Yar Khan.

² Department of Urology, Mayo Hospital, Lahore.

Correspondence: Dr. Safdar Shah, 13-B Sadiq Club Road, Opp. Canal Girls High School, Rahim Yar Khan.
E-mail: abeer15@msn.com

Received October 8, 2008; accepted February 20, 2009.

On gross examination, the tumour was yellowish grey in colour with greasy surface and having a slippery firm consistency. Mass weighed 200 gms. Diagnosis was confirmed histologically (Figure 3) showing capsule of a mass with mature and immature fat cells. Some homogenous material was also seen thought to be muscle fibers with few capillaries in it. The remnants of adrenal cortical tissue were also seen.

DISCUSSION

Adrenal lipoma is a rare benign tumour described first in literature in 1988. Uptill now, only 10 cases have been reported worldwide.² Lam and Locy in 2001 have described it as the second most common lipomatous adrenal tumour after myelolipoma in 30 years of clinicopathological experience at one centre.²

Most of the adrenal lipomas are asymptomatic and non-functioning but pain and hypertension are some of the presenting complaints due to compression effects on kidney. Hematuria is very uncommon presenting complaints in giant adrenal lipoma. When it compresses the upper pole calyceal system of the kidney⁵, the usual site of occurrence of lipoma is the adrenal gland but retroperitoneal fat, which is adherent to the adrenal gland, is also a common site for lipomatous changes.⁶

The best therapy for adrenal lipoma is complete excision of lipoma, if possible, otherwise adrenalectomy is the favourite therapeutic option.

Acknowledgement: I am thankful to Dr. Wafa, a histopathologist, who helped me in providing the slides of this specimen.

REFERENCES

1. Lam KY, Chan AC, Ng IO. Giant adrenal lipoma: a report of two cases and review of literature. *Scand J Urol Nephrol* 1997; **31**:89-90.
2. Lam KY, LoCy. Adrenal lipomatous tumours: 30-year clinicopathological experience at single institution. *J Clin Pathol* 2001; **54**:707-12.
3. Sharma MC, Gill SS, Kashyap S, Nabi G, Misha MC. Adrenal lipoma: a case report. *Urol Int* 1998; **6**:245-7.
4. Wrightson WR, Hahm TX, Hutchinson JR, Cheadle W. Bilateral giant adrenal myelolipoma: a case report. *Am Surg* 2002; **68**:588-9.
5. Albala DM, Chung CJ, Sueoka BL, Memoli A, Heaney JA. Hemorrhagic myelolipoma of adrenal gland after blunt trauma. *Urology* 1991; **38**:559-62.
6. Romacciato G, Lambard M, Amodio PM, Mercantini P, Petrocca S, Stipa F, Digiacomo G. Angiolipoma arising from retroperitoneal tissue. *Am Surg* 2003; **69**:427-33.

.....★.....